

# Letters to the Editor/Cartas ao Editor

DOI: 10.5935/1678-9741.20140020

RBCCV 44205-1530

## Comments on “Innovation and Excellence: Changing to prevail the Brazilian Cardiovascular Surgery”

Dear editor,

I have read the “Innovation and Excellence: Changing to prevail the Brazilian Cardiovascular Surgery” editorial written by Professor Walter J. Gomes [1], and found it to be at the same time lucid and honest, as the story is told by its protagonist.

I want to congratulate the author on his tenure at the Brazilian Society of Cardiovascular Surgery (SBCCV), on his actions, and on his dedication to the causes involving cardiovascular surgeries, which are known to all, but are worth mentioning.

I reflect on an important topic discussed in the editorial: ever since I had the honor of being President of the Brazilian Association of Cardiovascular Surgery Residents (ABRECCV) in 2010, I have raised what I consider a critical issue in the cardiovascular surgery chain: doctors entering this specialty. That year, at one of the meetings of the Society of Cardiovascular Surgery of the State of São Paulo (SCICVESP), I had the opportunity to present an article entitled “Shortage of cardiothoracic surgeons is likely by 2020” [2], which had been recently published in the *Circulation* and subsequently well-reviewed on the *Heartwire Medscape Cardiology* website [3]. The article predicted a lack of cardiovascular surgeons in the USA in 2020. However, we can say that this is already a reality in Brazil.

One of the great difficulties on the path to creating new services in cardiovascular surgery is finding other surgeons with the profile and willingness to implement those services. It seems clear that this happens because there are few of us. Therefore, it is essential that the next management team stand firm on the demands to waive the general surgery prerequisite and to improve the quality of training in residencies, which I believe would make our specialty viable in the future.

After talking with both young and older surgeons, it seems that we could consider creating a department within SBCCV that would provide guidance to surgeons (human beings raised behind closed doors, with little incentive to interact with the world around them) on how to develop and implement a viable project for service in cardiovascular surgery. The project would cover the basic needs required of the public manager, whether philanthropic or private, who wishes to invest in this idea, including: structure; human resources; protocols; trade negotiations with hospitals, health insurances, and co-operatives; guidance on legislation (decrees, laws, SUS); and assistance in adapting models to local needs.

Such department could go a long way in helping even to restructure existing services that have had their quality, spirits, and motivation diminish over time.

Congratulations to the Editor and the author on the services rendered to our cause. I wish them good health and Peace in 2014.

**Sergio Francisco dos Santos Junior<sup>1</sup>**

*1. Cardiovascular Surgeon, SBCCV-AMB Specialist / Santa Casa de Itabuna, Itabuna, BA, Brazil.*

## REFERENCES

1. Gomes WJ. Inovação e excelência: transformando para prevalecer a cirurgia cardiovascular brasileira. *Rev Bras Cir Cardiovasc.* 2013;28(4):III-IV.
2. Grover A, Gorman K, Dall TM, Jonas R, Lytle B, Shemin R, et al. Shortage of cardiothoracic surgeons is likely by 2020. *Circulation.* 2009;120(6):488-94.
3. Busko M. Cardiothoracic surgeon shortage likely by 2020, study predicts. *Heartwire*; 2009. Disponível em: <http://www.medscape.com/viewarticle/706571>.

## About Technique for Planning Interventional Treatments

The article “Proposal for geometric virtual correction of the ostial projection of renal artery in the surgery study of infrarenal aneurysms: initial results of a pilot study” presents a simple technique of great importance in planning interventional treatment technique.

The skill with the manipulation of digital medical image formats allows the recovery of a greater volume of data and allows the interventional procedures are performed more efficiently, with less time for adjusting the projection of images, injections of contrast and ionizing radiation exposure. In addition to the renal artery ostial projection, the technique can be applied in treatment of thoracic aorta and transcatheter aortic valve implants.

It is important to note that the study was performed using a free software and personal computers, indicating that

the knowledge of this technique is independent of major investments, which makes encouraging and demystifies the use of softwares for viewing medical images. Obviously, expertise and familiarity come with the practice of using, but it is evident that this is an important tool given the current scenario where more and more procedures are guided by images.

**Guilherme Agreli<sup>1</sup>**

1. Bachelor's Degree in Medical Physics, São José do Rio Preto, SP, Brazil.

#### REFERENCE

1. Molinari GJP, Dalbem AMO, Menezes FH, Guillaumon AT. Proposal of renal artery's ostial projection under virtual geometric correction in infrarenal aneurysms: initial results of a pilot study. Rev Bras Cir Cardiovasc. 2014;29(1):78-82.

#### Repair of an interrupted aortic arch in concomitant diseases

To the Editor,

We read with great interest the article by Dallan et al. [1], entitled "Cardiogenic shock due to coronary artery disease associated with interrupted aortic arch", which is recently published in Brazilian Journal of Cardiovascular Surgery/Revista Brasileira de Cirurgia Cardiovascular. The authors presented a case of a cardiogenic shock due to serious right and left main coronary artery disease associated with interrupted aortic arch (IAA). They just performed an off-pump left anterior descending artery bypass, and they managed the treatment of IAA conservatively. We thank authors for their excellent management of coronary artery disease and valuable article but some comments may be of beneficial.

IAA is a rare congenital malformation and could be seen very rarely in late adulthood [2,3]. Complex diseases associated with IAA should be managed in either of single stage or two-stage procedures [2-4]. Although Burton et al. [2] and Lafci et al. [3] reported a successful single-stage treatment of IAA and aortic root replacement, and Yu et al. [5] and Riess et al. [6] reported a successful single stage treatment of IAA and coronary artery bypass grafting; as in this case, single stage surgeries could be challenging and are associated with high morbidity and mortality [2-4].

IAA is usually accompanied by hypertension, and confers

a very poor prognosis without treatment [2,3]. Considering that if not treated, patient's prognosis are usually lethal; either single or two stage surgeries should be managed depending on the surgeon's experience and patient's condition [2-4]. In contrast to conservative management, early treatment of IAA prevents possible aortic rupture and associated cardiac dysfunction in such a critical patient.

**Emre Yalcinkaya<sup>1</sup>, MD; Murat Celik<sup>2</sup>, MD**

1. Aksaz Military Hospital, Chief of coronary care unit, Marmaris, Mugla, Turkey.  
2. Gulhane Military Medical Faculty, Istanbul, Turkey.

#### REFERENCES

1. Dallan LAO, Milanez A, Lisboa LAF, Jatene FB. Cardiogenic shock due to coronary artery disease associated with interrupted aortic arch. Rev Bras Cir Cardiovasc. 2013;28(2):290-1.
2. Burton BJ, Kallis P, Bishop C, Swanton H, Pattison CW. Aortic root replacement and extraanatomic bypass for interrupted aortic arch in an adult. Ann Thorac Surg. 1995;60(5):1400-2.
3. Lafci G, Yalcinkaya A, Ecevit AN, Tasoglu I, Kadirogullari E, Turkvatan A, et al. Single-stage aortic valve-sparing root replacement and extra-anatomic bypass for aortic arch interruption in an adult. Tex Heart Inst J. 2012;39(3):398-400.
4. Issa M, Avezum A, Dantas DC, Almeida AF, Souza LC, Sousa AG. Risk factors for pre, intra, and postoperative hospital mortality in patients undergoing aortic surgery. Rev Bras Cir Cardiovasc. 2013;28(1):10-21.
5. Yu L, Shi E, Gu T. Single-stage repair of interrupted aortic arch with simultaneous coronary artery bypass grafting without cardiopulmonary bypass in an adult. Ann Thorac Surg. 2011;92(3):1110-3.
6. Riess FC, Danne M, Stripling JH, Bergmann H, Bleese N. Surgical treatment of interrupted aortic arch with extraanatomical bypass simultaneous to coronary artery bypass grafting and aortic valve replacement. Heart Surg Forum. 2004;7(5):E394-7.

#### Answer

We thank Yalcinkaya et al. [1] for their interest in our article: cardiogenic shock due to coronary artery disease associated with interrupted aortic arch [2] and for the interesting points they raised. Yalcinkaya et al. in agreement that either single or two stage surgeries should be managed for repair interrupted aortic arch (IAA), considering that if not treated it may confer a very poor prognosis. We have experience in surgical repair of

the aortic arch coarctation in adults using the extra-anatomic aortic bypass technique using Dacron graft [3]. However, in this case we chose the simplest surgical approach (saphenous graft to left anterior descending) because we believed that such an unstable and critical patient's condition would not let allow a simultaneous correction (tube between ascending and descending aorta as well as coronary artery bypass graft).

We know that IAA rarely develops to old age since it is early diagnosed. However, the beneficial effect of surgical repair or transcatheter intervention in terms of diminished mortality in very old patients is still questionable, which makes conservative management with antihypertensive drug therapy an acceptable treatment options in such patients [4]. We agree with Yalcinkaya et al., that clinical stable adult patients with complex diseases associated with IAA should be managed in either single stage or two-stage procedures.

***Luís Alberto Oliveira Dallan, Adriano Milanez, Luiz Augusto F. Lisboa, Fabio B. Jatene. São Paulo, SP.***

#### REFERENCES

1. Yalcinkaya E, Celik M. Repair of an interrupted aortic arch in concomitant diseases. Rev Bras Cir Cardiovasc. 2013;29(1):111.
2. Dallan LA, Milanez A, Lisboa LA, Jatene FB. Cardiogenic shock due to coronary artery disease associated with interrupted aortic arch. Rev Bras Cir Cardiovasc. 2013;28(2):290-1.
3. Lisboa LAF, Abreu Filho CAC, Dallan LAO, Rochitte CE, Souza JM, Oliveira SA. Tratamento cirúrgico da coarctação do arco aórtico em adulto: avaliação clínica e angiográfica tardia da técnica extra-anatômica. Rev Bras Cir Cardiovasc. 2001;16(3):187-94.
4. Cevik S, Izgi C, Cevik C. Asymptomatic severe aortic coarctation in an 80-year-old man. Tex Heart Inst J. 2004;31(4):429-31.

#### **Early coronary artery disease as a complication of radiotherapy for Hodgkin's disease**

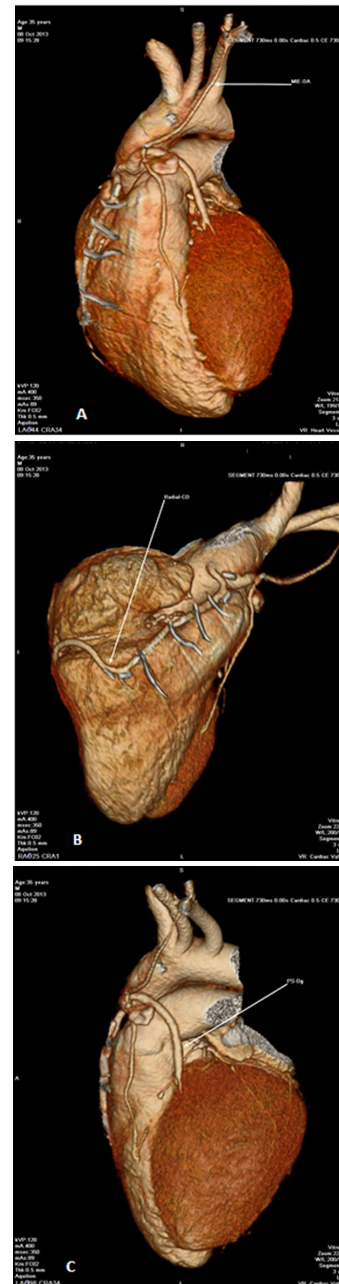
Dear Editor,

We would like to share our experience with a 28-year-old patient, who had been complaining of chest pain and dyspnea after minimal efforts for 10 days. He denied having hypertension and diabetes and smoking. He had undergone supra-diaphragmatic radiotherapy associated with chemotherapy for Hodgkin's disease 15 years ago.

His physical examination was normal. The electrocardio-

gram showed normal sinus rhythm, inverted T waves in the anterior and inferior wall, and only mild mitral regurgitation in two-dimensional echocardiography.

Myocardial perfusion imaging demonstrated an area of severe reversible uptake at great length in the septal and inferior regions of the left ventricle (LV), reduced global left ventricular systolic function, decreased ejection fraction during stress, and transient left ventricular dilation post-stress.



**Fig. 1 - Coronary CT angiography.**  
*A - patency of the left internal mammary artery - anterior descending artery graft. B - patency of radial artery - right coronary artery graft. C - patency of saphenous bypass - diagonal artery graft*

In the coronary angiography, we observed normal systolic function with mild dyskinesia in apical wall; occlusion of the right coronary artery (RCA) in the distal third, and severe lesions in the middle third of the anterior descending artery (DA) and in the origin of the circumflex artery.

He underwent coronary artery bypass surgery on the fifth day with anastomosis of the left internal thoracic artery to the descending artery and right internal thoracic artery to the diagonal artery as well as saphenous bypass of diagonal aorta and radial aorta for right coronary. He was discharged on the sixth postoperative day.

CT angiography of the coronary arteries in the sixth year of follow-up showed patent grafts (Figure 1) and the patient progressed asymptomatic.

We aimed to draw attention to the fact that even though coronary disease in young patients is rare, it is frequent in young patients who underwent mediastinal irradiation as treatment for Hodgkin's disease. In addition, the most common cause of late mortality is acute myocardial infarction [1,2], with 8% risk for fatal and nonfatal infarction, up to 22 years after treatment [3].

Therefore, these patients should undergo regular cardiac evaluation for early diagnosis.

Mediastinal irradiation can lead to endothelial injury, fibroblast proliferation, collagen deposition, changes to the intima of the vessels, and acceleration of coronary disease [4]. When irradiation occurs in the anterior mediastinum, it is more damaging to the trunk of the left coronary artery [5], the anterior descending, and the right coronary artery ostium, while the posterior irradiation affects mostly the circumflex artery [6].

The risk appears higher when associated with chemotherapy, especially with vinblastine [3], due to the possibility of occlusion of the right coronary artery, as well as radiotherapy with doses greater than 30 GY [4].

Concerning surgery, internal thoracic artery grafts do not seem to be influenced by prior radiotherapy, but by cardiovascular risk factors, with a survival rate of 87% in five years.

**Tereza Cristina Barbosa Lins<sup>1</sup>; Lúcia Maria Vieira de Oliveira Salerno<sup>1</sup>; Pedro Rafael Salerno<sup>1</sup>; Emanuel Sávio Cavalcanti Sarinho<sup>2</sup>**

1. HOPE-Esperança Hospital, Recife, PE, Brazil.

2. Federal University of Pernambuco, Recife, PE, Brazil.

#### REFERENCES

1. Filopei J, Frishman W. Radiation-induced heart disease. *Cardiol Rev.* 2012;20(4):184-8.
2. Salemi VM, Dabarian AL, Nastari L, Gama M, Soares Júnior J, Mady C. Treatment of left main coronary artery lesion after late thoracic radiotherapy. *Arq Bras Cardiol.* 2011;97(3):e53-5.
3. Lee MS, Finch W, Mahmud E. Cardiovascular complications of radiotherapy. *Am J Cardiol.* 2013;112(10):1688-96.
4. Brennan S, Hann LE, Yahalom J, Oeffinger KC, Rademaker J. Imaging of late complications from mantle field radiation in lymphoma patients. *Radiol Clin North Am.* 2008;46(2):419-30.
5. Victor EG, Parente GBO. Radioterapia mediastínica e lesão ostial de tronco de coronária esquerda. *Arq Bras Cardiol.* 2004;82(3):295-7.
6. Mulrooney DA, Ness KK, Solovey A, Hebbel RP, Neaton JD, Peterson BA, et al. Pilot study of vascular health in survivors of Hodgkin lymphoma. *Pediatr Blood Cancer.* 2012;59(2):285-9.