

# Standardization of video-assisted cardiac surgery technique: initial experience

## *Padronização da técnica para cirurgia cardíaca videoassistida: experiência inicial*

Jeronimo Antonio FORTUNATO JÚNIOR<sup>1</sup>, Alcides A. BRANCO FILHO<sup>2</sup>, Aníbal BRANCO<sup>3</sup>, André Luiz M. MARTINS<sup>4</sup>, Marcelo L. PEREIRA<sup>4</sup>, João Gustavo G. FERRAZ<sup>5</sup>, Luciana PALUDO<sup>6</sup>

RBCCV 44205-972

### *Abstract*

**Introduction:** Minimally invasive cardiac surgery has been performed in major worldwide centers, including procedure such as valves, coronary and congenital surgery.

**Objective:** To demonstrate our first works with noninvasive cardiac surgery by mean of the experience gained with general and thoracic surgery.

**Methods:** Whenever possible to carry out a minimally invasive cardiac surgery, this was the approach of choice. The left thoracoscopy was used in four cases: (1) symptomatic coronary-pulmonary fistula ligation; (2) implant of an epicardial lead into the left ventricle for resynchronization;

(3) excision of pericardial giant lipoma in the left atrium, and (4) resection of hemangiolioma in the mediastinum. Right thoracoscopy with extracorporeal circulation through cardiopulmonary bypass via femoral vein and artery and cardiac arrest in ventricular fibrillation with moderate hypothermia were carried out in the following cases: (5) patient with mitral stenosis after surgical repair with Carpentier ring 12 years before. An anterior and posterior commissurotomy without thoracotomy was successfully made; (6) patient with idiopathic dilated cardiomyopathy, high-response atrial fibrillation, and severe mitral insufficiency, underwent mitral repair surgery with

1. Master degree in Clinical Surgery (Head Surgeon; Department of Cardiac Surgery – Red Cross Hospital - Curitiba, PR)
2. General Surgeon (Surgery Department Head)
3. Urologist (Member of the Department of Urologic Videosurgery)
4. Cardiac Surgeon (Member of the Department of Cardiac Surgery)
5. Cardiac Surgeon (Member of the Department of Cardiac Surgery)
6. Internal Medicine (Specialized in Cardiology)
7. Anesthesiologist (Anesthetist of the Cardiac Surgery staff)

This study was carried out at the Brazilian Red Cross Hospital Cardiac Surgery Department, a branch of UNICENP/Paraná - Rua Vicente Machado 1310, Bairro Batel, Curitiba-PR.

### Correspondence address:

Jerônimo A. Fortunato Júnior Rua Amauri Gabriel Grassi Matei 50, Santo Inácio, Curitiba, PR, Brasil, CEP 82.010.620. Fone/Fax: (41) 3372-6822.

E-mail: jfjunior@uol.com.br

Article received on October 24<sup>th</sup>, 2007

Article accepted on April 25<sup>th</sup>, 2008

Gregori's ring and ablation of the pulmonary veins with radio-frequency catheter. (MAZZE modified)

**Results:** No death occurred in this series and the surgical result in all cases was highly satisfactory. All patients were discharged from hospital with a mean time of  $5.5 \pm 5$  days after intervention.

**Conclusion:** Our initial experience in this field proves the effectiveness and the viability in introducing this type of technique in Brazil.

**Descriptors:** Surgical procedures, minimally invasive. Cardiac surgical procedures. Video-assisted surgery.

#### Resumo

**Introdução:** Cirurgias cardíacas videoassistidas minimamente invasivas têm sido realizadas em grandes centros mundiais, incluindo procedimentos valvares, coronários e congênitos.

**Objetivo:** Apresentar nossa primeira casuística com videocirurgia cardíaca, por meio da experiência adquirida com cirurgia geral e torácica.

**Métodos:** Sempre que houve possibilidade de se realizar uma cirurgia cardíaca por acesso minimamente invasivo, esta foi a abordagem inicialmente utilizada. A toracoscopia esquerda foi utilizada em quatro casos: (1) ligadura de fistula coronário-

pulmonar sintomática, (2) implante de eletrodo epicárdico em ventrículo esquerdo para ressincronização ventricular, (3) retirada de lipoma gigante de pericárdio com pedículo em átrio esquerdo e (4) ressecção de hemangio-lipoma de mediastino. Toracoscopia direita com bypass cardiopulmonar via artéria e veia femorais e parada cardíaca em fibrilação ventricular com hipotermia moderada, foram realizados nos seguintes casos: (5) paciente com estenose mitral pós-plastia, com anel de Carpentier 12 anos antes. Foi realizada comissurotomia anterior e posterior com sucesso, sem toracotomia, (6) paciente com miocardiopatia dilatada idiopática, fibrilação atrial de alta resposta e insuficiência mitral importante, realizada plastia mitral com anel de Gregori e ablação de veias pulmonares com cateter de radiofrequência (MAZE modificada). Neste caso, uma minitoracotomia ântero-lateral direita de 6 cm foi utilizada.

**Resultados:** Nenhum óbito ocorreu nesta série e o resultado cirúrgico em todos os casos foi altamente satisfatório, sendo que todos os pacientes receberam alta hospitalar com média de  $5,5 + 5$  dias após a intervenção.

**Conclusão:** Nossa experiência inicial neste campo demonstra a eficácia e exequibilidade de introdução deste tipo de técnica em nosso meio.

**Descritores:** Procedimentos cirúrgicos minimamente invasivos. Procedimentos cirúrgicos cardíacos. Cirurgia video-assistida.

## INTRODUCTION

Over the past few years, the surgical approach to heart diseases using minimally invasive techniques has had a great improvement, but difficulties in visualizing and exposing cardiac structures have limited its influence. With the advent of videosurgery in general surgery and its application in the cardiac surgery, the minimally invasive procedures have become more and more usual. The robotics with articulated and motor-based instruments further improves this new technique.

Our studies related to cardiac videosurgery started in 2006 using our experience acquired through the practice of general and thoracic surgeries. Whenever there has been a possibility of performing a cardiac surgery by minimally invasive approach, this was the approach of choice. The conversion into open surgery was suggested as a last resource.

## METHODS

The instruments used involved a 5- or 10-mm diameter thoracoscope according to the necessity of visual field and lens angulation of  $30^\circ$ . The instruments (ESTECH inc.; California, USA) were specifically designed for cardiac surgery, e.g., atrium retractor, scissors/shears, knot pushers, needle-holder, and counter needle-holder. Other instruments such as forceps, clamps, electrocautery, and staplers came from laparoscopic surgery. Video and light source are the same used for conventional laparoscopy (Figure 1). When opening cardiac cavity a carbon dioxide ( $\text{CO}_2$ ) insufflator and a manometer under negative pressure were used. Femoral artery and vein cannulation kits were designed for peripheral cardiopulmonary bypass (DLP®, Medtronic Inc., Minneapolis, USA).

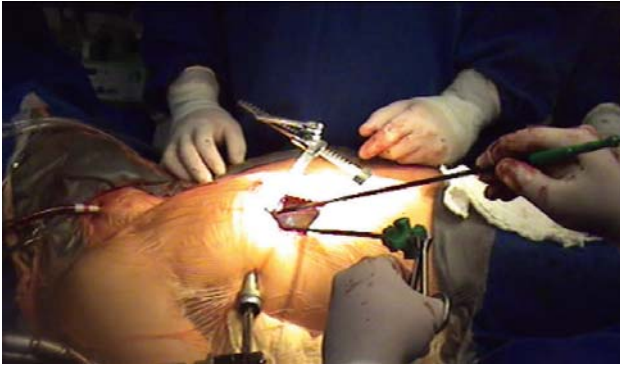


Fig. 1 – Minithoracotomy panoramic view for mitral valve access, with videoscopic instruments

The cases presented were divided into two groups according to the approach used and cardiotomy requirement:

### Group I

Left lateral thoracoscopy, without cardiotomy, through three 10-mm access routes for instrumentation were used in the following cases:

(1) Ligature of symptomatic coronary-pulmonary fistula without thoracotomy.

- A 45-year-old female patient with a diagnose of coronary-pulmonary fistula diagnosed after months of dyspnea and thoracic pain (Figure 2).

(2) Epicardial lead implantation into the left ventricle for ventricular resynchronization, without thoracotomy.

- A 53-year-old female patient with dilated cardiomyopathy, NYHA functional class III, with complete left AV block (Figure 3).

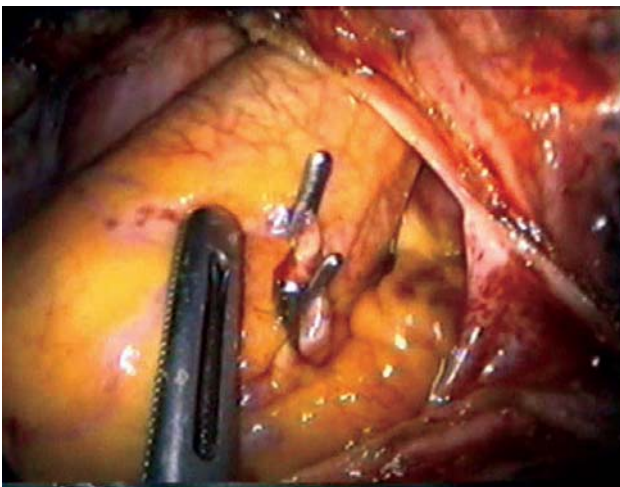


Fig. 2 – Videoendoscopic aspect of the coronary-pulmonary fistula ligature

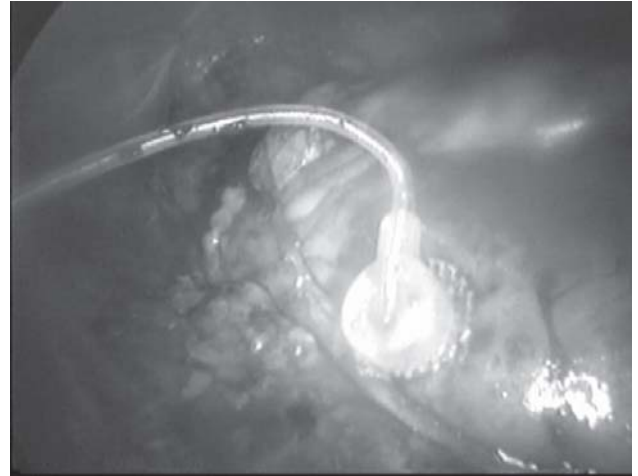

Fig. 3 – Videoendoscopic vision of the lead implanted into the left ventricle

(3) \*Resection of a giant lipoma from the pericardium with left atrium pedicle.

- A 32-year-old male patient presenting thoracic pain and frequent extrasystole with a diagnosis of adherent intrapericardial giant lipoma to the left atrium; resection through tomography and echocardiography. Anatomicopathologic diagnosis evidenced a benign lipoma weighing 900 g.

(4) \*Resection of hemangiolioma from the mediastinum.

- A 55-year-old male patient with radiologic and tomographic findings of mediastinal enlargement and tumoral mass, respectively; on anatomicopathologic diagnosis, these findings were diagnosed as hemangiolioma.

\* Note: In both cases of lipoma a minithoracotomy was used for instrumentation and resection of larger tumors.

### Group II

#### Right lateral thoracoscopy with cardiotomy

Cardiotomy was involved in the cases of group II, thus the patients underwent cardiopulmonary bypass (CPB) via femoral vein and artery cannulation. Low-profile cannulation kits (DLP®, Medtronic Inc.) especially designed for peripheral CPB were used in both cases. The insertion of venous cannula up to the right atrium was performed through direct vision or videoendoscopy; transesophageal echocardiography was not necessary. Cardiac arrest was performed under hypothermic ventricular fibrillation; transthoracic clamping or endoclamping was not necessary.

(5) Mitral stenosis commissurotomy after surgical repair using Carpentier ring 12 years ago. Femoral cardiopulmonary bypass were performed with venous

drainage using a long femoral cannula (24 Fr) alone conducted up to the right atrium under endoscopy and through an arterial cannula (17 Fr) via right femoral artery. An anterior and posterior commissurotomy was performed through a left atriotomy without pericardial dissection below the phrenic nerve and after left atrium exposure under videoendoscopy. The procedure was performed in a totally endoscopic fashion without greater incisions than those already used for trocars and instruments; 3 access routes were used for introduction of instruments.

- A 24-year-old female patient presenting a clinical picture of heart failure, NYHA functional class III, with a history of rheumatic mitral stenosis and surgical repair with

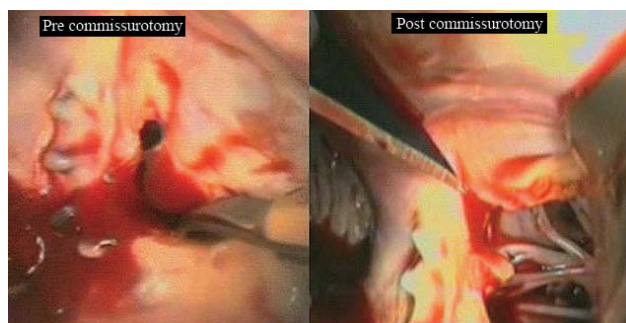


Fig. 4 – Mitral valve stenotic aspect pre and post commissurotomy

Carpentier ring at the age of 12; the echocardiographic diagnosis was as follows: severe mitral restenosis after surgical repair (Figure 4).

(6) Mitral valve replacement and modified Mazze surgery were performed through a 6-mm right anterolateral minithoracotomy and a 10-mm thoracoscopic port-access. Femoral CPB with venous drainage using a long femoral cannula (24 Fr) alone conducted up to the right atrium by direct vision, and arterial cannula (17 Fr) into right femoral artery. After drainage of cavities and hypothermic ventricular fibrillation ( $\pm 26^\circ$ ) was achieved, a left atriotomy was performed under videoscopia to expose the left atrium. Mitral valve replacement with Gregori ring, left leaflet ligature, and pulmonary veins ablation using a radiofrequency catheter were all performed.

- A 59-year-old female patient with dilated cardiomyopathy, NYHA functional class III, presenting high-response atrial fibrillation and severe mitral regurgitation.

## RESULTS

No deaths were observed in this series. The endotracheal tube was withdrawal in all cases at the

operating room but case 6. A minithoracotomy was useful in cases 3, 4, and 6. Case 5 was performed in a complete endoscopically fashion, i.e., without thoracotomy; vision of thoracic cavity was accomplished through a completely peripheral vision – under videoscopia. Cardiac arrest was achieved through hypothermic ventricular fibrillation not associated to complications, thus avoiding transthoracic cross clamping or endoaortic clamping. Kits of arterial and venous cannulation to peripherally access CPB were used. Cardiopulmonary bypass support was successfully established through femoral artery and vein dissection and insertion of the cannulae using the Seldinger technique.

Patients were highly satisfied with the surgical outcomes. All patients were discharged home, with an average length of stay of  $5.4 \pm 6$  days after intervention. All patients are followed-up at the outpatient clinic service. Minimally invasive surgical procedure was the intervention of choice for all patients who have signed written informed consent. The pain expressed by the amount of drugs used was reduced. When compared to median sternotomy, a cosmetically attractive result was reported by all patients.

## DISCUSSION

In the 90s, minimally invasive cardiac surgery (MICS) carried promises of outstanding results in relation to postoperative pain, esthetical effect of small incisions, and reduced surgical bleeding. However, due to inconsistent results, many reports have been discussing the minimally invasive procedures when compared with those of the conventional procedures in relation to complications and survival. Several studies have shown a higher rate of complications in the so-called less invasive procedures [1-3].

In return, a 1998 experience performed with 120 patients comparing conventional technique with minimum incisions in aortic valve surgery has shown similar results regarding survival but significant different as to postoperative pain, requirement of hemotransfusion, minimum analgesia, and low-incidence arrhythmias in minimally invasive cases [4]. Mulinari et al., in 1997, in Brazil, also used ministernotomy in valve surgeries accomplishing promising results [5].

With the advent of videosurgery, technique implementation for vascular accesses, cannulae for CPB, and endoaortic clamping (port-access technology), the minimally invasive surgical procedures in cardiac surgery went off on a new tack with increasingly promising outcomes reported quite often [6-10].

Even with this breakthrough in surgical procedures, some studies are still discussing the procedure. In a series of 51 consecutive patients undergoing mitral valve replacement with port-access system, in-hospital mortality was 9.8% and a conversion into open surgery was performed in 3.9% of the patients due to endoaortic clamping

complications [9]. In return, another study evaluating 106 patients undergoing minithoracotomy and port-access approach has shown promising results as to ICU stay (mean ICU stay of 31 hours), no postoperative death, or surgical wound infection, and mean length of hospital stay was 5.6 days [6].

Since the last decade, multicenter studies are reported to show the efficacy of this new method. Galloway et al., in 1999, gathered data from 121 centers and included 1,063 patients operated on through minimally invasive techniques, displaying outcomes similar to those of conventional surgery, with an advantage of being less aggressive, relatively painless, and use of less blood products, besides a much earlier hospital discharge and return to daily activities as well [11].

Mishra et al. [12] gathered 776 patients who underwent mitral valve minimally invasive surgery and repair of atrial septal defect. Hospital mortality was 0.46% in the mitral valve group while there was no hospital mortality in atrial septal defect group. The minimally invasive procedure has become the standard approach for repair of atrial septal defect and isolated mitral valve procedures, according to the authors. The major distinguishing factors in relation to median sternotomy are faster recovery, cosmetic advantage, and more patient satisfaction.

Greco et al. [13], reporting their experience with 129 patients were convinced that minimally invasive procedure is a superior procedure for certain types of surgery, including mitral surgery and repair of a variety of atrial septal defects.

Besides the abovementioned experiences reported, many centers using high-end technology robotic devices have displayed their experiences, and despite the high-investment costs, they have highlighted the minimally invasive methods due to their low mortality, less ICU stay, and earlier hospital discharge.

Tatooles et al. [14], using robotically assisted surgery in 25 patients with mitral valve disease, have stressed besides remarkable perioperative outcomes, a highly reduced hospital stay with a mean length of hospital of 2.7 days. Between the first and second phases of the experiment, the length of stay was reduced from 4.2 days to 1.67 days until hospital discharge. The use of da Vinci robotically assisted surgery has allowed an excellent mitral valve repair management with primary repair successfully performed in all the cases.

Reichenspurner et al. [15,16], using a three-dimensional video and robotic assistance (VISTA system [Vista, Inc, Westborough, MA]) with voice-activated movement (AESOP 3000 [Computer Motion, Inc, Goleta, CA]), have reported an experiment with 50 patients undergoing mitral valve surgical procedure through minithoracotomy with no in-hospital mortality, and they have confirmed the

advantages of smaller incisions already reported in other recent studies.

Brazil has been included in this list through the experiments carried out by Jatene et al. [17], who in 1997 reported the use of videothoracoscopy to dissect the left internal thoracic artery (LITA) and its coronary implant through minithoracotomy. Seventy-three patients were operated on with a low index of complications and early hospital discharge. Souto et al. [18], in 2000, showed a technique of arterial canal closure through videothoracoscopy. In a series of 40 patients, Souto et al. have highlighted the simplicity and singularity of the new approach method. Salerno et al. [19], also in 2000, reported a similar experiment in a series of 15 children with ductus arteriosus patency. In their results they emphasized the excellent cosmetic result and the low index of complications. Even with these experiments, the Brazilian studies using video-assisted techniques are few and far between. No case at all had ever been reported nationwide when we started our studies using minimally invasive cardiac surgery for mitral valve repair or replacement.

Currently, the use of cardiac video-assisted surgery for heart valve disease, coronary disease, and congenital defects treatment is increasingly higher, lying in the skilled surgeons' hand the greater expansion and the ultimate consecration of these procedures [11,12,20,21].

The report of our experience aims to show the use of videosurgery in a wide variety of heart diseases; first, the cases performed in the heart's periphery, followed by the procedures involving peripheral CPB support in mitral valve surgery.

The cases concerning cardiac lipoma and coronary fistula (Figure 3) were included in the present study aiming to show the possibility of using a surgery video-assisted in common situations, stimulating surgeons to seek alternative approaches to smaller incisions. A research carried out in the current literature did not report experiments in these cases.

The implant of epicardial lead via left thoracoscopy to achieve ventricular resynchronization is well documented in the literature [22]. Its implementation was stimulated due to the variable degree of failure to implant left ventricle lead through coronary sinus. The new technique is simple and complete endoscopically performed; the approaches are not performed through thoracotomy as in the conventional method but through three small incisions for insertion of instruments and fixation of the active epicardial lead.

The summit of our experiment was to mimetize the international studies using mitral valve disease [12,13,20]. It was possible to perform mitral valve replacement in two cases through a CPB support established via femoral vessels and cardiac arrest under hypothermic ventricular fibrillation. The first was a mitral valve reoperation which

allowed a recommissurotomy by totally endoscopic approaches (Figure 4). Similar report was presented in surgery for an atrial septal defect correction with minimally invasive procedures; the procedure were achieved by totally endoscopic approaches [23,24].

Casselam et al. [25] reported the use of minimally invasive surgery in mitral valve reoperation with heart arrest under ventricular fibrillation. They considered the technique as the first option in cases of isolated mitral reoperation. The second case was related to a patient with dilated cardiopathy and atrial fibrillation, in which case was, performed successfully a mitral valve replacement with Gregori ring, ligature of left leaflet and ablation of pulmonary veins using a modified Mazze technique.

The small incisions are attractive for both medical staff and patient, leading to a lower incidence of infection and sternal dehiscence, lower incidence of postoperative pain and early hospital discharge are well documented in many current studies [20,21].

The discussion regarding the procedure high-cost is transient, because with a greater experience and better outcomes, the instrument costs have a trend to be increasingly reduced, provided more case are being treated by the video-assisted technique.

## CONCLUSION

Our initial experience in this Field shows the efficacy and feasibility of introducing this type of technique in Brazil. The results achieved in this series stimulate the studies using video-assisted cardiac surgery. The best cosmetic result and postoperative comfort to the patient, allowing his/her early return to normal activities, keep our perseverance for the continuity of this promising and accessible procedure.

## REFERENCES

1. Bridgewater B, Steyn RS, Ray S, Hooper T. Minimally invasive aortic valve replacement through a transverse sternotomy: a word of caution. *Heart*. 1998;79(6):605-7.
2. Szwerc MF, Benckart DH, Wiechmann RJ, Savage EB, Szydlowski GW, Magovern GJ Jr, et al. Partial versus full sternotomy for aortic valve replacement. *Ann Thorac Surg*. 1999;68(6):2209-13.
3. Kort S, Applebaum RM, Gross EA, Baumann FG, Colvin SB, Galloway AC, et al. Minimally invasive aortic valve replacement: echocardiographic and clinical results. *Ann Thorac Surg*. 2001;142(3):476-81.
4. Mächler HE, Bergmann P, Anelli-Monti M, Dacar D, Rehak P, Knez I, et al. Minimally invasive versus conventional aortic valve operations: a prospective study in 120 patients. *Ann Thorac Surg*. 1999;67(4):1001-5.
5. Mulinari LA, Tyszka AL, Costa FDA, Carvalho RG, Silva Junior AZ, Giublin R, et al. Mini-sternotomia: um acesso seguro para a cirurgia cardíaca. *Rev Bras Cir Cardiovasc*. 1997;12(4):335-9.
6. Aklog L, Adams DH, Couper GS, Gobeze R, Sears S, Cohn LH. Techniques and results of direct-access minimally invasive mitral valve surgery: a paradigm for the future. *J Thorac Cardiovasc Surg*. 1998;116(5):705-15.
7. Chitwood WR Jr, Wixon CL, Elbeery JR, Moran JF, Chapman WH, Lust RM. Video-assisted minimally invasive mitral valve surgery. *J Thorac Cardiovasc Surg*. 1997;114(5):773-80.
8. Grossi EA, LaPietra A, Ribakove GH, Delianides J, Esposito R, Culliford AT, et al. Minimally invasive versus sternotomy approaches for mitral reconstruction: comparison of intermediate-term results. *J Thorac Cardiovasc Surg*. 2001;121(4):708-13.
9. Morh FW, Falk V, Diegeler A, Walther T, van Son JA, Autschbach R. Minimally invasive port-access mitral valve surgery. *J Thorac Cardiovasc Surg*. 1998;115(3):567-74.
10. Stevens JH, Burdon TA, Peters WS, Siegel LC, Pompili MF, Vierra MA, et al. Port-access coronary artery bypass grafting: a proposed surgical method. *J Thorac Cardiovasc Surg*. 1996;111(3):567-73.
11. Galloway AC, Shemin RJ, Glower DD, Boyer JH Jr, Groh MA, Kuntz RE, et al. First report of the Port Access International Registry. *Ann Thorac Surg*. 1999;67(1):51-6.
12. Mishra YK, Khanna SN, Wasir H, Sharma KK, Mehta Y, Trehan N. Port-access approach for cardiac surgical procedures: our experience in 776 patients. *Indian Heart J*. 2005;57(6):688-93.
13. Greco E, Barriuso C, Castro MA, Fita G, Pomar JL. Port-Access cardiac surgery: from a learning process to the standard. *Heart Surg Forum*. 2002;5(2):145-9.
14. Tatoes AJ, Pappas PS, Gordon PJ, Slaughter MS. Minimally invasive mitral valve repair using the da Vinci robotic system. *Ann Thorac Surg*. 2004;77(6):1978-82.
15. Reichenspurner H, Boehm D, Reichart B. Minimally invasive mitral valve surgery using three-dimensional video and robotic assistance. *Semin Thorac Cardiovasc Surg*. 1999;11(3):235-43.
16. Reichenspurner H, Boehm DH, Gulbins H, Schulze C, Wildhirt S, Welz A, et al. Three-dimensional video and robot-assisted port-access mitral valve operation. *Ann Thorac Surg*. 2000;69(4):1176-81.

- 
17. Jatene FB, Pego-Fernandes PM, Assad RS, Dallan LA, Hueb W, Arbulu HEVD, et al. Cirurgia de revascularização do miocárdio minimamente invasiva: resultados com o uso da videotoracoscopia e do estabilizador de sutura. *Rev Bras Cir Cardiovasc.* 1997;12(3):233-8.
  18. Souto GLL, Tinoco RC, Tinoco ACA, Caetano CS, Souza JB, Paula AG, et al. Ligadura videotoroscópica da persistência do canal arterial. *Rev Bras Cir Cardiovasc.* 2000;15(2):154-9.
  19. Salerno PR, Jatene MB, Santos MA, Ponce F, Bosísio IBJ, Fontes VF, et al. Fechamento de canal arterial por minitoracotomia: técnica e resultados. *Rev Bras Cir Cardiovasc.* 2000;15(3):234-7.
  20. Grossi EA, Galloway AC, LaPietra A, Ribakove GH, Ursomanno P, Delianides J, et al. Minimally invasive mitral valve surgery: a 6-year experience with 714 patients. *Ann Thorac Surg.* 2002;74(3):660-3.
  21. Woo YJ, Nacke EA. Robotic minimally invasive mitral valve reconstruction yields less blood product transfusion and shorter length of stay. *Surgery.* 2006;140(2):263-7.
  22. Navia JL, Atik FA, Grimm RA, Garcia M, Vega PR, Myhre U, et al. Minimally invasive left ventricular epicardial lead placement: surgical techniques for heart failure resynchronization therapy. *Ann Thorac Surg.* 2005;79(5):1536-44.
  23. Argenziano M, Oz MC, DeRose JJ Jr, Ashton RC Jr, Beck J, Wang F, et al. Totally endoscopic atrial septal defect repair with robotic assistance. *Heart Surg Forum.* 2002;5(3):294-300.
  24. Torracca L, Ismeno G, Quarti A, Alfieri O. Totally endoscopic atrial septal defect closure with a robotic system: experience with seven cases. *Heart Surg Forum.* 2002;5(2):125-7.
  25. Casselman FP, La Meir M, Jeanmart H, Mazzarro E, Coddens J, Van Praet F, et al. Endoscopic mitral and tricuspid valve surgery after previous cardiac surgery. *Circulation.* 2007;116(11 Suppl):I270-5.