

# Percutaneous Closure of Small *Ostium secundum* Atrial Septal Defects

Francisco Chamié<sup>1</sup>, Daniel Chamié<sup>2</sup>

## ABSTRACT

**Background:** Small atrial septal defects are usually well tolerated in childhood but may present problems later in life. The percutaneous occlusion of such defects is safe and presents very low risk, but is questioned. This manuscript was aimed at evaluating the results of the percutaneous occlusion of small defects and patients' mid-term follow-up. **Methods:** Retrospective analysis of percutaneous closure procedures performed in patients with *ostium secundum* atrial septal defects whose static diameters were  $\leq 6$  mm. **Results:** From November 2003 to March 2014, procedures performed in 34 patients were evaluated. Of these, 22 were female, with ages ranging from 2 to 60 years. The static diameters ranged between 2 to 6 mm and a mean increase of 55% was observed after balloon sizing. Implants were feasible in all of the cases and each patient received one device, of different types and brands. There were no deaths and all patients had their defects completely closed. There was only one minor complication during the procedure and a major complication 4 months after the procedure in another patient. **Conclusions:** The percutaneous closure of small *ostium secundum* atrial septal defects was safe and effective. The good results of occlusion procedures suggest that the use of devices may be considered the treatment of choice for *ostium secundum* atrial septal defects  $\leq 6$  mm.

**DESCRIPTORS:** Heart septal defects, atrial. Cardiac catheterization. Septal occluder device. Prostheses and implants.

## RESUMO

### Fechamento Percutâneo de Pequenas Comunicações Interatriais Tipo *Ostium secundum*

**Introdução:** As comunicações interatriais pequenas são geralmente bem toleradas na infância, mas podem apresentar problemas na vida adulta. O procedimento de oclusão percutânea desses defeitos é seguro e apresenta baixíssimo risco, mas é questionado. Este manuscrito objetivou avaliar os resultados do fechamento de defeitos considerados pequenos e sua evolução a médio prazo. **Métodos:** Análise retrospectiva dos procedimentos de oclusão em pacientes portadores de comunicações interatriais tipo *ostium secundum* cujos diâmetros estáticos eram  $\leq 6$  mm. **Resultados:** De novembro de 2003 a março de 2014, foram analisados os procedimentos realizados em 34 pacientes, dos quais 22 eram do sexo feminino, com idades variando de 2 a 60 anos. Os diâmetros estáticos variaram de 2 a 6 mm e apresentaram um aumento médio de 55% após o uso do balão medidor. Os implantes foram possíveis em todos os casos e foi utilizado um dispositivo por paciente, de diferentes tipos e marcas. Não ocorreram óbitos e todos os pacientes apresentaram oclusão completa de seus defeitos. Houve apenas uma complicação menor durante um procedimento e uma complicação maior, após 4 meses, em outro paciente. **Conclusões:** A oclusão percutânea de pequenas comunicações interatriais tipo *ostium secundum* foi segura e eficaz. Os bons resultados dos procedimentos de oclusão sugerem que o uso de dispositivos possa vir a ser considerado o tratamento de escolha das comunicações interatriais tipo *ostium secundum*  $\leq 6$  mm.

**DESCRIPTORES:** Comunicação interatrial. Cateterismo cardíaco. Dispositivo para oclusão septal. Próteses e implantes.

<sup>1</sup> Hospital Federal dos Servidores do Estado, Rio de Janeiro, RJ, Brazil.

<sup>2</sup> Instituto Dante Pazzanese de Cardiologia, São Paulo, SP, Brazil.

**Correspondence to:** Francisco Chamié. Intercat – Cardiologia Intervencionista – Rua Real Grandeza, 108, salas 223-224 – Botafogo – CEP: 22281-034 – Rio de Janeiro, RJ, Brazil  
E-mail: fchamie@pobox.com

Received on: 06/05/2014 • Accepted on: 08/23/2014

**A**trial septal defects (ASD) are very prevalent, ranging from 7 to 11% of all congenital heart defects.<sup>1,2</sup> These are generally well tolerated, and ASD diagnosis can be difficult in childhood, due to the low expression of clinical symptoms. Not infrequently, this defect is not discovered until adulthood, at a more advanced age, or haphazardly, during a survey for other heart conditions.<sup>3</sup>

Small defects are known to have the possibility of spontaneous closure, but they can also become larger, to the point of precluding their occlusion through the use of devices.<sup>4</sup> Some authors have pointed out that adult individuals with *ostium secundum* ASD (osASD) are at increased risk of adverse cardiovascular events if the defect is not closed, and emphasize the importance of an earlier correction, before the onset of complications, such as atrial fibrillation (AF), pulmonary arterial hypertension, and right-ventricular failure.<sup>5-7</sup> Although they are not candidates for surgical correction, small defects should not be excluded from transcatheter percutaneous closure which, in such cases, is a fairly simple procedure with high success rate and a very low risk of complications in qualified hands.<sup>6</sup>

The aim of this study was to evaluate the results, in the medium and long term, in patients with small osASD undergoing transcatheter percutaneous closure. Indications for occlusion were discussed, and the complications encountered were evaluated.

## METHODS

### Study design

This monocentric, single-arm study presents a retrospective review of patients with small osASD undergoing percutaneous closure with different prostheses.

### Patient selection

This study retrospectively analyzed the clinical records of all patients with osASD referred for percutaneous closure, and whose defects had a static diameter  $\leq 6$  mm by transesophageal echocardiography (TEE). Patients with patent foramen ovale (PFO) or multifenestrated communications, who needed more than one device for occlusion, were excluded from this analysis.

### Procedure

All patients underwent general anesthesia and orotracheal intubation, after at least 8 hours of fasting. Patients underwent right and left heart catheterization via femoral vein puncture and under monitoring by TEE (three-dimensional type, when available). Angiography was not performed.

Heparin was administered at doses of 100 IU/kg for children or 5,000 to 10,000 IU for adults, after obtaining venous access and following the introduction

of the transesophageal probe. A dose of cefazolin (50 mg/kg in children or 2 g in adults) was administered.

The stretched diameter (SD) measurement of the defect, with an appropriate balloon provided by the manufacturer, was performed in all cases. The choice of the prosthesis was based on the SD, using devices ranging from the exact size up to 2 mm above the SD. The prosthesis was loaded through the long sheath with a compatible size, according to manufacturer specifications, and released by usual techniques, previously detailed.<sup>8</sup>

After the procedure, patients were followed in the closed unit and were discharged after performing a control transthoracic echocardiogram (TTE).

## FOLLOW-UP

All patients were advised to use acetylsalicylic acid (3-5 mg/kg/day in children and 200 mg/day in adults) for 6 months. Since 2007, the use of clopidogrel 75 mg for 3 months in adults has been associated. It was recommended to observe procedures for infective endocarditis prophylaxis for 6 months, when necessary.

TTEs were performed after 1, 3, and 12 months, and then yearly. A TEE was performed at the 6<sup>th</sup> month.

## Statistical analysis

Continuous variables were expressed as means and standard deviations, and categorical variables as numbers and percentages. The comparison between the values of the static diameters (measured by TEE) and of stretched diameters of osASDs was performed with the Wilcoxon's signed-rank test for paired samples.

## RESULTS

From November 2003 to March 2014, 514 patients underwent osASD occlusion. Of these, 34 (6.6%) had defects whose static diameter, measured by TEE, was  $\leq 6$  mm. Twenty-two patients were female, and 12 patients were male, with a ratio of 1.8:1. Their ages ranged from 2 to 60 years ( $22 \pm 18.2$  years), and their weights from 12 to 98 kg ( $60 \pm 20.7$  kg).

A 2-year-old patient was suffering from pulmonary atresia without ventricular septal defect and required palliative surgery (modified Blalock-Taussig shunt) in the neonatal period; subsequently, this child was subjected to pulmonary valve perforation with radiofrequency, with good results. A hemodynamic study showed that the pulmonary valve was cleared and that the pulmonary blood flow was normal. The modified Blalock-Taussig shunt was occluded with a vascular plug and, as this patient presented severe cyanosis due to right-to-left shunt through the ASD, an occlusion of the defect at the age of 2 was conducted.

Six patients, mistakenly diagnosed with PFO, were diagnosed with osASD and referred for occlusion. Four patients had suffered ischemic stroke, and two professional divers were referred due to a decompression accident.

A 6-year-old patient showed high systolic pulmonary pressure (40 mmHg), which returned to normal level (25 mmHg) immediately after the occlusion of the defect.

An atrial septal aneurysm was present in three cases. Four patients had additional orifices with multiple fenestrations, besides the main orifice; all defects were closed with a single device. Two patients had their osASD previously occluded with GORE® HELEX® prostheses and showed significant residual shunts, requiring a new device. Both showed significant flow passage through the lateral edge of the prosthesis, with orifices that measured 8 and 8.5 mm, respectively, with the measuring balloon.

The diameters of the main static orifices ranged from 2 to 6 mm ( $4.5 \pm 1.1$  mm), and the stretched diameters from 5 to 16 mm ( $10 \pm 3.0$  mm). The use of the measuring balloon caused a mean increase of 55% compared to the static diameter of the defects (Figure 1).

It was possible to perform the implantation in all patients; different types of devices were used, in appropriate sizes: Amplatzer® ASD Occluder (St. Jude Medical Inc., St. Paul, United States) in eight patients; Cardia® ASD Occluder (PFM Medical Ag, Koln, Germany) in seven; Occlutech® ASD Occluder (Occlutech AB, Helsingborg, Sweden) in five; Lifetech Cera® ASD Occluder (Lifetech Scientific Corporation, Shenzhen, China) in five; Cardia® PFO Occluder (PFM Medical Ag, Koln, Germany) in three; Amplatzer® Cribiform Occluder (St. Jude Medical Inc., St. Paul, United States) in two; and GORE® HELEX® Septal Occluder (W. L. Gore & Associate, Newark, United States), Lifetech Cera® PDA Occluder (Lifetech Scientific Corporation, Shenzhen, China), Nit-Occlud® ASD-R (PFM Medical Ag, Koln, Germany), and Cocoon ASD Occluder (Vascular Innovations Co. Ltd., Bangtanai, Pakkret, Thailand) in one patient each.

During the procedures, only one minor complication was found. ATEE study detected a threadlike thrombus in the right atrium, adhered to the exchange guide of a patient. This complication was attributed to an ineffective anticoagulation. An additional dose of heparin was applied, with a careful removal of the device, which was washed and reintroduced, allowing the implant to be performed with the traditional technique. There were no sequelae resulting from this thrombus, which was not visualized on TEE after removal of the guide.

Two patients had episodes of migraine in the first weeks after implantation. The Amplatzer® ASD Occluder was used in one of these patients, and the Occlutech® ASD Occluder was used in the other. In both cases, the migraine subsided after the addition of 75 mg of clopidogrel to acetylsalicylic acid. There were no deaths in this study.

Mean follow-up was 67.5 months (3-132 months). The only significant event occurred in one patient, a professional diver, who had been treated by occlusion of the defect with a 16 mm Cardia® ASD Occluder after a decompression accident. In the fourth month after the procedure, an organized thrombus which had adhered to the right disk of the device was identified. The event was attributed to the irregular use of antiplatelet agents. The thrombus could not be eliminated with anticoagulation, and its removal was performed surgically. No patient showed a periprosthetic residual shunt.

## DISCUSSION

There is controversy in the literature about size criteria that define a small ASD. In most studies, their criteria were arbitrarily chosen, without a physiological basis. From a hemodynamic point of view, Brassard et al.,<sup>9</sup> using TTE, rated as minor defects those measuring < 6 mm; and as large defects those  $\geq 6$  mm, above 1 year of age. McMahan et al.,<sup>10</sup> also using TTE, regarded as minor defects those whose diameter ranged from 3-6 mm; as moderate those from 6-12 mm; and as major defects those > 12 mm. Geva et al.<sup>11</sup> considered as minor defects those measuring > 3 mm and < 5 mm. These authors reported that defects < 10 mm in diameter are associated with a small shunt, with minimal or no increase in right cavities. They also consider that in case of a defect > 10 mm, the ratio of pulmonary/systemic blood flow ( $Q_p/Q_s$ ) is > 1.5:1, and in this scenario a cascade of changes in the myocardium and pulmonary vasculature could occur. Saxena et al.<sup>12</sup> considered as minor defects those measuring from 4 and 5 mm.

Importantly, these authors classified the defects based on images of two-dimensional transthoracic echocardiograms, which introduce some margin of error, since they assessed defects that had mostly an oval or elliptical shape and, therefore, exhibited varying diameters, depending on the plan in which the septum was interrogated by the ultrasound beam (Figure 2).<sup>13-15</sup>

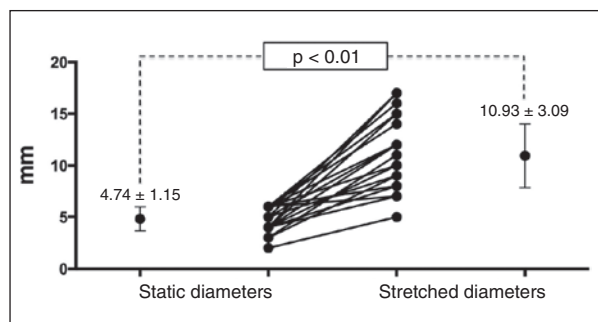


Figure 1 – Comparison between static and stretched diameters of defects, showing wide variability in increases after using the measuring balloon.

In this study, only those defects considered as small-sized were included ( $\leq 6$  mm diameter on two-dimensional TEE). This cut-off point was decided upon because it is a near-consensus in the literature, and because the searched studies reported absence of right cavity overload in these defects at a pre-procedural TEE. As demonstrated, there is wide variation between the static diameter and the SD of the defects. The use of the measuring balloon significantly increased the diameter of osASDs. There are three possible explanations: the low sensitivity of two-dimensional echo in determining the defect edge, particularly in non-spherical defects; excessive compliancy of the edges; and, while the balloon is theoretically a more compliant device, the possibility of edge rupture, resulting in increases in the diameter of the defect.

Most centers perform occlusive procedures in 4- or 5-year-old patients, based on the premise that there is a possibility of spontaneous closure in childhood. Reports of spontaneous closure up to adolescence, although much less frequent, have also been published, which reinforces the conservative approach of most authors.<sup>16,17</sup> Hanslik et al.<sup>18</sup> reported the occurrence of spontaneous closure in approximately 56% of defects measuring between 4 and 5 mm, 30% between 6 and 7 mm, and 12% between 8 and 10 mm. None of the defects measuring  $> 10$  mm resulted in spontaneous closure. Other authors reported similar observations, with spontaneous closure rates ranging from 12 to 82% in small ASDs.<sup>4,9,10,12</sup>

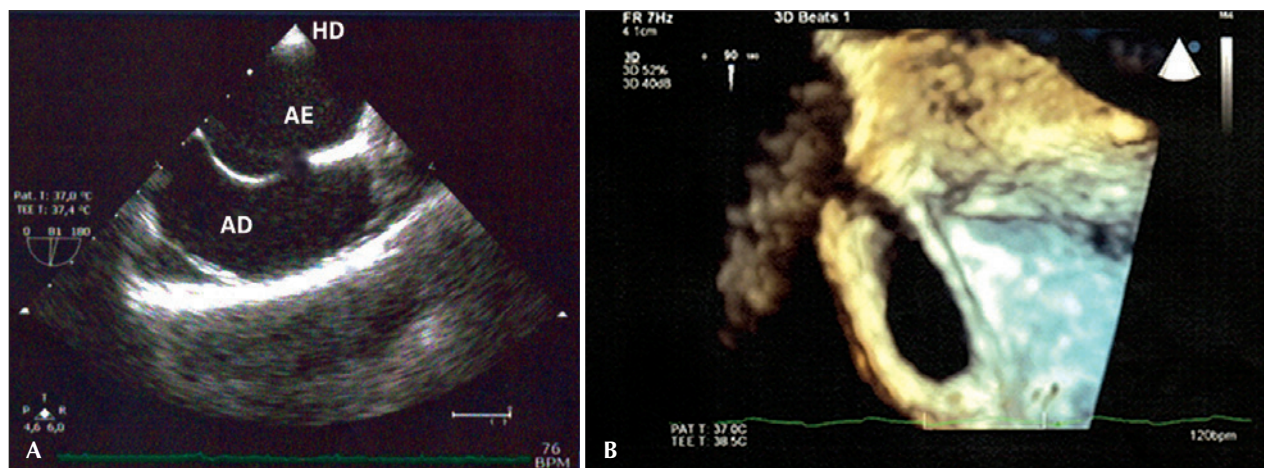
With respect to small defects, it is common belief that these defects remain asymptomatic and hemodynamically insignificant; nevertheless, the possibility of increases in defect size throughout life cannot be excluded. Among the defects without spontaneous closure, the defect size may increase with age, and may even increase to a point that will defeat any attempt

of percutaneous occlusion.<sup>19</sup> In the series of Hanslik et al.,<sup>18</sup> 18% of defects with  $< 4$  mm increased in size. McMahon et al.<sup>10</sup> reported that 63% of small defects increased in size, with an increase of 1.6 mm per year in patients with a mean follow-up of 38 months (9-85 months). In other studies, the small defects increased sufficiently so as to require surgical or percutaneous occlusion with the use of devices.<sup>4,11,12</sup>

In adults, small osASD may be more harmful than in children. Symptoms rarely reported in childhood are most commonly found in adults, appearing on average at the age of 33 years.<sup>3</sup> Adults suffering from congenital heart defect are more likely to suffer major adverse cardiovascular events (heart failure, arrhythmias, and stroke) compared with controls. Patients with osASD were those individuals who benefited most from surgical correction, in terms of reducing the risk of major adverse cardiovascular events at follow-up (adjusted hazard ratio 0.3; 95% confidence interval 0.3-0.5;  $p < 0.0001$ ).<sup>7</sup>

Atrial arrhythmias are part of late natural history of osASD, and are associated with significant morbidity and mortality, mainly in patients of older age groups. These conditions are associated with congestive heart failure and embolic events, among them stroke. Tachyarrhythmias (flutter and AF) are uncommon events in individuals younger than 40 years, with a reported incidence of 1%. Over 40 years of age, their prevalence increases disproportionately, when compared to the normal population, ranging from 15% between 40 and 60 years to 61% above the sixth decade of life.<sup>20,21</sup>

osASD occlusion is associated with a progressive normalization of the diameters of the right cavities and, as might be anticipated, the earlier the correction, the higher its frequency.<sup>22</sup> Although there may be a regression of atrial flutter after correction of osASD,



**Figure 2** – In A, two-dimensional image of a small *ostium secundum* type atrial septal defect (osASD) obtained by transesophageal echo. In B, three-dimensional image of the same osASD, clearly showing its elliptical shape and the presence of edges in the entire contour of the defect.

the same does not occur with AF, which usually require electrophysiological procedures besides the occlusion of the defects for heart rhythm normalization.<sup>20</sup>

The incidence of AF onset after percutaneous occlusion with devices is estimated to be 7% for PFO and 12% for osASD, regardless of device type and size. Again, patients diagnosed with post-occlusion AF are older than other patients.<sup>23</sup> This incidence is higher than that expected in general population; but these results may be challenged, in that it is unclear whether the occurrence of AF was indeed caused by the device, or whether these patients would have developed changes that could cause AF, even without the correction of defects.<sup>24</sup>

Interestingly, the incidence of AF after surgical correction is comparable to that for percutaneous closure: 14% among patients who underwent percutaneous occlusion and 16% among those who underwent surgery.<sup>25</sup>

Regardless of patient's rhythm, the presence of paradoxical embolism is also a complication of osASDs, especially defects of small dimensions. Patients presenting with embolic events, with the exception of patients with PFO, tend to be female, younger, and with smaller defects, when compared to osASD patients, who did not exhibit paradoxical embolism (Figure 3).<sup>26</sup>

Studies have shown that, among patients with episodes of paradoxical embolism and who were referred for percutaneous closure of their atrial septal defects, 11% had osASD, 9% had osASD and PFO, and 80% had PFO. These data suggest that the risk of paradoxical embolism is considerable in patients with osASD (Figure 4).<sup>27</sup>

The wide variety of models and brands of prostheses used was not due to any particular criterion. PFO occlusion prostheses were employed in those cases in which the initial diagnosis was mistaken. In these cases, the patients had small central orifices with appropriate

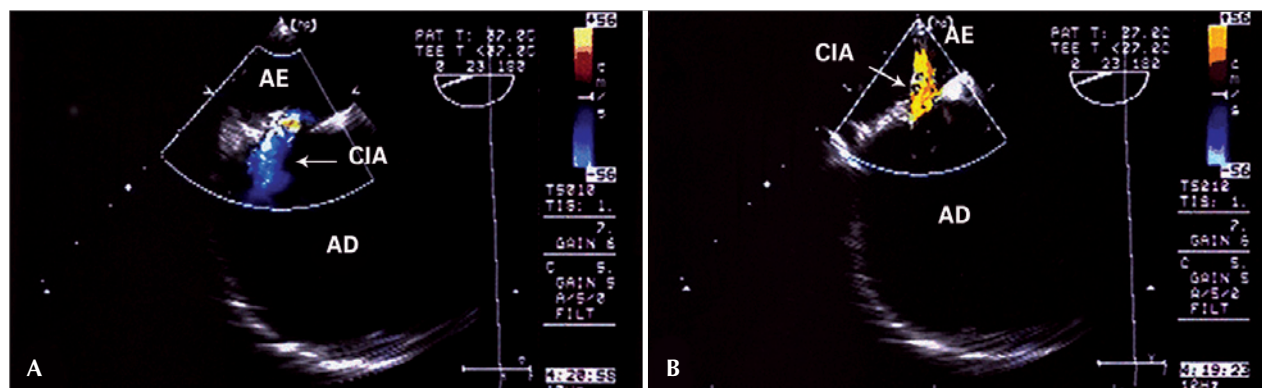


Figure 3 – Color flow mapping of a small *ostium secundum* type atrial septal defect in two phases of the cardiac cycle. In A, the color Doppler reveals a normal flow from left-to-right atrium. In B, the color Doppler detects the reverse transit flow, from right to left.

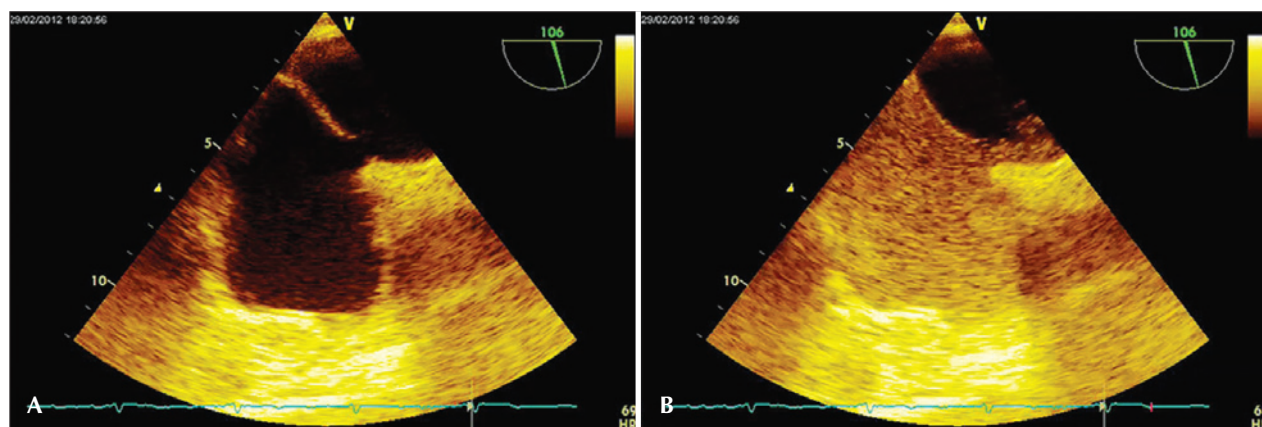
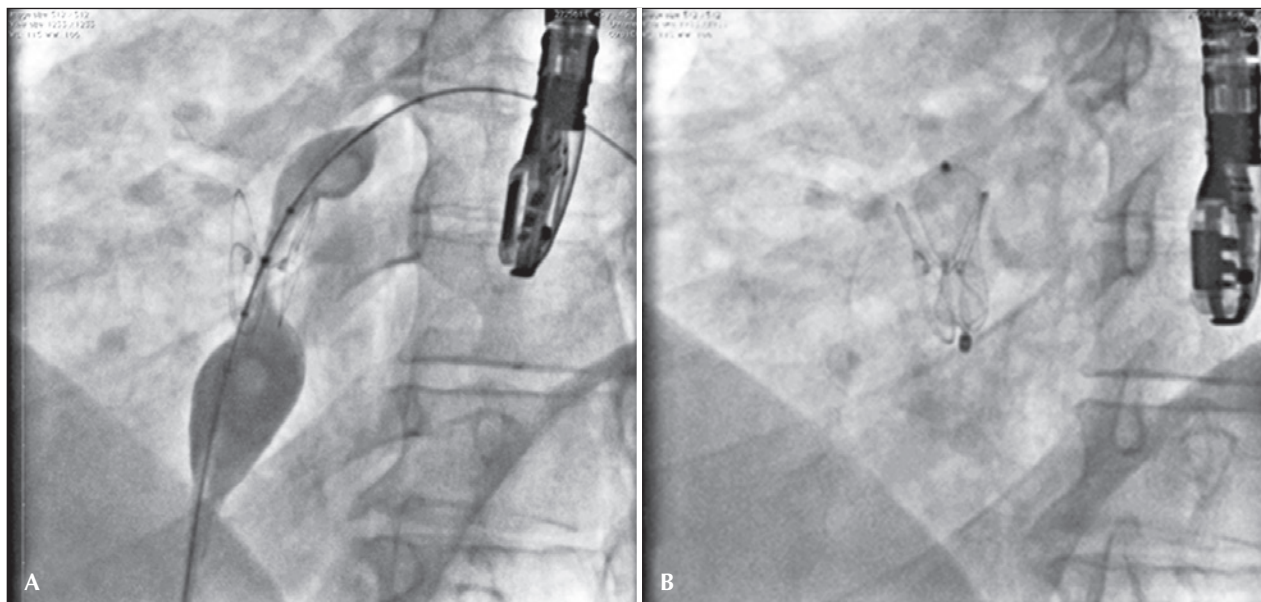


Figure 4 – Transesophageal echocardiography of a small *ostium secundum*-type atrial septal defect, performed during the occlusion of the defect in a professional diver who had suffered a decompression accident. In A, the size of the defect in the area of oval fossa can be seen. In B, the agitated saline bubble test, performed through the venous sheath, showing a great transit of microbubbles through the defect during normal breathing.



**Figure 5** – Patient who had *ostium secundum*-type atrial septal defect occluded with a HELEX® prosthesis. In A, the prosthesis in proper position and configuration can be observed. The residual orifice is outlined by a measuring balloon, between the two discs of the device. In B, the Cera® PDA Occluder (Lifetech) is visualized, perfectly conforming to the anatomy of the orifice, and completely occluding the defect.

edges, and available prostheses were suited to the types of defects found. In a case of residual shunt with a long and tapered orifice, it was decided to use patent ductus arteriosus occlusion prosthesis, well suited to the anatomy of the defect (Figure 5).

## CONCLUSIONS

The results of this study showed that, in line with the literature, the percutaneous occlusion of small *ostium secundum*-type atrial septal defects was a safe and effective procedure, with very few complications in the short and medium term. It would be desirable a long-term longitudinal follow-up to establish a valid correlation between the defect size and its evolution in patients of older age groups. Randomized, double-blinded controlled studies are still needed to validate the use of percutaneously implanted devices targeting the treatment of atrial septal defects measuring  $\leq 6$  mm.

## CONFLICTS OF INTEREST

The authors declare no conflicts of interest.

## FUNDING SOURCES

None.

## REFERENCES

1. Feldt RH, Avasthey P, Yoshimasu F, Kurland LT, Titus JL. Incidence of congenital heart disease in children born to residents of Olmsted County, Minnesota, 1950-1969. *Mayo Clin Proc.* 1971;46(12):794-9.

2. Keith J. Atrial septal defect: ostium secundum, ostium primum and atrioventricularis communis (common AV canal). In: Keith J, Rowe R, Vlad P, editors. *Heart disease in infancy and childhood.* 3rd ed. New York: MacMillan; 1978. p. 380-404.
3. Forfang K, Simonsen S, Andersen A, Efskind L. Atrial septal defect of secundum type in the middle-aged. Clinical results of surgery and correlations between symptoms and hemodynamics. *Am Heart J.* 1977;94(1):44-54.
4. Azhari N, Shihata MS, Al-Fatani A. Spontaneous closure of atrial septal defects within the oval fossa. *Cardiol Young.* 2004;14(2):148-55.
5. Cheng TO. All atrial septal defects should be closed. *Int J Cardiol.* 2014;175(2):224-5.
6. Meier B. Percutaneous closure of atrial septal defects—more roads lead to Rome than meets the eye. *Catheter Cardiovasc Interv.* 2011;78(5):675-6.
7. Lin YS, Liu PH, Wu LS, Chen YM, Chang CJ, Chu PH. Major cardiovascular events in adult congenital heart disease: a population-based follow-up study from Taiwan. *BMC Cardiovasc Disord.* 2014;14:38.
8. Chamie FCD, Ramos S, Tress JC, Victor R. Fechamento percutâneo das comunicações interatriais (CIA) complexas. *Rev Bras Cardiol Invasiva.* 2006;14(1):47-55.
9. Brassard M, Fouron JC, van Doesburg NH, Mercier LA, De Guise P. Outcome of children with atrial septal defect considered too small for surgical closure. *Am J Cardiol.* 1999;83(11):1552-5.
10. McMahon CJ, Feltes TF, Fraley JK, Bricker JT, Grifka RG, Tortoriello TA, et al. Natural history of growth of secundum atrial septal defects and implications for transcatheter closure. *Heart.* 2002;87(3):256-9.
11. Geva T, Martins JD, Wald RM. Atrial septal defects. *Lancet.* 2014;383(9932):1921-32.
12. Saxena A, Divekar A, Soni NR. Natural history of secundum atrial septal defect revisited in the era of transcatheter closure. *Indian Heart J.* 2005;57(1):35-8.

13. Ferreira SM, Ho SY, Anderson RH. Morphological study of defects of the atrial septum within the oval fossa: implications for transcatheter closure of left-to-right shunt. *Br Heart J.* 1992;67(4):316-20.
14. Roberson DA, Cui W, Patel D, Tsang W, Sugeng L, Weinert L, et al. Three-dimensional transesophageal echocardiography of atrial septal defect: a qualitative and quantitative anatomic study. *J Am Soc Echocardiogr.* 2011;24(6):600-10.
15. Kim KH, Song J, Kang IS, Chang SA, Huh J, Park SW. Balloon occlusive diameter of non-circular atrial septal defects in transcatheter closure with amplatzer septal occluder. *Korean Circ J.* 2013;43(10):681-5.
16. Cockerham JT, Martin TC, Gutierrez FR, Hartmann AF Jr, Goldring D, Strauss AW. Spontaneous closure of secundum atrial septal defect in infants and young children. *Am J Cardiol.* 1983;52(10):1267-71.
17. Hartmann AF Jr, Elliott LP. Spontaneous physiologic closure of an atrial septal defect after infancy. *Am J Cardiol.* 1967;19(2):290-2.
18. Hanslik A, Pospisil U, Salzer-Muhar U, Greber-Platzer S, Male C. Predictors of spontaneous closure of isolated secundum atrial septal defect in children: a longitudinal study. *Pediatrics.* 2006;118(4):1560-5.
19. Tortoriello TA, McMahon C, Kovalchin JP, Bricker JT, Grifka RG. Growth of an atrial septal defect: missing the window for transcatheter closure. *Pediatr Cardiol.* 2002;23(5):542-4.
20. Berger F, Vogel M, Kramer A, Alexi-Meskishvili V, Weng Y, Lange PE, et al. Incidence of atrial flutter/fibrillation in adults with atrial septal defect before and after surgery. *Ann Thorac Surg.* 1999;68(1):75-8.
21. Oliver JM, Gallego P, Gonzalez AE, Benito F, Sanz E, Aroca A, et al. Surgical closure of atrial septal defect before or after the age of 25 years: comparison with the natural history of unoperated patients. *Rev Esp Cardiol.* 2002;55(9):953-61.
22. Veldtman GR, Razack V, Siu S, El-Hajj H, Walker F, Webb GD, et al. Right ventricular form and function after percutaneous atrial septal defect device closure. *J Am Coll Cardiol.* 2001;37(8):2108-13.
23. Spies C, Khandelwal A, Timmermanns I, Schrader R. Incidence of atrial fibrillation following transcatheter closure of atrial septal defects in adults. *Am J Cardiol.* 2008;102(7):902-6.
24. Knirsch W, Dodge-Khatami A, Valsangiacomo-Buechel E, Weiss M, Berger F. Challenges encountered during closure of atrial septal defects. *Pediatr Cardiol.* 2005;26(2):147-53.
25. Oliver JM, Gallego P, Gonzalez A, Benito F, Mesa JM, Sobrino JA. Predisposing conditions for atrial fibrillation in atrial septal defect with and without operative closure. *Am J Cardiol.* 2002;89(1):39-43.
26. Bannan A, Shen R, Silvestry FE, Herrmann HC. Characteristics of adult patients with atrial septal defects presenting with paradoxical embolism. *Catheter Cardiovasc Interv.* 2009;74(7):1066-9.
27. Khositseth A, Cabalka AK, Sweeney JP, Fortuin FD, Reeder GS, Connolly HM, et al. Transcatheter Amplatzer device closure of atrial septal defect and patent foramen ovale in patients with presumed paradoxical embolism. *Mayo Clin Proc.* 2004;79(1):35-41.