

Partial Congenital Absence of Pericardium

José Luis Attab dos Santos¹, Clemente Greguolo², José Fábio Fabris Junior³, Alan Nascimento Paiva⁴, Henrique Simão Trad⁵, Taisa Tavares de Andrade⁶

ABSTRACT

Agenesis of the pericardium is a rare congenital anomaly, which is difficult to diagnose. We report a case of a 42-year-old patient, with atypical chest pain, electrocardiogram with an incomplete right bundle branch block, chest X-ray with a counterclockwise heart axis deviation and echocardiogram suggesting right ventricle volume overload. Cardiac catheterization showed no intracardiac shunts, and rotation and displacement of the heart into the left hemithorax. Magnetic nuclear resonance imaging confirmed the diagnosis by revealing partial absence of the left pericardium, with interposition of lung parenchyma between the main pulmonary artery and the aorta.

DESCRIPTORS: Heart defects, congenital. Pericardium. Diagnostic imaging.

Agenesis of the pericardium is a rare congenital anomaly (1:14.000 in necroscopic series) that is more prevalent in the male gender (1:3), is occasionally detected during intrathoracic surgeries (or necropsy examinations), and is difficult to diagnose in clinical practice.¹⁻⁵ A case of partial congenital absence of the pericardium is reported. The patient was referred to the Department of Haemodynamics of the Hospital das Clínicas Samuel Libânio da Faculdade de Medicina de Pouso Alegre (Pouso Alegre, MG, Brazil) for diagnosis confirmation.

CASE REPORT

A 42-year-old male patient complaining of atypical chest pain was admitted to the Department of

RESUMO

Ausência Parcial Congênita do Pericárdio

A ausência congênita do pericárdio é uma anomalia congênita rara, de difícil diagnóstico. Relatamos um caso de paciente de 42 anos, com dor torácica atípica, eletrocardiograma com distúrbio de condução no ramo direito, radiografia de tórax com desvio do eixo cardíaco no sentido antihorário e ecocardiograma sugerindo sobrecarga de volume do ventrículo direito. Cateterismo cardíaco demonstrou ausência de *shunts* intracardíacos, e rotação e deslocamento do coração para o hemitórax esquerdo. Ressonância nuclear magnética confirmou o diagnóstico ao demonstrar ausência parcial do pericárdio à esquerda, com interposição do parênquima pulmonar entre o tronco da artéria pulmonar e a aorta.

DESCRITORES: Cardiopatias congênitas. Pericárdio. Diagnóstico por imagem.

Haemodynamics of the Hospital das Clínicas Samuel Libânio da Faculdade de Medicina de Pouso Alegre for confirmation of suspected congenital heart disease. Electrocardiogram (ECG) showed right branch conduction disturbance, and chest X-ray showed counterclockwise heart axis deviation (Figure 1). Echocardiography showed normal dimensions, as well as left ventricular function and right ventricular volume overload, with no evidence of tricuspid regurgitation or intracardiac shunts.

The patient was submitted to cardiac catheterization via femoral access with arterial and venous puncture under local anaesthesia. After puncturing the femoral vein, the catheter was introduced until the right atrium and the superior-inferior cava concordance was established, defining the atrial *situs solitus*. The passage of

¹ Interventionist Cardiologist Physician and Director at Hemodynamics and Invasive Cardiology of Santa Casa de Ribeirão Preto. Ribeirão Preto, SP, Brazil.

² Interventionist Cardiologist Physician at Hemodynamics and Cardiology Service of Santa Casa de Ribeirão Preto. Ribeirão Preto, SP, Brazil.

³ Interventionist Cardiologist Physician at Hemodynamics and Invasive Cardiology at Santa Casa de Ribeirão Preto. Ribeirão Preto, SP, Brazil.

⁴ Interventionist Cardiologist Physician at Hemodynamics and Invasive Cardiology at Hospital das Clínicas Samuel Libânio de Pouso Alegre. Pouso Alegre, MG, Brazil.

⁵ Radiologist Physician at Centro Diagnóstico por Imagem. Ribeirão Preto, SP, Brazil.

⁶ Echocardiographist Cardiologist Physician at Centro Diagnóstico Cardiovascular. Ribeirão Preto, SP, Brazil.

Correspondence to: José Luis Attab dos Santos. Av. Saudade, 456 – Campos Elíseos – Ribeirão Preto, SP, Brazil – CEP 14085-000
E-mail: joseluis@hci.med.br

Received on: 6/26/2012 • Accepted on: 10/18/2012

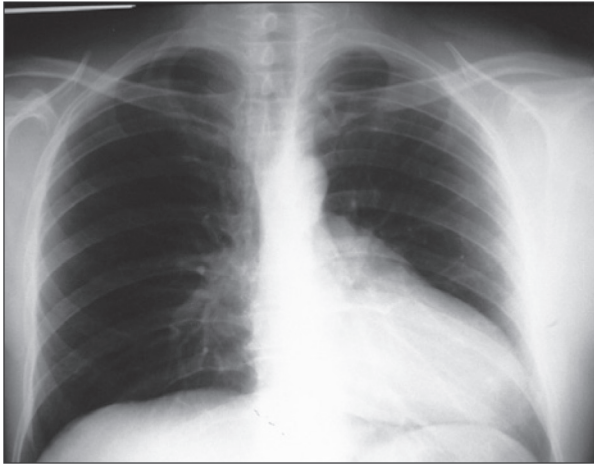


Figure 1 – Chest X-ray: counterclockwise heart axis deviation.

the catheter into the right atrium and the pulmonary trunk was performed with technical difficulty, due to excessive heart displacement to the left. Blood pressure records did not show evidence of pulmonary hypertension or right ventricular outflow gradients. Selective contrast injection in the ventricle with image acquisition at the right anterior oblique view disclosed angiographic characteristics of a morphologically right ventricle with preserved dimensions and contractile functions that were displaced upwards and forward (with concordant connection with the pulmonary trunk). The pulmonary venous return opacified the left atrium, indicating an intact interatrial septum but with an abnormal contour. This abnormal contour was later attributed to the interposition of lung tissue between the atrium and its appendage, which protruded through the pericardial defect.

The retrograde arterial catheterization with blood pressure measurements showed elevated left ventricular filling pressures (135/0/24) without aortic or mitral transvalvular gradients. During catheter advancement, the ventricular outflow tract was observed to have a criss-crossed trajectory (with the aorta to the right), farther from the pulmonary artery. Selective injection of contrast into this ventricle on the left anterior oblique view showed angiographic characteristics of a left ventricle with an intact ventricular septum but with abnormal contractile function: it had shifted backwards and downwards (a concordant direction with that of the aorta (Figures 2 and 3)).

The echocardiography was repeated at the Centro Diagnóstico Cardiovascular (Ribeirão Preto, SP, Brazil) with a diagnostic impression of criss-cross heart, which was not confirmed since cross-flow through the atrio-ventricular valves, structural defects, or cavitory dilation were not observed. However, marked postero-lateral and inferior deviations were observed at the access of the apical four-chamber window, as well as an abnormal

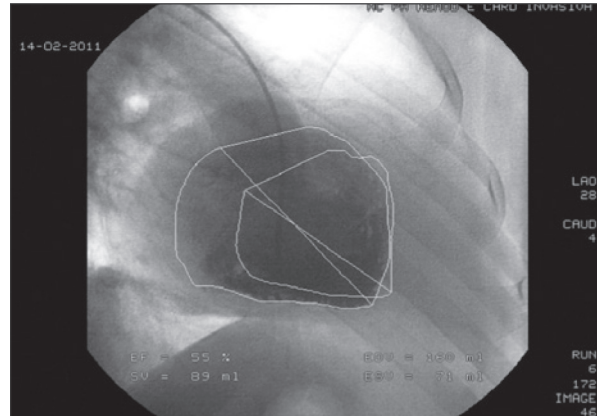


Figure 2 – Left ventriculography: left posterior ventricle displaced downwards and backwards.

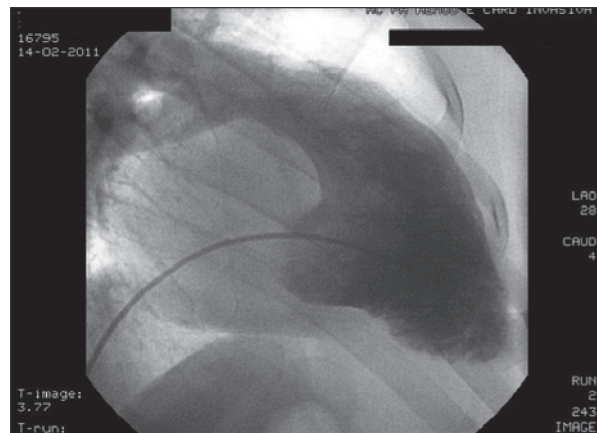


Figure 3 – Right ventriculography: right anterior ventricle displaced upwards and forwards.

interventricular septal motion (paradoxical type A) that was associated with extensive posterior wall motion and was consistent with partial congenital absence of the pericardium as a result of extensive anterior motion of the heart during systole (resulting from the pericardial defect).

A cardiac magnetic resonance imaging (MRI) was also requested and was performed at the Centro Diagnóstico por Imagem (CEDIRP), Ribeirão Preto, SP, Brazil. The cardiac MRI evidenced a counterclockwise heart axis deviation with increased mobility during the cardiac cycle phases, and no identification of the pericardium on the left side of the heart (with the lung parenchyma involving the pulmonary artery trunk). Other findings described in the report included a normal aortic root and ascending aorta, as well as normal calibre and contours of the pulmonary artery trunk, normal systemic and pulmonary venous drainage, cardiac chambers with normal dimensions and wall thicknesses, and preserved

atrioventricular and ventriculoarterial ratios. The dynamic study evidenced the preserved systolic performance of both ventricles with no regional contractile alterations or significant valvular dysfunction (Figure 4).

DISCUSSION

The lateralization of the pulmonary artery to the left with anterior displacement of the right ventricular outflow tract, as well as the displacement of the aorta and marked left ventricular shift backwards and downwards were unexpected findings of the heart catheterization. However, these findings were used as the foundation for the diagnosis of this rare heart malformation.

The inadequate position of the ventricles led to the initial erroneous interpretation that this was a case of superior-inferior ventricles (criss-cross heart) and atrioventricular and ventriculoarterial discordance (bulboventricular loop), since in such a scenario the aorta is situated to the right of the pulmonary artery, and the physiology of congenitally corrected transposition of the great arteries is present.⁶ Thus, the venous catheter trajectory would be from the right atrium to the left ventricle (connected to the pulmonary artery), and the arterial catheter trajectory would reach the right ventricle (connected to the left atrium) with the aorta to the right of the pulmonary artery.

The questions concerning the morphological ventricular pattern, the spatial arrangement of the ventricular septum, the atrioventricular valve position, the non-parallel outflow tract alignment, the coronary circulation pattern, as well as the rarity of the criss-cross heart and its associated severe deficiencies (which were not present in this case) stood as reasons to continue the investigation combined with other cardiovascular imaging methods.^{5,7} Thus, the definitive identification

of the condition was only confirmed using MRI, which demonstrated the partial absence of the pericardium on the left side without the incarceration of heart structures, a finding more frequently associated with the interposition of lung tissue between the aorta and the pulmonary artery, as described in the literature.⁶

Regarding the congenital absence of the pericardium, it is important to emphasize that the complete form is more frequent (70%), and most patients remain asymptomatic. However, the incomplete forms may present symptoms of chest pain or palpitations that are attributed to a loss of cardiac fixation; thus, these forms are potentially lethal due to the herniation of heart chambers with incarceration and torsion (especially the left atrial appendage through the pericardial defect).⁸ Thus, in the complete forms, there is no indication for surgical treatment due to absence of risk, and pericardium repair is reserved for symptomatic cases or for those at risk of incarceration and syncope.^{9,10}

Finally, the importance of a joint evaluation using different cardiovascular imaging methods when performing a systematic assessment of atypical clinical cases is emphasized, so that differential diagnosis can be used to achieve the the best possible therapeutic management.

CONFLICTS OF INTEREST

The authors declare no conflicts of interest.

REFERENCES

1. Rusk RA, Kenny A. Congenital pericardial defect presenting as chest pain. *Heart*. 1999;81(3):327-8.
2. Faridah Y, Julsrud PR. Congenital absence of pericardium revisited. *Int J Cardiovasc Imaging*. 2002;18(1):67-73.
3. Ladd W. Congenital absence of the pericardium. *N Engl J Med*. 1936;214:183.
4. Nasser WK. Congenital diseases of the pericardium. *Cardiovasc Clin*. 1976;7(3):271-86.
5. Payvandi MN, Kerber RE. Echocardiography in congenital and acquired absence of pericardium: an echocardiographic mimic of right ventricular volume overload. *Circulation*. 1976;53(1):86-92.
6. Arazo PA, Reddy GP, Thomson PD, Higgins CB. Images in cardiovascular medicine. Magnetic resonance angiography of criss-cross heart. *Circulation*. 2002;105(4):537-8.
7. Nasser WK, Helmen C, Tavel ME, Feigenbaum H, Fisch C. Congenital absence of the left pericardium: clinical electrocardiographic, radiographic, hemodynamic and angiographic findings in six cases. *Circulation*. 1970;41(3):469-78.
8. Gatzoulis M, Munk MD, Merchant N, Van Arsdell GS, McCrindle BW, Webb GD. Isolated congenital absence of the pericardium: clinical presentation diagnosis and management. *Ann Thorac Surg*. 2000;69(4):1209-15.
9. Saito R, Hotta F. Congenital pericardial defect associated with cardiac incarceration: case report. *Am Heart J*. 1980;100(6 Pt 1):866-70.
10. Scheuermann-Freestone M, Orchard E, Francis J, Petersen M, Friedrich M, Rashid A, et al. Partial congenital absence of the pericardium. *Circulation*. 2007;116(6):e126-9.

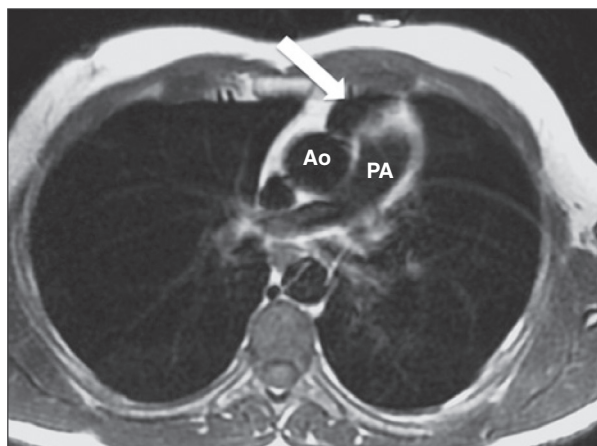


Figure 4 – Chest magnetic resonance imaging showing the interposition of lung tissue between the aorta and pulmonary artery (arrow). Ao, aorta; PA, pulmonary artery.