

# Complications after breast implant use in Poland's syndrome: a case report

## *Complicação pós-implante mamário na síndrome de Poland*

EWALDO BOLÍVAR DE SOUZA  
PINTO<sup>1</sup>

OSVALDO RIBEIRO SALDANHA<sup>2</sup>

ROGÉRIO PORTO DA ROCHA<sup>3</sup>

ALEXANDRE SANFURGO DE  
CARVALHO<sup>4</sup>

PABLO FRIZZERA BELBONI<sup>4</sup>

### ABSTRACT

Poland's syndrome is described as the absence of the pectoralis major muscle associated with deformities of the hands such as variable syndactylia, absence of the middle phalanx, fusion of the carpal bones, or shortening of the forearm. There may be variations in the extent of the thoracic impairment from the absence of anterior portions of ribs or costal cartilages to "sunken chest," which is generally used to describe thoracic depressions associated with skeletal dysplasia. In general, the areolar–papillary complex is in an upper region in men, and women have hypoplastic breasts. A 32-year-old female patient with Poland's syndrome sought our outpatient service wishing to improve the appearance of her thorax and breasts. She had undergone surgical intervention 7 years earlier with implantation of a silicone breast prosthesis, aiming to minimize the characteristic thoracic deformity. After an assessment, we opted to replace the prosthesis. During the intraoperative period, an area of osteocartilaginous resorption about 4 cm in diameter was observed in a region of costochondral articulation. After the surgery, the patient progressed as expected. Extensive research was carried out on the deformity found, and the patient was referred to a thoracic surgeon. Anterior regional bone resorption in the left hemithorax can be an important surgical finding. It can also represent a decrease in cardiac protection, necessitating greater care in cases of breast prosthesis replacement and the requirement of specific imaging examinations such as CT scans in order to minimize surgical risks.

**Keywords:** Breast implantation. Poland syndrome. Thoracic wall/abnormalities. Bone diseases, developmental.

### RESUMO

A síndrome de Poland é descrita como ausência do músculo peitoral maior, associada a deformidade das mãos, como sindactilias variáveis, ausência de falanges médias, fusão dos ossos do carpo ou encurtamento do antebraço. Pode haver variação na extensão do comprometimento torácico, desde o *sunken chest*, termo utilizado para as depressões torácicas associadas a displasia esquelética em geral, até a ausência das porções anteriores das costelas ou cartilagens costais. Em geral, o complexo areolopapilar é posicionado mais superiormente nos homens e nas mulheres a mama é hipoplásica. É relatado o caso de paciente portadora de síndrome de Poland, com 32 anos de idade, que procurou nosso ambulatório de residentes com o desejo de melhorar a aparência do tórax e da mama. Foi realizada intervenção cirúrgica sete anos antes, com implante de prótese mamária de silicone, no intuito de amenizar a deformidade torácica característica. Após avaliação, optou-se pela troca da prótese. No intraoperatório, observou-se área de reabsorção osteocartilaginosa com cerca de 4 cm de diâmetro, em região de articulação costochondral. Após a cirurgia, a paciente evoluiu conforme o esperado. Foi realizada investigação ampla da deformidade encontrada e a paciente avaliada foi encaminhada ao cirurgião torácico. A reabsorção óssea regional anterior no hemitórax esquerdo pode ser um achado cirúrgico e representar diminuição da proteção cardíaca, tornando necessária maior atenção para os casos de substituição de prótese mamária, com realização de exame de imagem específico, como tomografia computadorizada, com o objetivo de minimizar o risco cirúrgico.

**Descritores:** Implante mamário. Síndrome de Poland. Parede torácica/anormalidades. Doenças do desenvolvimento ósseo.

Study conducted in the Plastic Surgery Service "Prof. Dr. Ewaldo Bolívar de Souza Pinto" of Universidade Santa Cecília (Unisantá) – Santos, SP, Brazil.

Submitted to SGP (Sistema de Gestão de Publicações/Manager Publications System) of RBCP (Revista Brasileira de Cirurgia Plástica/Brazilian Journal of Plastic Surgery).

Paper received: February 10, 2010

Paper accepted: April 6, 2011

1. Professor Doctor in Plastic Surgery, Full member of the Brazilian Society of Plastic Surgery (SBCP), Director of the Specialization Course in Plastic Surgery of Universidade Santa Cecília (Unisantá), Founder and President of the Center of Studies in Plastic Surgery Prof. Antonio Prudente, Head of the Medical Residency Service in Plastic Surgery of Unisantá, Santos, SP, Brazil.
2. Full member of SBCP, Head of the Specialization Service in Plastic Surgery of Unisantá, Santos, SP, Brazil.
3. Professor Doctor in Plastic Surgery, Full member of SBCP, Professor of Anatomy at Centro Universitário Lusíada – UNILUS, Physician at the Specialization Service in Plastic Surgery of Unisantá, Santos, SP, Brazil.
4. Resident physician in Plastic Surgery of the Plastic Surgery Service "Prof. Dr. Ewaldo Bolívar de Souza Pinto" of Unisantá, Santos, SP, Brazil.

## INTRODUCTION

Congenital deformities or deformities impairing thoracic development rarely cause severe functional problems, unlike other severe anomalies affecting limbs. They are also aesthetically more tolerable and concealable than larger facial fissures<sup>1-4</sup>.

Poland<sup>5</sup> was the first to describe an anomaly involving the absence of the pectoralis major muscle associated with hand deformities, which was later described by Froriep<sup>6</sup>. Recently, the studies of Ravitch<sup>7</sup> resolved many issues regarding the diagnosis and treatment of such anomalies.

Poland's syndrome comprises a variety of anomalies specifically affecting the trunk and upper limbs. It is more common in men than in women and is rarely bilateral. The absence of the sternal portion of the pectoralis major muscle is considered to be the mildest manifestation of this syndrome. Impairment of other adjacent muscles (i.e., the pectoralis minor, serratus anterior, latissimus dorsi, and external oblique) has been reported in the literature<sup>4</sup>.

Skeletal deformities may include "sunken chest," which is generally used to describe thoracic depressions associated with skeletal dysplasia, as well as the absence of anterior portions of the ribs or costal cartilage<sup>8</sup>. In severe cases, there may be significant paradoxical movement of the thorax and anterior herniation of the lungs. The scapulae may be smaller and winged (Sprengel's deformity). The skin in this region is hypoplastic, and the subcutaneous mesh is flatter. In general, the areolar-papillary complex is in an upper region in men, while women have hypoplastic breasts. Hand deformities may include variable syndactylia, absence of phalanges, carpal bone fusion, or forearm shortening<sup>4</sup>.

Studies demonstrate a low incidence of Poland's syndrome (1:30,000) in Brazil; it is believed that this syndrome is genetically influenced and is related to chromosomal anomalies<sup>4</sup>.

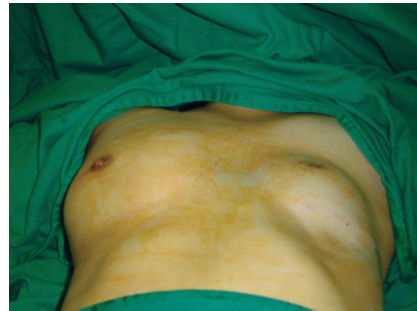## CASE REPORT

A 32-year-old Caucasian female patient visited Prof. Dr. Ewaldo Bolívar de Souza Pinto, Outpatient Service of Plastic Surgery, with history of Poland's syndrome on the left side, absence of the pectoralis major muscle, and depression in the left anterior thoracic wall resulting in "sunken chest" (Figure 1). After clinical examination, the subcutaneous mesh in the affected region and the areolar-papillary complex were found to be hypoplastic, while the left side was in an upper position relative to the right. The left upper limb exhibited normal development, and the patient did not have any systemic diseases.

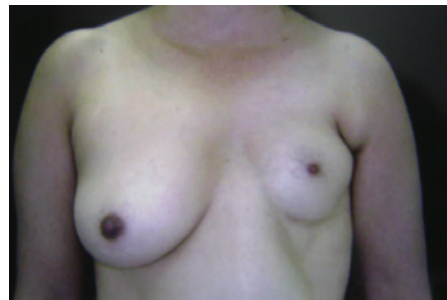The patient underwent a surgical procedure for implantation of a left breast prosthesis 7 years earlier in an attempt to correct or minimize the thoracic deformity. She sought our

service to replace the breast prosthesis as she was unhappy with its shape (Figure 2).

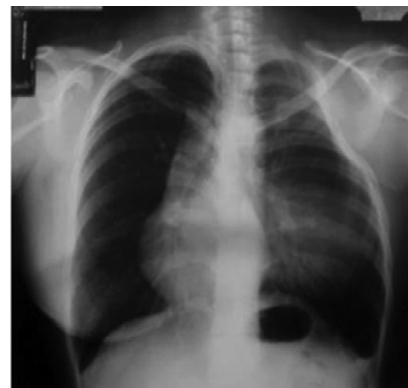Routine preoperative examinations were performed. After analyzing the chest X-ray in the posterior-anterior view, the existence of an upper bone depression at the left side was observed, with the mediastinum deviating to the right (Figure 3). A circular radiopaque image was observed in the middle third of the left hemithorax, which is compatible with



**Figure 1** – Asymmetry caused by sunken chest in Poland's syndrome.



**Figure 2** – Preoperative period.



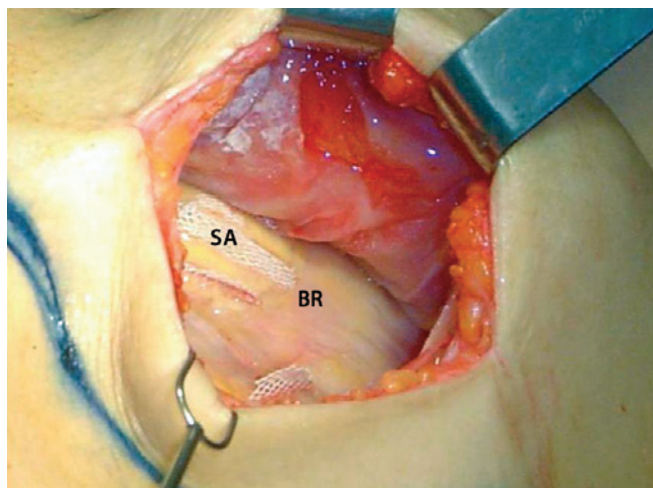
**Figure 3** – Chest X-ray revealing a costal deformity on the left and deviation of the mediastinum to the right. A circular radiopaque image on the left side indicating the presence of the breast prosthesis.

the breast prosthesis. After the preanesthetic visit, the patient underwent breast prosthesis replacement under general anesthesia of basal flow.

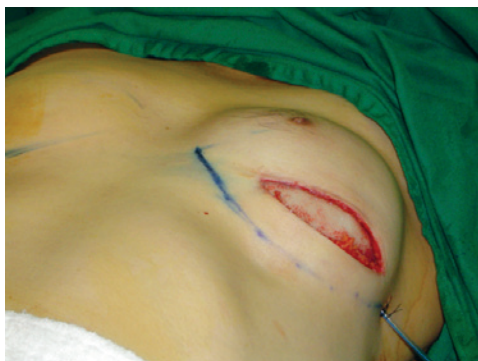The incision was made over the scar in the submammary crease to the left side to access the prosthetic cavity. After the prosthesis was removed, osteocartilaginous resorption (about 4 cm in diameter) was observed in the region of costochondral articulation (Figure 4).

Partial capsulectomy was performed, and a new round high-profile mammary prosthesis with a polyurethane surface was placed (235 mL) (Figure 5) with vacuum drainage of the prosthesis cavity for 72 hours.

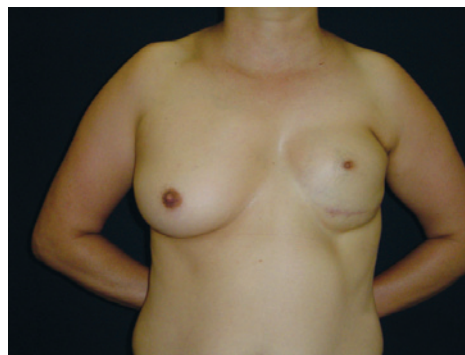The patient was discharged on the first postoperative day and exhibited good progress. On the 30<sup>th</sup> postoperative day, she was sent to the thoracic surgeon who requested a CT scan for assessment and follow-up (Figure 6).



**Figure 4** – The cavity after removal of the breast prosthesis. At the center, an area of bone resorption (about 4 cm in diameter) can be observed. SA = silicone adhesive; BR = bone resorption.



**Figure 5** – Placement of the new prosthesis with a polyurethane surface with vacuum drainage of the cavity.



**Figure 6** – One-year postoperative period.

## DISCUSSION

Surgical correction of congenital deformities or deformities impairing thoracic development can be important in the prevention of progressive scoliosis, cardiopulmonary restriction, and adverse psychological development.

The literature does not contain cases of total or regional secondary resorption in the presence of breast prostheses. However, it is known that the compression results in bone absorption and subsequent bone remodeling.

During prosthesis removal, 3 circular silicone devices used for prosthetic fastening in the thoracic wall were observed within the cavity (Figure 3). This observation led the authors to believe that anterior regional bone resorption did not occur after the first surgery since such devices are normally positioned over the rigid surface.

Anterior regional bone resorption in the left hemithorax was an important surgical finding; considering the possibility of decreased cardiac protection, we decided to replace the prosthesis with another prosthesis that was greater in volume to occlude the observed defect. The patient was sent to the thoracic surgeon for follow-up and planning of corrective surgery.

Although the literature does not contain information regarding bone resorption as result of breast prosthesis implantation in Poland's syndrome, we believe that greater attention is necessary in cases involving breast prosthesis replacement and specific imaging examinations such as CT scans should be performed.

## REFERENCES

1. Hodgkinson DJ. The management of anterior chest wall deformity in patients presenting for breast augmentation. *Plast Reconstr Surg.* 2002;109(5):1714-23.
2. Longaker MT, Glat PM, Colen LB, Siebert JW. Reconstruction of breast asymmetry in Poland's chest-wall deformity using microvascular free flaps. *Plast Reconstr Surg.* 1997;99(2):429-36.
3. Sadove AM, van Aalst JA. Congenital and acquired pediatric breast

- anomalies: a review of 20 years' experience. *Plast Reconstr Surg.* 2005; 115(4):1039-50.
4. Shaw WW, Aston SJ, Zire BM. Reconstrucción del tronco. In: *Cirugía plástica: tronco y extremidades inferiores*. Vol. 6. Buenos Aires: Panamericana; 1990. p. 1-116.
  5. Poland A. A deficiency of the pectoral muscles. *Guy's Hospital Report.* 1841;VI:191.
  6. Froriep R. Beobachtung eines felles von mangel der brustaruse. *Notizen aus dem Bebiere der Naturund Heilkunde.* 1939;10(1):9.
  7. Ravitch MM. Poland's syndrome: a study of an eponym. *Plast Reconstr Surg.* 1977;59(4):508-12.
  8. Spear SL, Pelletiere CV, Lee ES, Grotting JC. Anterior thoracic hypoplasia: a separate entity from Poland syndrome. *Plast Reconstr Surg.* 2004;113(1):69-77.

---

**Correspondence to:**

Rogério Porto da Rocha  
Av. Ana Costa, 120 – Vila Mathias – Santos, SP, Brazil – CEP 11060-000  
E-mail: rogerio@portodarocha.com