



Beard transplantation

Transplante de barba

CARLOS EDUARDO GUIMARÃES
LEÃO^{1,2*}

Institution: Clinica Leão, Belo Horizonte, MG, Brazil. Hospital Premier, Belo Horizonte, MG, Brazil.

Article received: November 15, 2016.
Article accepted: July 9, 2017.

Conflicts of interest: none.

DOI: 10.5935/2177-1235.2017RBCP0053

■ ABSTRACT

Introduction: Beard transplantation is a surgical procedure that has been increasingly performed in the last 10 years, concurrently with the considerable technical progress of hair restoration. This is a prevalent phenomenon in plastic surgery worldwide and a great option for patients naturally beardless or with patchy beards and to hide unsightly facial scars in beard areas. **Methods:** Some diseases, including alopecia areata, dermatophytosis, folliculitis, dermatitis, and emotional stress, may progress with loss of beard hair and should be clinically treated. Therefore, etiological evaluation and differential diagnosis are fundamental in the surgical indication for beard failure due to genetic problems or scars in the beard, mustache, and goatee areas. **Results:** A good beard surgery outcome requires correct diagnosis and adequate planning for each case, refined and careful surgical technique, and perfect physician-patient relationship because facial changes are striking. **Conclusion:** This is a surgery for any individual seeking one of the most striking male esthetic attributes of all time: the beard. This surgery is an actualized aspiration for naturally beardless patients and patients with patchy beards or unsightly facial scars in beard areas and will positively affect their self-esteem, ultimately improving all aspects of their lives.

Keywords: Autologous transplantation; Transplants; Beard products.

¹ Sociedade Brasileira de Cirurgia Plástica, São Paulo, SP, Brazil.

² Fundação Hospital do Estado de Minas Gerais, Belo Horizonte, MG, Brazil.

■ RESUMO

Introdução: O transplante de barba é um procedimento cirúrgico que cresceu significativamente nos últimos 10 anos e coincide com a grande evolução técnica da restauração capilar neste mesmo período. Trata-se de um fenômeno de forte tendência na cirurgia plástica mundial e se apresenta como grande opção para os geneticamente imberbes, barbas falhadas e para camuflar cicatrizes inestéticas da face em regiões de barba. **Métodos:** Algumas doenças como alopecia areata, tinha, foliculite, dermatite e estresse emocional podem cursar com perda de fios de barba e devem ser tratados clinicamente. Portanto, a etiologia e o diagnóstico diferencial são fundamentais na indicação cirúrgica das falhas da barba, seja por problemas genéticos ou por cicatrizes na região de barba, bigode e cavanhaque. **Resultados:** Os bons resultados em cirurgia da barba dependem do correto diagnóstico, do planejamento adequado para cada caso, de técnica cirúrgica refinada e cuidadosa e do perfeito relacionamento médico-paciente, já que as mudanças na fisionomia são marcantes. **Conclusão:** Trata-se de uma cirurgia para todos aqueles que desejam ter um dos mais marcantes atributos estéticos do homem desde sempre, a barba. Pacientes imberbes, com barbas falhadas ou com cicatrizes inestéticas da face em regiões de barba encontram nessa cirurgia a realização de um sonho que influenciará positivamente na sua autoestima, melhorando, em última análise, sua vida em todos os âmbitos da convivência.

Descritores: Transplante autólogo; Transplantes; Produtos para barba.

INTRODUCTION

The beard is a key esthetic attribute of male identity. Its history and culture date back to ancient civilizations and remain unscathed in contemporary men. Opinions regarding its appearance have always varied worldwide, depending on the habits, beliefs, and cultural aspects of individual personality development.

Some civilizations saw unequivocal signs of wisdom, social status, and sexual power in their bearded men. Conversely, other individuals saw signs of sloppiness, eccentricity, and lack of personal hygiene, refinement, and upbringing in bearded men.

To date, the beard culture in specific religions is a sign of respectability and remains important for preserving belief and devotion and spreading faith.

The demand for laser epilation of unwanted beard hair has grown in recent years among beardless enthusiasts, albeit without comparison with the opposite. The XXI century man wants to have a beard or to fix his patchy beard. This is a worldwide cultural phenomenon perceiving the “unshaven look” from 4 to 5 days without shaving as the contemporary standard of male beauty adopted by international film, sports, and showbiz celebrities.

A fad is not and will never be an indication for any surgery, even imminently esthetic procedures. However, the desire to have a beard or fix a patchy beard is legitimate, and given the extraordinary technical evolution of hair restoration in the most diverse body segments, the use of this surgical procedure has increased. In recent studies conducted at the University of Southern Queensland in Australia, 55% of men worldwide have a beard, mustache, or both, and these covered areas are one-third less exposed to solar radiation.

OBJECTIVE

The present study aimed to show the current importance of and great progress in hair restoration techniques and approaches, especially facial hair restoration, unprecedentedly increasing the importance of beard transplantation among plastic surgery procedures worldwide.

METHODS

The indication for beard transplantation involves a careful etiological evaluation and differential diagnosis.

The loss of beard hair caused by extreme stress commonly occurs in the daily life trials and tribulations of modern men.

The most common diseases, including seborrheic dermatitis of the face, folliculitis of various causes, alopecia areata, and dermatophytosis, progress with circumscribed or diffuse hair loss, causing an unsightly patchy beard¹⁻³.

Hormonal dysfunctions, dietary deficiencies, or poorly planned diets, which are recently very common, in addition to the use of anabolic and other drugs with similar effects, may also lead to the loss of beard hair, causing patchy and thin beards.

Therefore, a successful treatment depends on a correct diagnosis. Genetic problems are indeed the main indication for surgical restoration of the beard. Facial scars, depending on the quality and location, may be hidden via Follicular Unit Transplantation (FUT), disguising the esthetic and social problems they cause.

In this case series, the age of the subjects ranged from 23 to 64 years. Beardless patients accounted for 60% of the cases. Further, 30% of the patients complained of a patchy beard, and 10% sought the surgery to hide scars, mostly from a cleft lip.

Planning is crucial for surgical success. The mapping of the beard into different facial segments, always including the mustache and goatee, shows that the direction of the beard hair growth is individual (Figure 1). However, there is a pattern repeated in a significant part of the sample (Figure 2), which tremendously facilitates planning and drawing of the new beard in beardless patients during the consultation (Figure 3).

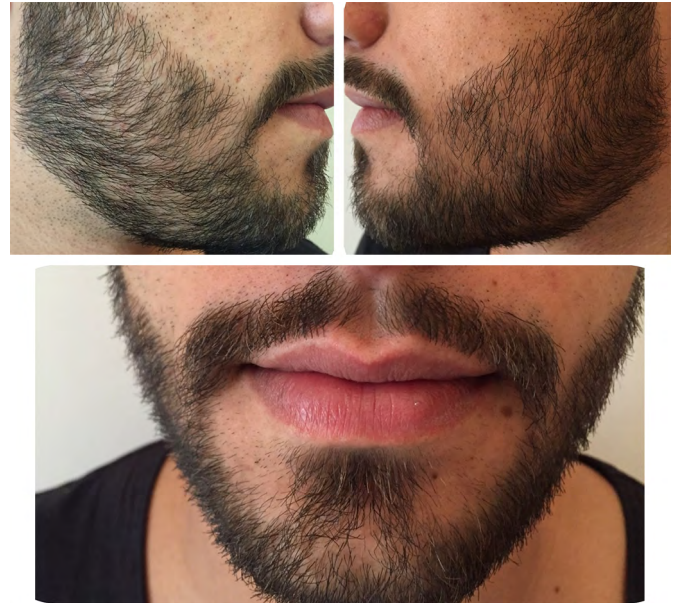

Figure 2. Most common pattern of beard hair direction.

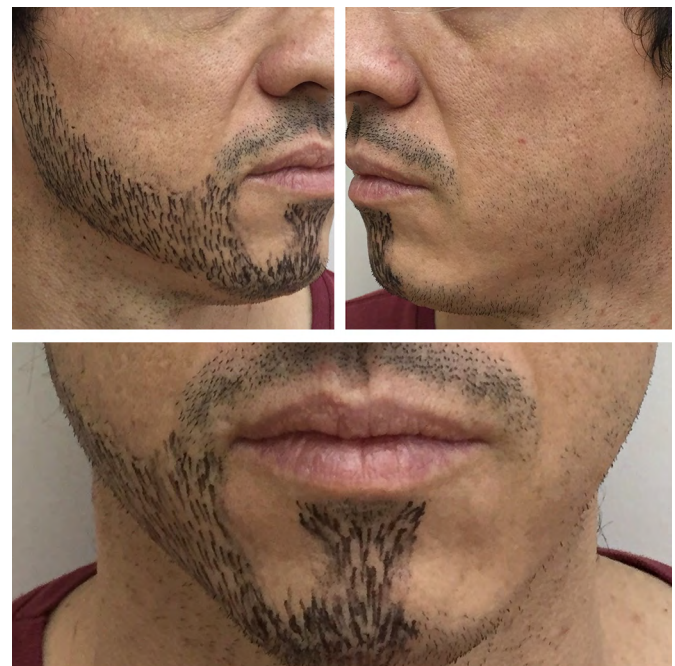

Figure 3. Preview of the new beard in a beardless patient during a consultation.

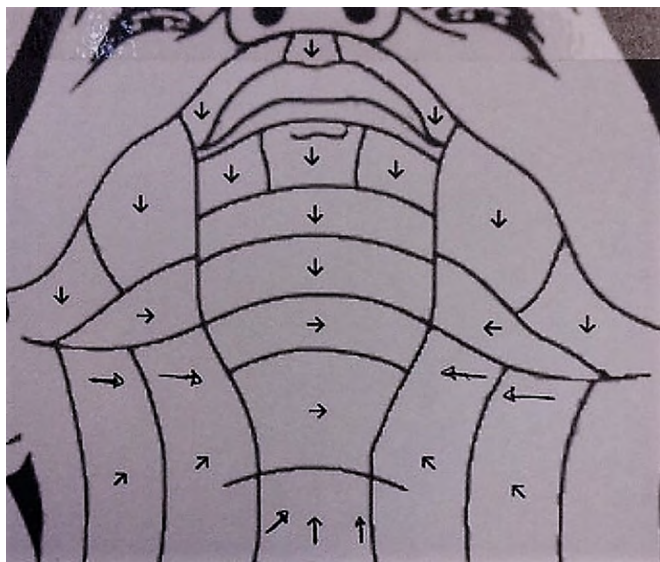


Figure 1. Individual map of the direction of beard hair growth.

In most cases, patients select the traditional pattern, which is more outlined and in which the neck line is more angled and slightly outside the jaw line, with a maximum width of 6 cm until the genic area, making both this segment and the neck hairless. The cheek line, which is in a slightly bent curve, ends at the height of the labial commissure, herein joining the side of the mustache to the goatee.

Patients commonly ask for an inverted triangle shape of the beard connecting the lower lip to the goatee (Figure 4). A few sparse hairs, scattered in the genic area above the marking line, provide a natural appearance and may be scraped off if necessary. In patients with a patchy beard, it is particularly important to follow the marking lines and the direction of the original hair, which would facilitate preoperative understanding (Figure 5).

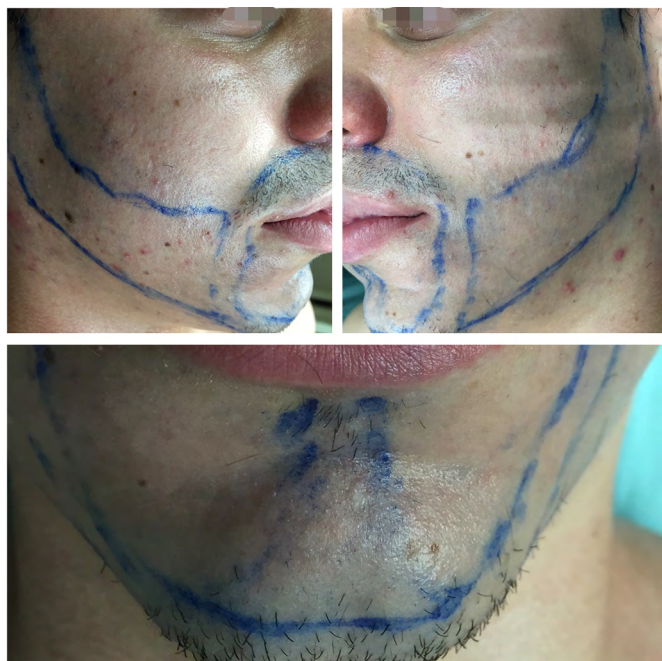

Figure 4. Preview of the new beard lines in a beardless patient.

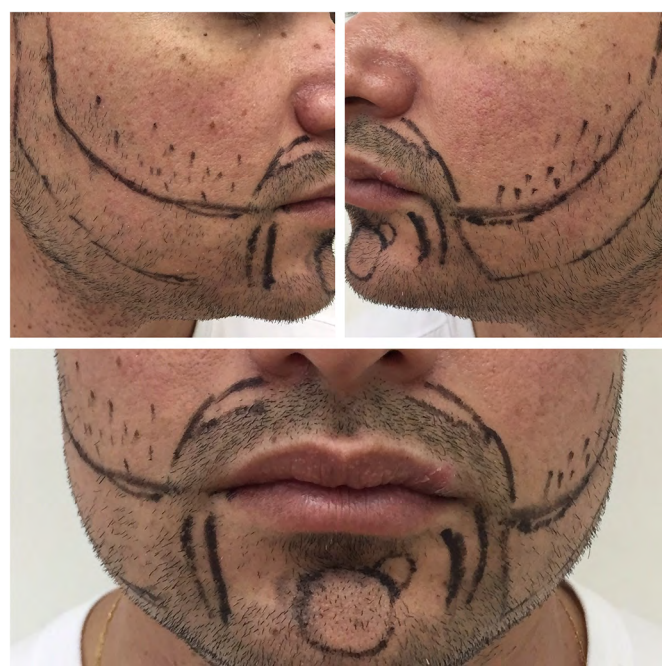

Figure 5. Preview of beard transplantation in a patient with a patchy beard.

Routine preoperative examinations are necessary. Well-equipped clinics or hospitals and anesthesiologist-assisted local anesthesia induction with sedation are preferred by the author, mainly because this surgery is a long, thorough, and highly laborious surgical procedure, requiring a trained and technically well-prepared team and a suitable surgical arsenal for the success of the procedure.

Both FUT (a scalp strip is harvested from the temporo-occipital region, thereby leaving a thin linear scar) and Follicular Unit Extraction (FUE; numerous holes are created in the same area by micropunches, resulting in the same number of small scars, i.e., the so-called white dots) may be used as methods of obtaining follicular unit (FUs) for beard restoration (Figure 6).

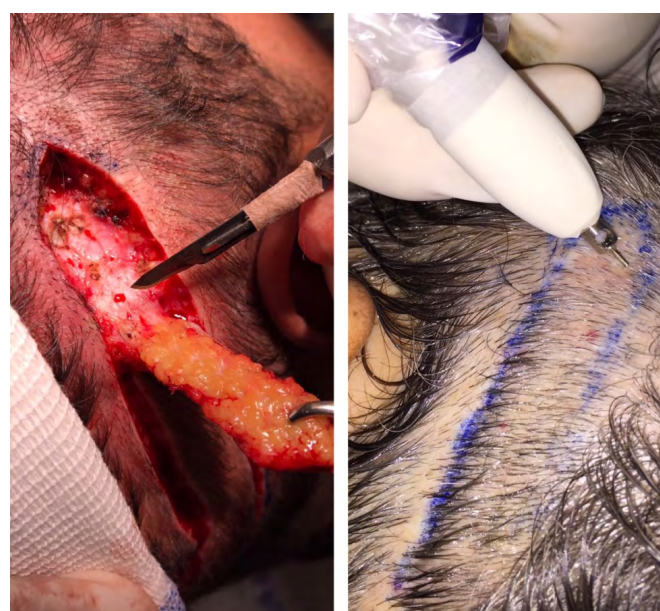

Figure 6. Methods of harvesting follicular units: on the left, Follicular Unit Transplantation; on the right, Follicular Unit Extraction.

The method of choice is individualized and has no effect on the final surgical outcome. FUT is preferred by the author mainly because this technique is performed faster than FUE, which greatly decreases the surgical time of a procedure that is already very long, specifically in this surgery.

In small patches of thin beards or unsightly facial scars, neck beard, when present, may be used as a donor area in a decision shared with the patient. In this case, FUE is the method of choice for harvesting roots, including the author's (Figure 7)⁴⁻⁷.

FUs should have one to two roots with longer hairs at least 1-cm-long (Figure 8). Particularly in beard transplantation, long hairs are crucial for the correct direction and angle of the grafts in relation to the facial skin and should have a slope of 20° (Figure 9).

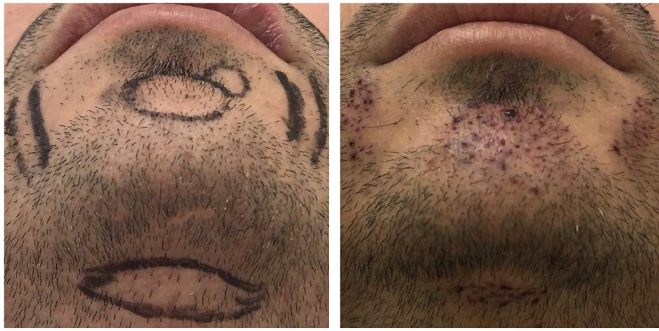

Figure 7. Follicular Unit Extraction for the correction of small patches of a thinning beard with follicular units harvested from the cervical region.

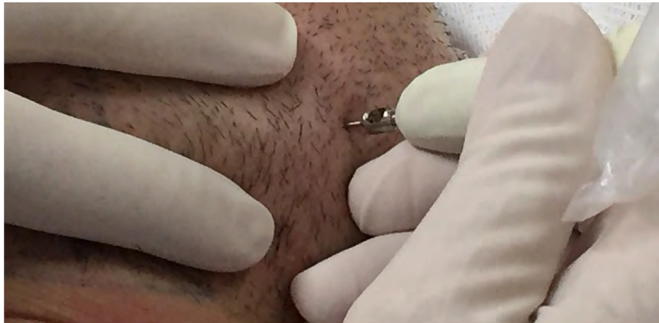

Figure 8. Follicular units containing one to two 1-cm-long roots.

Pogonology (study of beards) predicts that a normal man has 20,000 to 25,000 hairs in a full beard, including the mustache, goatee, and neck area. The acceptable cosmetic density for a good hair restoration in beardless patients approximately ranges from 8,000 to 10,000 hairs, with an estimated average ranging from 25 to 30 FUs per cm^2 , although the neck area is rarely included in the surgical planning as an area for transplantation^{9,10}.

The ergonomics, comfort, and position of the patient and the surgeon are key variables in the progress of the surgery. The work of the first assistant, which is to maintain the facial skin stretched throughout the surgical procedure, enables a more efficient dynamics for correct graft positioning, facilitating precise maneuvers of the surgeon required for beard transplantation surgery, which lasts for at least 6 hours when performed by an expert.

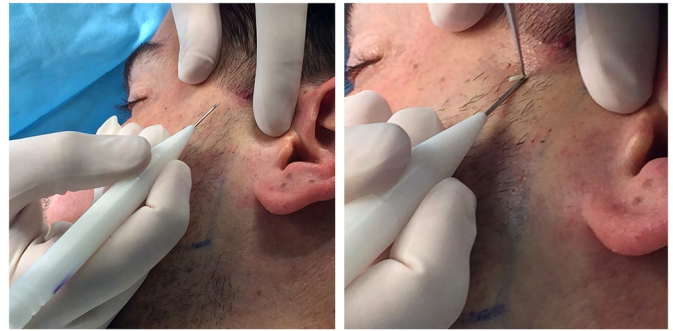
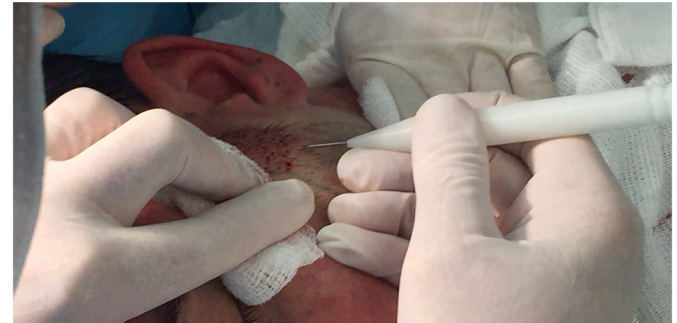
Figure 9. Correct inclination of the needle in relation to the skin. Perfect introduction of the follicular unit observing the hair angle and direction. Competent work of the assistant in pulling the skin.



For grafting, the author prefers the stick-and-place technique (sequentially piercing and grafting) using the Lion Scalpel, which was optimized by the author, for grafting maneuvers. Previous incisions and subsequent grafting may also be used, as well as implanters, which simultaneously pierce and insert the grafts in one stroke (Figure 10). In both instruments, needles with diameters ranging from 0.8 to 0.9 mm are preferred.

The immediate, postoperative period is simple and does not prevent patients from performing their main daily activities. Facial transplant hairs follow the same progression as those intended for treating baldness and fall during the first 30 postoperative days, reappearing approximately 2 months after falling. Discrete ecchymosis and edema (Figure 11) and sparse folliculitis and pruritus are common and easily resolved complaints. The use of shavers, either manual or electric, is allowed as soon as definitive hairs appear.

RESULTS

The new beard should be outlined in agreement with the patient in front of a mirror before entering the Surgical Block, while repeating every concern discussed combined with that in the first consultation. The patient should feel confident about everything planned because the upcoming change will be dramatic.

The beard transplantation outcome depends on some factors, mostly inherent to the patient. Curly and

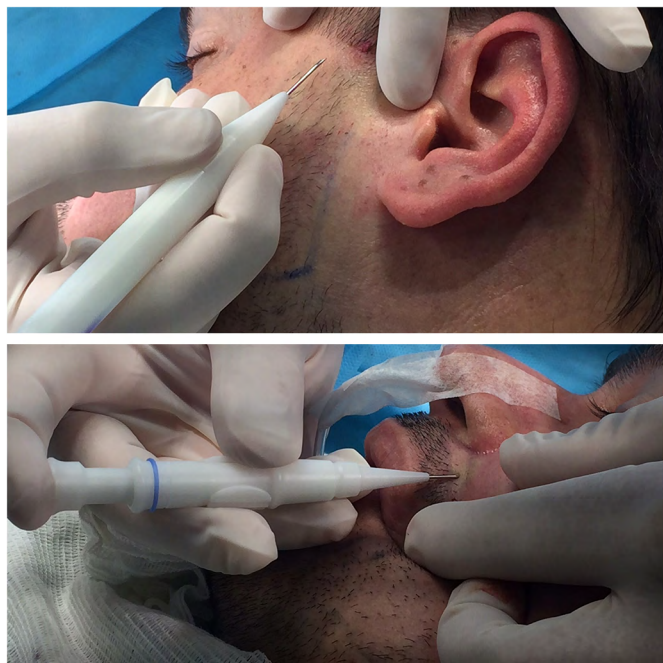

Figure 10. Above, Lion scalpel coupled to a 30 × 0.8-mm needle. Below, Implanter coupled to a 0.8-mm needle.

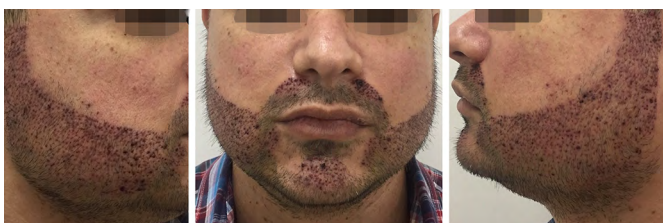

Figure 11. Appearance 24 hours after surgery. Discrete ecchymosis and edema.

black hairs are more difficult to prepare and cosmetically less interesting than hairs with smooth and straight roots.

The cosmetic density achieved with grafting (approximately 25 to 30 FUs per cm²), which pleases the absolute majority of transplanted patients, may be questioned by some patients for failing to meet their expectations. Therefore, the transplantation of new grafts is not ruled out, thereby enabling doubling of the number of roots obtained in the first step. This possibility should always be suggested in the first interview.

The need for detailed information on the surgical outcome in patients with a patchy beard is emphasized. Although the results are always satisfactory, the transplanted hairs are not identical to the original hairs. Such a care avoids questions from more detailed-oriented and demanding patients (Figures 12 to 14).

DISCUSSION

The changes promoted by beard transplantation in beardless patients should be thoroughly discussed with them. Although patients return to their previous physi-

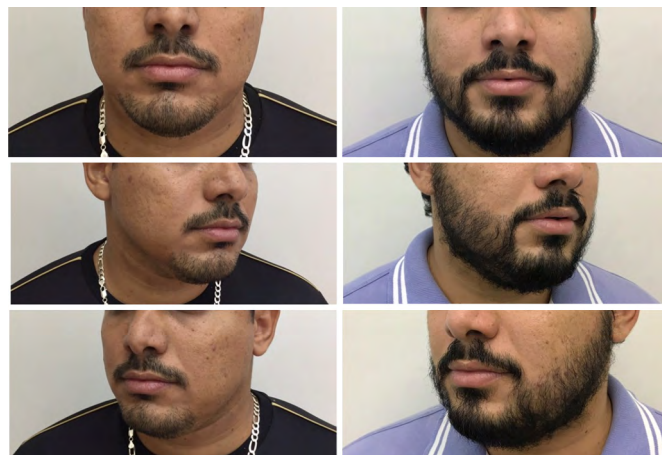

Figure 12. Pre- and post-operative photographs with 11 months of progression.

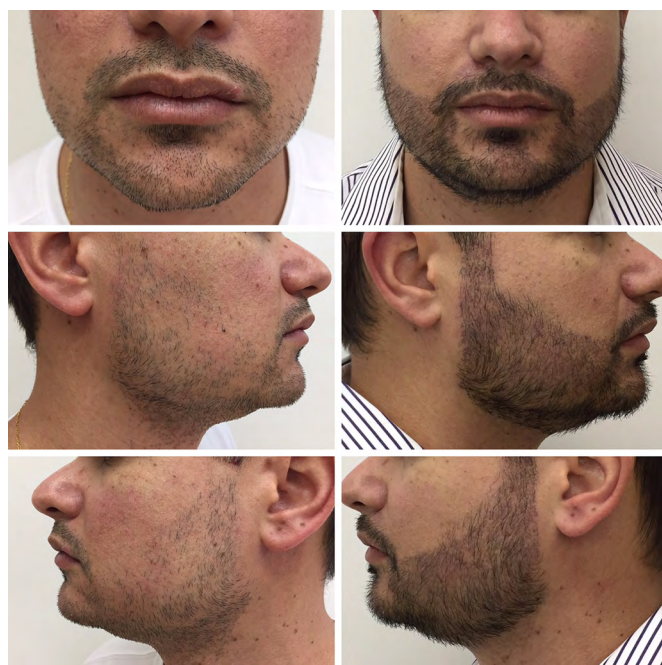

Figure 13. Pre- and post-operative photographs with 8 months of progression.

cal appearance when shaving, the beard becomes part of their new lives and may indelibly affect their personalities. Very young patients should be carefully followed up by the surgeon, and more than one interview is necessary for the correct surgical decision and should be shared with parents and guardians if possible.

Patients with a family history of baldness should be warned about the need for a donor area to treat this condition. Beard surgery, which uses the same donor region, will certainly decrease the likelihood of more surgical steps for either problem. The decision on either or even both surgeries belongs exclusively to the patient.

The psychological benefits reflected in the increased self-esteem, reassurance of masculinity, security

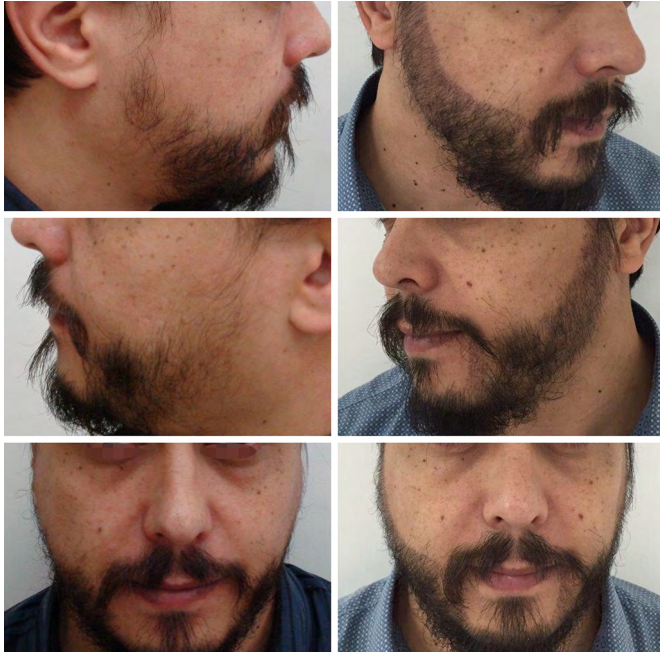

Figure 14. Pre- and post-operative photographs with 8 months of progression.

of interpersonal relationships, and above all, the satisfaction of the new appearance, encourage plastic surgeons specialized in hair restoration to improve the beard transplantation technique, which is exponentially and increasingly used worldwide.

CONCLUSION

Currently, beard transplantation is a reality and a great option for any individual seeking one of the most striking male esthetic attributes of all time. This surgery is an actualized aspiration for naturally beardless patients, patients with patchy beards, or even patients seeking to hide unsightly facial scars in beard areas and will

definitely and positively affect their self-esteem, ultimately improving all aspects of their lives.

COLLABORATIONS

CEGL Analysis and/or interpretation of data; statistical analyses; final approval of the manuscript; conception and design of the study; completion of surgeries and/or experiments; writing the manuscript or critical review of its contents.

REFERENCES

1. Cestari SCP, Azulay DR, Azulay RD. Eczemas e Dermatites Afins. In: Azulay RD, Azulay DR. *Dermatologia*. 4^a ed. Rio de Janeiro: Guanabara Koogan; 2006. p. 162-5. DOI: <http://dx.doi.org/10.1590/S0365-05962006000500015>
2. Sampaio SAP, Rivitti EA. Erupções Eritemato-Escamosas. In: Sampaio SAP, Rivitti EA, eds. *Dermatologia*. 3^a ed. São Paulo: Artes Médicas; 2007. p. 227-31.
3. Seckin D, Gurbuz O, Akin O. Metronidazole 0.75% gel vs. ketoconazole 2% cream in the treatment of facial seborrheic dermatitis: a randomized, double-blind study. *J Eur Acad Dermatol Venereol*. 2007;21(3):345-50. DOI: <http://dx.doi.org/10.1111/j.1468-3083.2006.01927.x>
4. Rassman WR, Bernstein RM, McClellan R, Jones R, Worton E, Uyttendaele H. Follicular unit extraction: minimally invasive surgery for hair transplantation. *Dermatol Surg*. 2002;28(2):720-8. DOI: <http://dx.doi.org/10.1097/00042728-200208000-00014>
5. Norwood OT, Sffiell RC. *Hair transplant surgery*. 2nd ed. Springfield: Charles C. Thomas; 1984.
6. Leão CEG, Miranda ES, Rodrigues FHC. Conduta Pessoal em Cirurgia da Calvície. *Rev Bras Cir Plast*. 2008;23(1):61-6.
7. Leão CEG. Cirurgia da Calvície. In: Carreirão S, ed. *Cirurgia Plástica*. Cap. 88. São Paulo: Atheneu; 2011. p. 1009-21.
8. Pitchon M. Preview long-hair follicular unit transplantation: An immediate temporary vision of the best possible final result. *Hair Transplant Forum Int*. 2006;16(4):113, 118-9.
9. Cooley JE, Vogel JE. Follicle Trauma and the Role of the Dissecting Microscope in Hair Transplantation – A Multicenter Study. *Semin Cutan Med Surg*. 2002;21(2):153-8. DOI: <http://dx.doi.org/10.1053/sder.2002.33284>
10. Uebel CO. Micrografts and minigrafts: A new approach for baldness surgery. *Ann Plast Surg*. 1991;27(5):476-87. PMID: 1746866 DOI: <http://dx.doi.org/10.1097/0000637-199111000-00009>

*Corresponding author:

Carlos Eduardo Guimarães Leão

Rua Ceará, 1986, 10^o andar - Belo Horizonte, MG, Brazil

Zip Code 30150-311

E-mail: leao@leao.med.br