



Cutaneous traction as a complement to the parascapular flap in major cancer loss: case report

Tração cutânea como complemento ao retalho paraescapular em grande perda oncológica: relato de caso

MARCELO ROSSETO^{1,2}
LUANA GRAZIELA BATISTA¹
FRANCO SILVA MARTINEZ^{2,3*}
BLANCA SILVA MARTINEZ³
CAROLINA MARIA STARTARI
SACCO⁴
LETÍCIA SUEMI ARAKAKI²
MICAEL VIANA AZEVEDO²
LUIZ FERNANDO ALVES DE
OLIVEIRA²

■ ABSTRACT

Introduction: Squamous cell carcinoma (SCC) is a malignant epidermal keratinocyte tumor closely related to sun exposure. When diagnosed, through biopsy, its staging, tumor resection with oncological safety margins must be performed, and lymph node dissection and treatment of metastases, if present, may be performed. **Case Report:** Skin traction is reported as a complement to the parascapular flap, used reconstructively after the excision of a large SCC in the left shoulder. **Conclusion:** The technique used proved effective for the satisfactory correction of large dehiscence in the postoperative period of the parascapular flap, promoting partial closure of the defect, reduced time to perform, and correction of the residual defect in a single step.

Keywords: Surgical flaps; Skin neoplasms; Carcinoma, squamous cell; Reconstructive surgical procedures; Surgery, plastic.

■ RESUMO

Introdução: O carcinoma espinocelular (CEC) é um tumor maligno dos queratinócitos epidérmicos e está intimamente relacionado à exposição solar. Quando diagnosticado, por meio de biópsia, deve ser realizado seu estadiamento, ressecção tumoral com margens de segurança oncológica, podendo ser feito esvaziamento ganglionar e tratamento de metástases, caso presentes. **Relato de Caso:** Reporta-se a utilização da tração cutânea como complemento ao retalho paraescapular, utilizado reconstrutivamente pós excisão de CEC de grande dimensão em ombro esquerdo. **Conclusão:** A técnica utilizada mostrou-se eficaz para correção satisfatória de grandes deiscências em pós-operatório de retalho paraescapular, promovendo fechamento parcial do defeito, tempo reduzido para realização e correção do defeito residual em tempo único.

Descritores: Retalhos cirúrgicos; Neoplasias cutâneas; Carcinoma espinocelular; Procedimentos cirúrgicos reconstrutivos; Cirurgia plástica

Institution: Hospital do Câncer de Campo Grande Alfredo Abrão, Campo Grande, MS, Brazil.

Article received: November 19, 2022.
Article accepted: June 13, 2023.

Conflicts of interest: none.

DOI: 10.5935/2177-1235.2023RBCP0768-EN

INTRODUCTION

Squamous cell carcinoma (SCC) is a malignant tumor of epidermal keratinocytes that invades the dermis and can generate metastases. It has a higher incidence in individuals over 50 years old, with the main etiologies being: sun exposure and carcinogenic agents¹.

The most affected sites are the scalp, back of the hands, lower lip, ears, face, buccal mucosa, and external genitalia¹.

The clinical characteristics of the lesion range from erythematous papules or plaques with a scaly or crusted surface to hyperkeratous nodules, often with a verrucous appearance¹.

¹ Hospital de Câncer de Campo Grande Alfredo Abrão, Campo Grande, MS, Brazil.

² Universidade Federal de Mato Grosso do Sul, Campo Grande, MS, Brazil.

³ Associação Beneficente Santa Casa de Campo Grande, Campo Grande, MS, Brazil.

⁴ Universidade Estadual de Mato Grosso do Sul, Campo Grande, MS, Brazil.

A biopsy confirms the diagnosis, and the staging is performed according to the TNM table. In addition to tumor resection, lymph node dissection and treatment of metastases may occur, if necessary².

This study aims to describe the suture by Góes et al.³ as a complement to the parascapular flap⁴, used reconstructively after the excision of SCC.

CASE REPORT

The patient, 50 years old male, white civil construction assistant, sought care due to an ulcerated lesion measuring 5.7 x 5.2 cm on the left shoulder, with the appearance of SCC, confirmed by biopsy (Figure 1).

Preoperative tests (laboratory and cardiological) were performed, which were normal and with surgical risk grade 1. After the demarcation of the tumor area with oncological safety margins, the patient underwent general anesthesia and was positioned in the right lateral decubitus position (Figure 2).

The lesion was resected with oncological margins and sent for anatomopathological examination, with the result of invasive squamous cell carcinoma grade 3 of differentiation, invasion to the subcutaneous tissue (Class V), free margins, no angiolymphatic involvement detected, and no perineural invasion.

A parascapular flap⁴ was demarcated, measuring (21cm x 6.5cm), based on the parascapular artery, a branch of the left axillary artery (Figure 3).

The flap was elevated and rotated to reach the left shoulder region (Figures 4 and 5) and sutured to its new bed with nylon 3-0 and 4-0. This completely covered the tumor resection area.

The donor area of the flap was repaired by advancing the local flaps and suturing with 3-0 and 2-0 nylon (Figure 6).

After 24 hours, there was a suture dehiscence in the distal part of the flap and pain at its extremity due to venous congestion (Figure 7).

Cyclic and continuous traction of the cutaneous margins³ was used to close the bloody area and a small part was partially left for healing by second intention (Figure 8).

The distal end of the parascapular flap⁴ with venous congestion evolved to dry necrosis of an area larger than the initial one, which did not require debridement (Figure 9).

The patient was followed up, requiring radiotherapy treatment, with good evolution and adequate surgical wound healing (Figures 10 and 11).

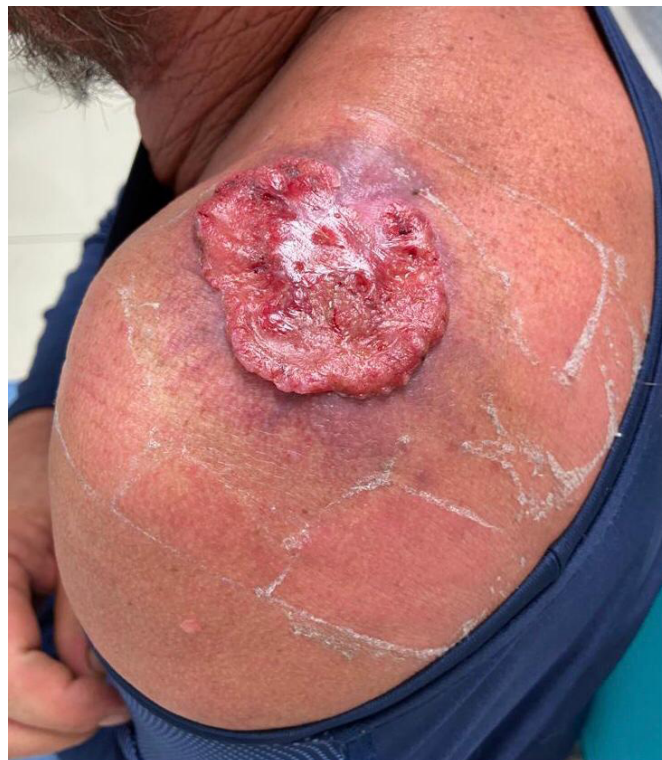

Figure 1. Ulcerated lesion measuring 5.7 x 5.2cm.

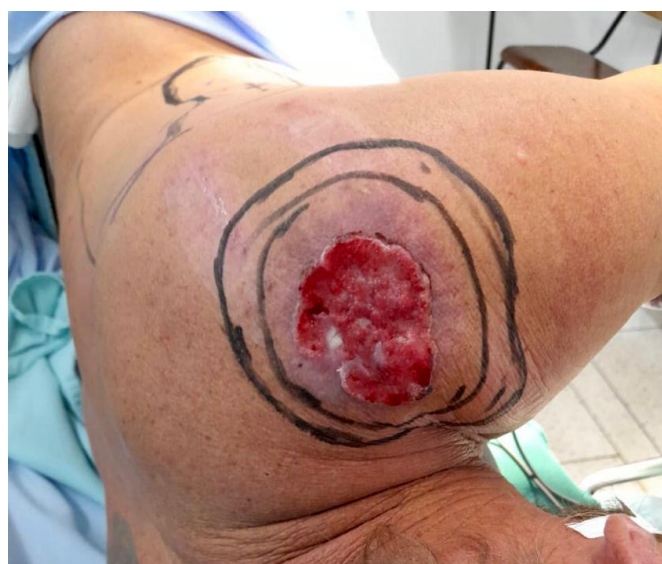

Figure 2. Patient in surgical positioning.

DISCUSSION

The literature cites numerous methods for covering the reported defect, including skin graft⁵, latissimus dorsi myocutaneous flap⁶, trapezius myocutaneous flap⁷, and microsurgical flaps⁸. The preference for the parascapular flap⁴ is due to its

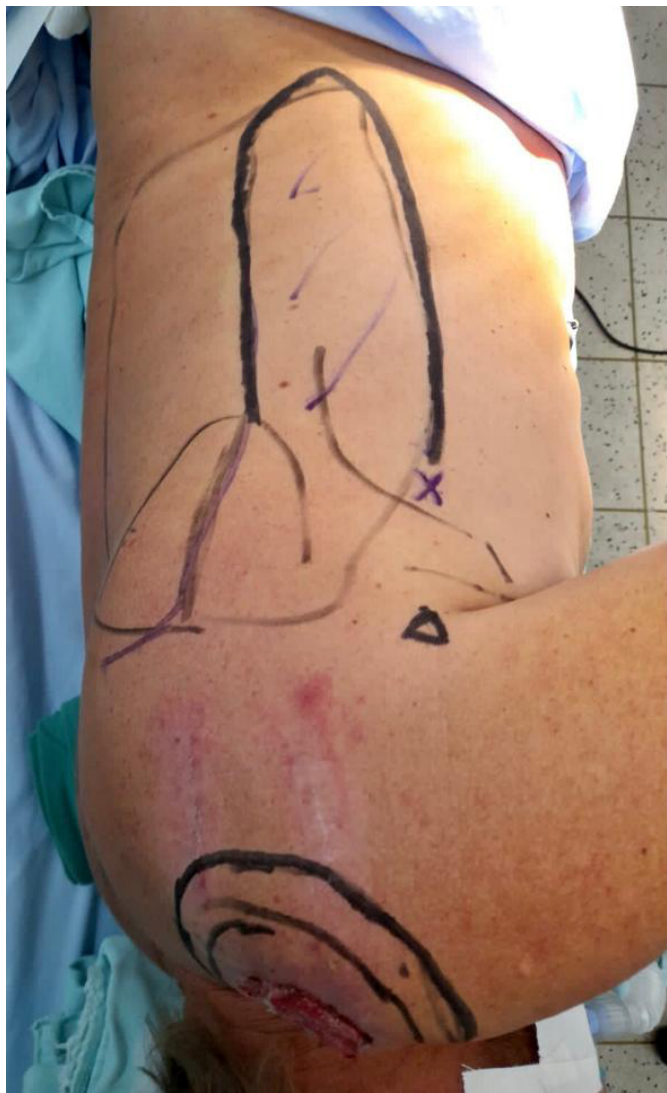

Figure 3. Demarcation of the parascapular flap.

greater ability to cover large areas, in addition to muscle preservation compared to other myocutaneous flaps, which generate great functional loss, requiring long periods for compensation, as is the case with the latissimus dorsi⁶ and trapezium flaps⁷.

Treatment with microsurgery⁸ is highly specialized, and our Service does not have the proper equipment, so we cannot perform it.

Due to the patient's profession (civil construction assistant), the skin graft⁵ would inevitably suffer loss with the work activity, causing a poor prognosis.

The parascapular flap⁴ is described in the literature with a length of up to 30 cm. Considering the patient's height of 1.82m, the length of the flap was adequate for its use, with the advantage of ensuring thick coverage - resistant to trauma and without muscle mobilization, allowing the patient to return to activities early.

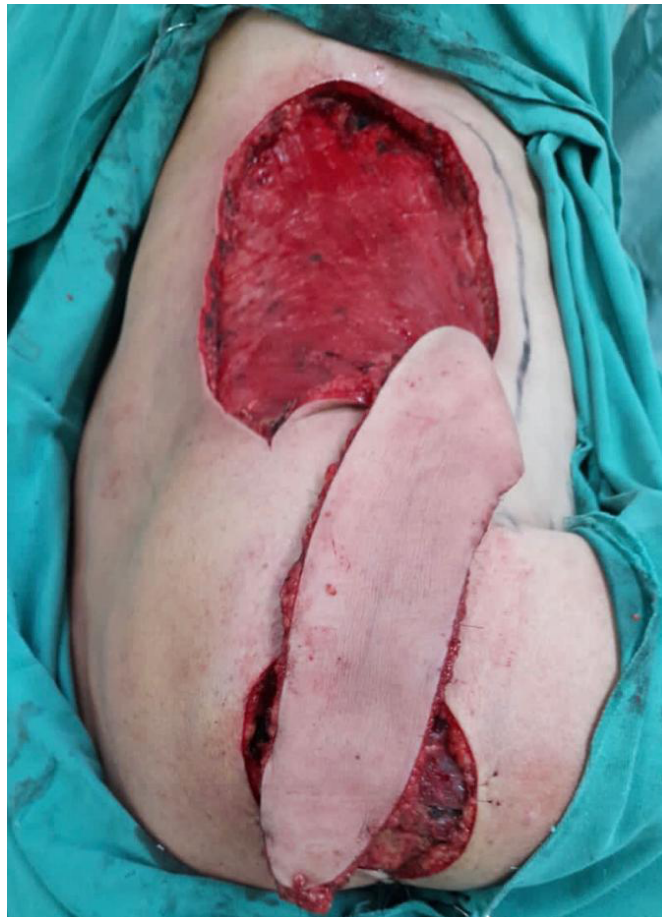


Figure 4. Elevation and rotation of the parascapular flap.

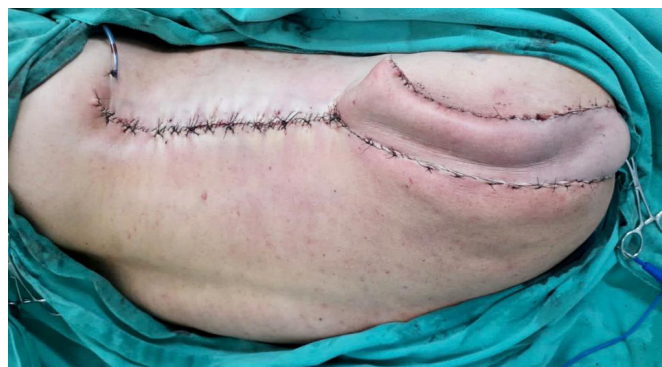

Figure 5. Elevation and rotation of the parascapular flap.

Wound closure by skin traction, recommended in 2004 by Carlos Henrique Fröner S. Góes et al.³, was performed in the ward on the second postoperative day to correct the dehiscence. For this purpose, Prolene 2 thread was used, with insertion in the area posterior to the detachment, exteriorizing it inside the wound, towards the other margin, and the thread is wrapped through the needle with a catheter segment. A "U" was completed bilaterally by returning the thread in

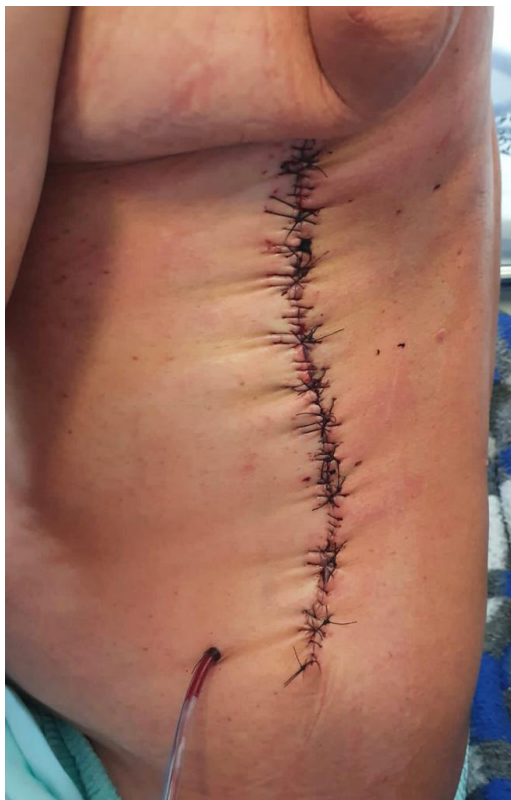

Figure 6. Donor region repair with 3-0 and 2-0 nylon.

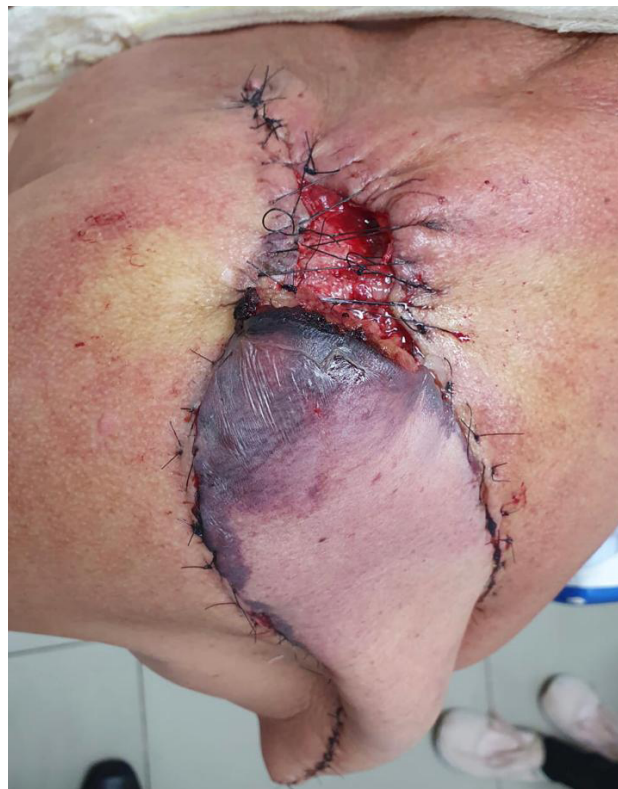

Figure 8. Use of the Góes Suture for partial closure of the dehiscence.

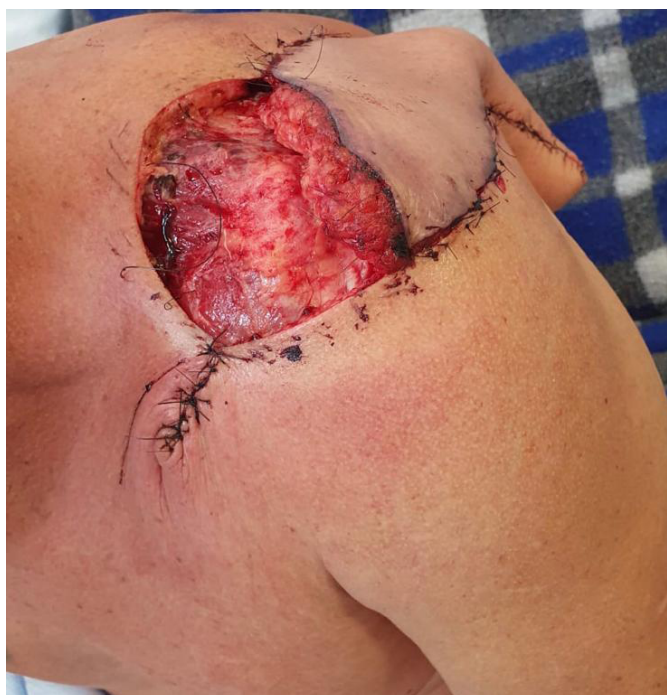

Figure 7. Dehiscence at the distal end of the parascapular flap.

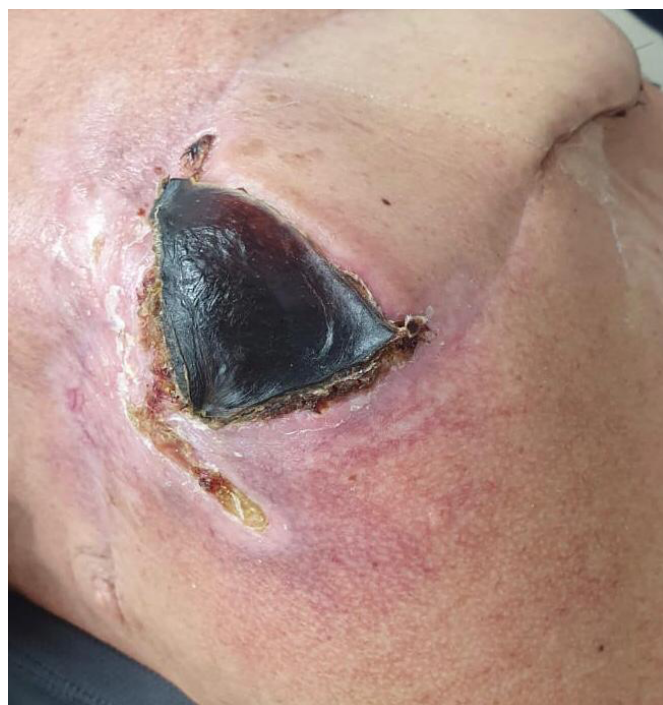

Figure 9. Dry necrosis at the distal end of the parascapular flap.

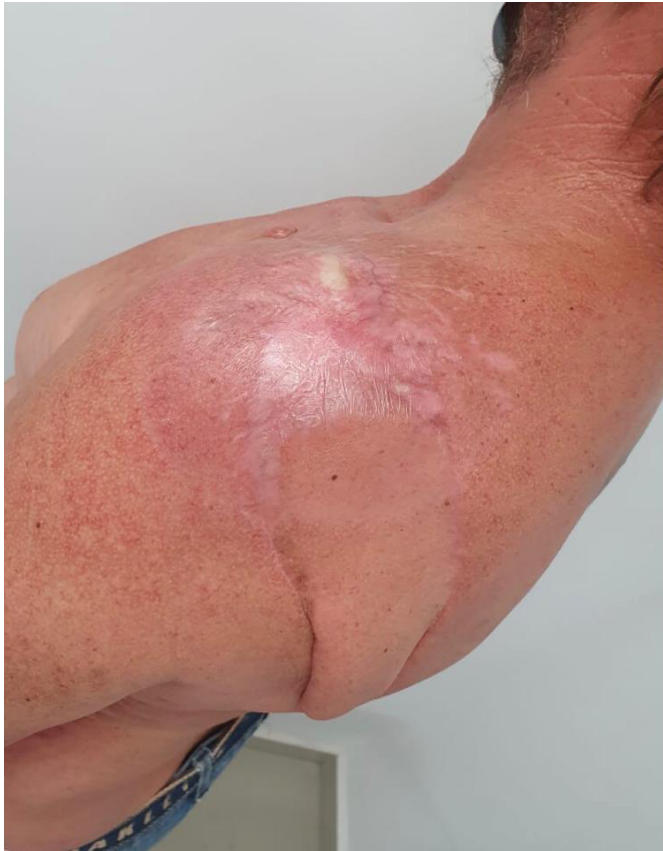

Figure 10. Late postoperative after radiotherapy.

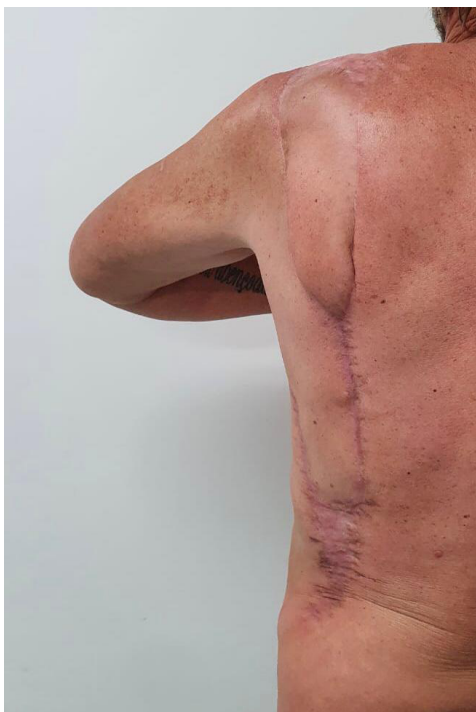

Figure 11. Late postoperative after radiotherapy.

reverse. The two threads on each side were pulled simultaneously, bringing the edges together with a certain point of maximum tension. Through repeated traction, greater skin relaxation and the possibility of partial closure were promoted. This avoided performing a new procedure in a surgical center, which would cause great emotional stress to the patient and higher costs to the institution that maintains it.

The suture proved an efficient method, promoting partial closure of the defect (80% of the dehiscence area), ease, and reduced time to perform in addition to one-time residual defect correction.

CONCLUSION

The suture proposed by Góes et al.³ proved to complement the parascapular flap⁴ in covering the resection of large tumor areas, with the advantages of being low-cost and easy to perform. In addition, skin traction provided satisfactory correction of large postoperative dehiscence using a parascapular flap⁴.

COLLABORATIONS

- MR** Conceptualization, Realization of operations and/or trials.
- LGB** Writing - Review & Editing.
- FSM** Conception and design study, Conceptualization, Final manuscript approval, Methodology, Writing - Original Draft Preparation, Writing - Review & Editing.
- BSM** Supervision, Writing - Original Draft Preparation.
- CMSS** Writing - Original Draft Preparation.
- LSA** Writing - Original Draft Preparation.
- MVA** Writing - Original Draft Preparation.
- LFAO** Validation.

REFERENCES

1. Simis T, Simis DRC. Doenças da pele relacionadas à radiação solar. *Rev Fac Ciênc Méd (Sorocaba)*. 2006;8(1):1-8.
2. Silva RD, Dias MAI. Incidência do carcinoma basocelular e espinocelular em usuários atendidos em um hospital de câncer. *Rev Fam Ciclos Vida Saúde Contexto Soc*. 2017;5(2):228-34.
3. Góes CHFS, Kawasaki MC, Mélega JM. Fechamento de feridas por tração cutânea intra-operatória: análise de 23 casos. *Rev Bras Cir Plást*. 2004;19(2):63-74.
4. Nassif TM, Vidal L, Bovet JL, Baudet J. The parascapular flap: a new cutaneous microsurgical free flap. *Plast Reconstr Surg*. 1982;69(4):591-600.

5. Lofêgo Filho JA, Dadalti P, Souza DC, Souza PRC, Silva MAL, Takiya CM. Skin grafts in cutaneous oncology. *An Bras Dermatol.* 2006;81(5):465-72.
6. Tavares-Filho JM, Franco D, Moreto L, Porchat C, Franco T. Utilização do retalho miocutâneo de grande dorsal, com extensão adiposa, nas reconstruções mamárias: uma opção para preenchimento do polo superior. *Rev Bras Cir Plást.* 2015;30(3):423-8.
7. Sbalchiero JC, Graziosi GB. Retalho miocutâneo inferior pediculado do músculo trapézio nas reconstruções após cirurgias oncológicas de cabeça e pescoço, e tórax. *Rev Bras Cir Plást.* 2014;29(3):346-51.
8. Andrade FAG, Servant JM, Ferreira LM, Revol M, Traber H, Nascimento Júnior CP, et al. Decúbito Dorsal no Retalho Microcirúrgico do Músculo Grande Dorsal - Técnica de J. M. Servant. *Rev Bras Cir Plást.* 2000;15(2):35-46.

***Corresponding author:**

Franco Silva Martinez

Rua Petrópolis, 585, Caiçara, Campo Grande, MS, Brazil

Zip Code: 79090-234

E-mail: francosmartinez99@gmail.com