



# Breast implant-associated anaplastic large-cell lymphoma: a systematic literature review

*Linfoma anaplásico de grandes células relacionado ao implante mamário: revisão sistemática da literatura*

DANIEL SUNDFELD SPIGA REAL<sup>1\*</sup>   
BEATRIZ SANT'ANA RESENDES<sup>1</sup> 

Institution: Universidade Federal de São Carlos, São Carlos, SP, Brazil.

Article received: June 8, 2019.

Article accepted: July 22, 2019.

Conflicts of interest: none.

DOI: 10.5935/2177-1235.2019RBCP0234

## ■ ABSTRACT

Breast implant-associated anaplastic large-cell lymphoma (BIA-ALCL) is a newly discovered and rare cancer possibly associated with textured breast implants. This literature review investigates its epidemiology, pathophysiology, and risk factors. PubMed, LILACS, and SciELO databases were searched from December 2018 to February 2019, and 10 articles published between 2016 and 2018 were selected. The incidence of BIA-ALCL ranged from 2.8:100,000 to 1:3 million breast implants. The obtained data corroborate the hypothesis that there is no direct cause and effect relationship between breast implants, especially textured implants, and BIA-ALCL, and these implants can be considered risk factors but not causative factors. The most accepted hypothesis on disease pathophysiology is that breast implants with larger surface areas may promote bacterial adhesion and biofilm formation, leading to severe chronic inflammation, triggering the malignant transformation of T cells. This review provides knowledge on BIA-ALCL and helps develop and implement public policies for disease prevention and timely diagnosis. The data highlight that long-term follow up is necessary and that surgeons should advise patients of the potential risk of developing BIA-ALCL before performing the implant surgery.

**Keywords:** Breast implant; Anaplastic large-cell lymphoma; T-cell lymphoma; Non-Hodgkin's lymphoma; Breast cancer.

<sup>1</sup> Universidade Federal de São Carlos, São Carlos, SP, Brazil.

## ■ RESUMO

O linfoma anaplásico de grandes células associado ao implante de mama (Breast Implant Associated *Anaplastic Large Cell Lymphoma* - BIA-ALCL) é uma doença maligna recentemente descoberta, rara e possivelmente associada aos implantes mamários texturizados. Essa revisão da literatura teve como objetivo trazer novas atualizações acerca da epidemiologia, fisiopatologia e fatores de risco para desenvolvimento do BIA-ALCL. Foi realizado o levantamento de dados do período de dezembro de 2018 a fevereiro de 2019, através das bases de dados PUBMED, LILACS e Scielo sendo selecionados 10 artigos publicados entre 2016 e 2018. Foi encontrada uma incidência variando entre 2,8:100.000 a 1:3 milhões de pacientes com implantes mamários. Os dados coletados corroboram para a teoria de que não há uma relação direta de causa e efeito entre os implantes mamários, mormente os texturizados, e o desenvolvimento do BIA-ALCL, podendo esses ser considerados somente como fatores de risco e não agentes causadores. A teoria fisiopatológica mais aceita é a de que os implantes mamários com maior área de superfície levariam a formação de maior biofilme por maior adesão bacteriana gerando inflamação crônica mais proeminente, levando ao gatilho para a transformação maligna das células T. As informações explicitadas nessa revisão devem auxiliar na ampliação de estudos acerca da doença e criação de políticas públicas para a prevenção e diagnóstico precoce de tal enfermidade. Pelos dados encontrados há necessidade de que cirurgiões plásticos realizem acompanhamento mais próximo de seus pacientes, assim como orientem os pacientes antes das cirurgias sobre a existência da doença.

**Descritores:** Implante mamário; Linfoma anaplásico de células grandes; Linfoma de células T; Linfoma não Hodgkin; Neoplasias da mama.

## INTRODUCTION

Breast implant-associated anaplastic large-cell lymphoma (BIA-ALCL) is a CD30<sup>+</sup> and ALK<sup>-</sup> T-cell lymphoma of the group of non-Hodgkin's lymphoma<sup>1</sup>. This newly discovered cancer may be linked with breast implants, especially textured implants used in cosmetic and reconstructive surgery<sup>2</sup>.

The first case of BIA-ALCL was reported in 1997 by Keech and Creech<sup>3</sup>, and in 2016, the World Health Organization classified this cancer as a recognized entity<sup>4</sup>.

The estimated incidence of BIA-ALCL is one case per 30,000 breast implants per year, and the average time of disease development after implantation is 10.7 years<sup>5</sup>. Variations in the estimated risk of BIA-ALCL (1:3,000,000 to 1:50,000 breast implants) may be due to limitations in obtaining the clinical history of affected patients, discrepancies in pathological diagnosis, underreporting, misdiagnoses, duplicated cases, and lack of accurate data on the total number of implants sold and that implanted<sup>1</sup>.

The pathogenesis and mechanisms underlying BIA-ALCL remain unclear. One of the hypotheses is that textured implants with the mammary microbiome may trigger malignant transformation by increasing the risk of chronic antigen-guided inflammation.

The larger surface area and embossed surface of textured implants decrease the rate of capsular contracture but promote increased bacterial adhesion and biofilm formation<sup>2</sup>, leading to higher local inflammation. Despite the increasing evidence on the correlation of chronic inflammation with the etiology of BIA-ALCL, conclusions should be cautiously drawn because this disease is poorly understood<sup>6</sup>.

The possible association between breast implant and disease onset highlights the need for health authorities worldwide to monitor the disease progression and promote research on this type of cancer<sup>7</sup>.

This literature review investigates the epidemiology, pathophysiology, and risk factors of BIA-ALCL and present new evidences on the role of breast implants on disease pathogenesis.

## METHODS

PubMed, LILACS, and SciELO databases were searched from December 2018 to February 2019 using the following descriptors: “BIA-ALCL”; “texturized implants”; “implantes texturizados”; “polyurethane implants”; and “implantes de poliuretano” (*Breast Implant and Anaplastic Large Cell Lymphoma*).

The inclusion criteria were four types of study—systematic literature review, case reports, retrospective descriptive studies, and clinical trials—published in English and Portuguese. The exclusion criteria were duplicate articles, articles published before December 2015, methodology inappropriate for the purpose of the study, and studies published in languages other than English and Portuguese.

A total of 53 articles were selected according to the exclusion criteria. Articles repeated in databases ( $N = 11$ ), not written in English or Portuguese ( $N = 2$ ), not related to the focus of this systematic review after reading the titles ( $N = 18$ ), and not related to the objective of this review after reading abstracts ( $N = 12$ ) were excluded. No articles were excluded according to the type of study.

After exclusion, 10 articles published between 2016 and 2018 on the epidemiology, physiopathology, and risk factors associated with breast implants were selected. The flowchart of article selection is shown in Figure 1.

## RESULTS

The selected articles are shown in Table 1.

The following data were analyzed: epidemiology and pathophysiology of BIA-ALCL and types of breast implants were potentially correlated with higher risk of comorbidity development.

### Epidemiology

Data on the prevalence and incidence of BIA-ALCL were collected. The estimated prevalence in the United States between 1996 and 2015 was 1:30,000 textured implants<sup>2</sup>. De Jong et al. 2008<sup>8</sup> reported that the estimated incidence of BIA-ALCL was 1–3 cases per 1 million breast implants per year<sup>6</sup>. A retrospective descriptive study from the Italian Ministry of Health indicated that the estimated incidence of BIA-ALCL in Italy was 2.8:100,000 at-risk patients (with implants) in 2015 and 2.3:100,000 at-risk patients in 2016<sup>7</sup>. The Australian Therapeutic Products Administration reported that the incidence of BIA-ALCL in December 2016 ranged from 1:1,000 to 1:10,000 textured implants<sup>7</sup>. A study found that the estimated risk of BIA-ALCL ranged between 1–500,000 and 1–3 million breast

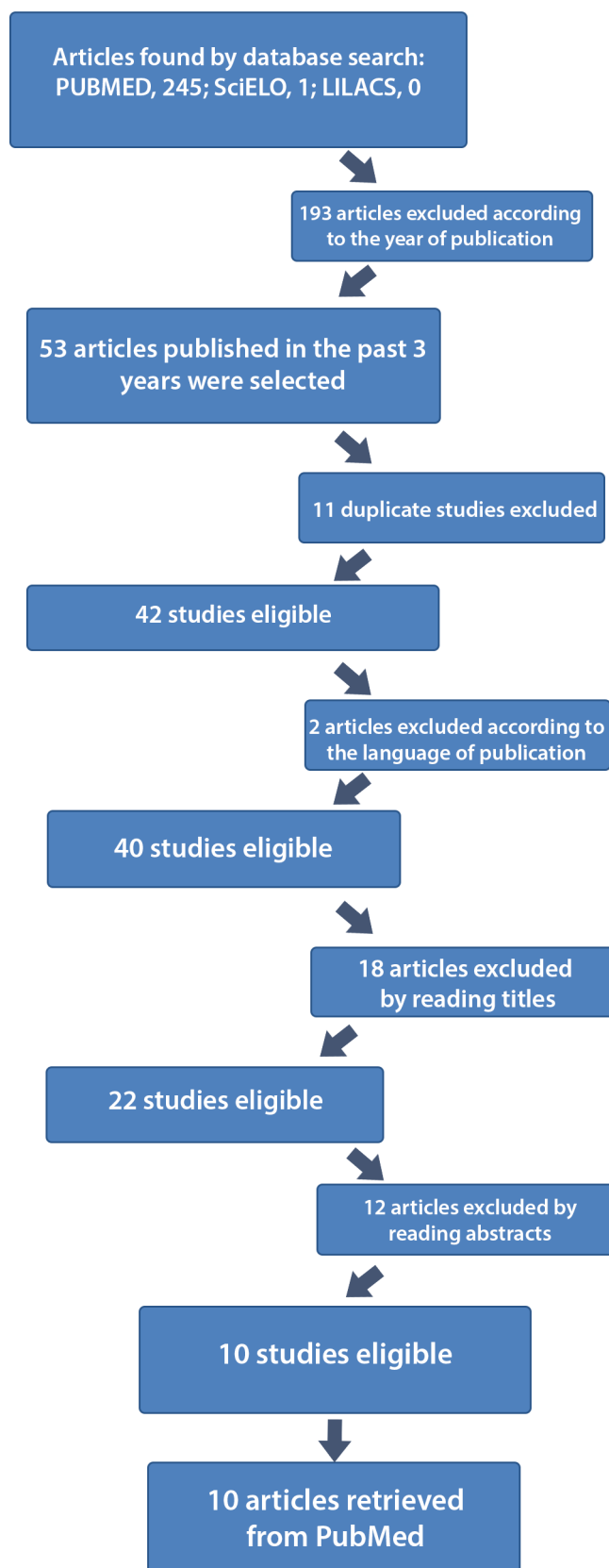


Figure 1. Articles selection flow.

Chart 1. Selected articles.

Title	Authors	Date of publication/ journal	Type research article	Methodology
1) Breast Implant-Associated Anaplastic Large Cell Lymphoma <sup>2</sup>	Rastogi P, Deva AK, Prince HM	October 22, 2018 Current Hematologic Malignancy Reports Journal	Literature review	Not described by the authors.
2) Breast implant associated anaplastic large cell lymphoma: a pictorial review <sup>8</sup>	Chacko A, Lloyd T	April 30, 2018 Insights Into Imaging Journal	Case report	Not described by the authors.
3) Breast implant associated anaplastic large cell lymphoma: The UK experience. Recommendations on its management and implications for informed consent <sup>5</sup>	Johnson L, O'Donoghue JM, McLean N, Turton P, Khan AA, Turner SD, et al.	May 8, 2017 European Journal of Surgical Oncology	Retrospective descriptive study	A retrospective study of data on breast implants, clinical evaluation, treatment, and follow-up of 18 patients diagnosed with BIA-ALCL between 2012 and 2016 at 15 regional centers in the United Kingdom.
4) Breast Implant-Associated Anaplastic Large Cell Lymphoma: Case Report and Review of the Literature <sup>3</sup>	Berlin E, Singh K, Mills C, Shapira I, Bakst RL, Chadha M	Jan 21, 2018 Case Reports in Hematology Journal	Case report and literature review	Not described by the authors.
5) Breast Implant-Associated Anaplastic Large Cell lymphoma A Systematic Review <sup>4</sup>	Leberfinger AN, Behar BJ, Williams NC, Rakszawshi KL, Potochny JD, Mackay DR, et al.	Oct 18, 2017 JAMA Surgery Journal	Systematic literature review	A systematic review of BIA-ALCL. The keywords used were BIA-ALCL, lymphoma, breast implants, and breast implant-associated lymphoma. The databases used were PubMed, EBSCOhost, Web of Science, and Google Scholar. A total of 115 studies indexed from August 1997 to January 2017 were selected.
6) Breast Implant-Associated Anaplastic Large Cell Lymphoma: A Case Report and Review of the Literature <sup>7</sup>	Ezekwudo DE, Ifabiyi T, Gbadamosi B, Haberichter K, Yu Z, Amin M, et al.	Oct 31, 2017 Case Reports in Oncological Medicine	Case report and literature review	A rare case of BIA-ALCL was reported. The rare presentation and histopathological characteristics of the indolent and infiltrative form and its clinical relevance were discussed after reviewing the literature.
7) 22 Cases of Breast Implant-Associated ALCL: Awareness and Outcome Tracking from the Italian Ministry of Health <sup>6</sup>	Campanale A, Boldrini R, Marletta M.	April 14, 2017 Plastic and Reconstructive Surgery Journal	Retrospective descriptive study	A retrospective study based on BIA-ALCL cases obtained from the database of the Directorate-General for Medical Devices and Pharmaceutical Services of Italy. The following variables were analyzed: identification number, companies that manufactured the implants currently used by the patients, implant filling and surface, time since implantation, previous breast surgery, indication for implantation, patient age, symptoms, BIA-ALCL markers, BIA-ALCL staging, treatment, and follow-up.

Continue...

Continuation...

8) Implications of Breast Implant-Associated Anaplastic Large Cell Lymphoma (BIA-ALCL) for Breast Cancer Reconstruction: An Update for Surgical Oncologists <sup>9</sup>	O'Neill AC, Zhong T, Hofer SOP	Jul 31, 2017 Annals of Surgical Oncology	Literature review	Not described by the authors.
9) Breast Implant and Anaplastic Large Cell Lymphoma Meta-Analysis <sup>10</sup>	Gallardo GR, Pardo JC, Olivares ER, Moreno RI, Bulnes LC, Rodríguez AV, et al.	Jul 18, 2016 Journal of Investigative Surgery	Systematic review with meta-analysis	A meta-analysis was performed by reviewing the databases PubMed, Embase, Cochrane, Fistera, Google Scholar, and LILACS. Articles indexed from 1980 to August 2015 were screened using the following MESH terms: lymphoma or non-Hodgkin's lymphoma or large-cell anaplastic lymphoma or ALCL or BIA-ALCL, breast implant or breast prosthesis, breast implants or silicone or silicone gel, and adverse effects.
10) Breast Implant-Associated Anaplastic Large Cell Lymphoma in Australia and New Zealand: High-Surface-Area Textured Implants Are Associated with Increased Risk <sup>1</sup>	Loch-Wilkinson A, Beath KJ, Knight RJW, Wessels WLF, Magnusson M, Papadopoulos T, et al.	October 2017 Journal of Plastic and Reconstructive Surgery	Retrospective descriptive study	All cases diagnosed in Australia and New Zealand were identified and analyzed. Data on implant history and the frequency of use of different types of breast implants were obtained. BIA-ALCL + was also listed. The surface area of different types of implant (textured [Silimed, Biocell, and Siltex] and smooth implants) were measured. Pathological diagnosis was confirmed through further examination of specimens by a pathologist. Sales data in 1999–2005 from three breast implant manufacturers (Mentor - Siltex, Allergan - Biocell and Silimed - polyurethane) were used to estimate implant-specific risk.

implants, and the incidence in the United States, based on the literature and institutional database, was 2.03:1 million people per year<sup>7</sup>.

The incidence of BIA-ALCL varies worldwide (much lower in Asia than that in Western countries, lower in Brazil and Europe and higher in Australia and New Zealand)<sup>2</sup>, which may be related to the frequency of using smooth or textured implants in each country and genetic predisposition/race<sup>2</sup>.

The incidence and prevalence of BIA-ALCL have increased, which may be due to increased number of breast implant surgeries<sup>9,10</sup>.

### Breast implant characteristics

In 2017, the Food and Drug Administration provided 359 medical reports on BIA-ALCL; most of

them included patients with textured implants. Of the 232 cases with implant type information, textured and smooth implants were used in 203 and 28 patients, respectively<sup>4,9</sup>. All 18 cases reported in a retrospective study from the United Kingdom involved textured implants<sup>6</sup>. Ninety-five patients were included in the systematic review analyzed in this study, and most of them received textured implants<sup>5</sup>. Another study reported five cases of BIA-ALCL in a cohort of 17,656 women with textured Natrelle implants (Biocell), corresponding to a prevalence of at least 1:3,500 textured Natrelle implants<sup>2</sup>.

Although these cases included smooth and textured implants, the latter was used at some point by patients in almost all cases<sup>11</sup>. Some patients underwent multiple implant replacement surgeries, which may limit determining the type of implant used<sup>11</sup>.

Cases potentially caused by smooth implants may be due to incomplete clinical history<sup>11</sup>. The reviewed meta-analysis reported that implant surface was textured in 17 (21.3%) and was unknown in 63 (78%) patients, and none of them were related to smooth surface implants. The most common brands were McGhan (11 patients, 14%), Mentor (7%), and PIP (hydrogel, 3%). The brands were unknown in 76% patients<sup>12</sup>.

A retrospective descriptive study reported that all patients (N = 55) diagnosed with BIA-ALCL in Australia and New Zealand from 2007 to 2016 had textured implants. The reviewed meta-analysis indicated that the risk of BIA-ALCL was 14.11 times higher for Biocell textured implants (95% CI, 1.2–561.46; p = 0.0005) and 10.84 times higher for Silimed textured polyurethane implants (95% CI, 1.0–566.34; p = 0.05) as compared to Siltex textured implants. The brands with the highest estimated risk by the number of implants were Biocell (1:3,817), Silimed (1:7,788), and Siltex (1:60,631). The risk from polyurethane implants in this study may be overestimated because of the lower availability of this type of implant in the Australian and New Zealand markets as compared with the other two textured implants<sup>1</sup>.

A retrospective descriptive study from the Italian Ministry of Health showed that 21 cases involved textured silicone implants (polyurethane implant in one case) and one case included a double lumen (saline/silicone) implant with textured surface<sup>9</sup>. Fifteen patients received breast implants before the diagnosis of BIA-ALCL<sup>9</sup>. Although >97% implants used in Italy are textured and the 22 cases of BIA-ALCL were associated with textured silicone implants, our sample was not representative enough to correlate the disease pathogenesis with the type of implant<sup>7</sup>.

With current advancements in breast augmentation and reconstruction, the proportion of textured implants is significantly higher than that of smooth implants, which may partly explain why most cases involved textured implants<sup>6</sup>. Reported cases are limited to implants used in the United States because most BIA-ALCL studies come from this country. Therefore, further studies are necessary to correlate this disease with the type of implant in other countries<sup>11</sup>.

BIA-ALCL has been associated with silicone and saline implants<sup>9</sup>. The analyzed systematic review found that this type of cancer occurred in 61% of patients with silicone implants and 39% with saline implants. This result may be related to the increased use of textured silicone implants<sup>5</sup>. The materials used in implants were silicone (32, 40%), saline (28, 35%), polyurethane (2), combination of silicone and saline (1), and other materials (17)<sup>12</sup>. Several authors have found that the

number of implants was similar between different filling materials<sup>11</sup>. The analyzed literature review found no significant differences in the number of saline and silicone implants<sup>10</sup>.

### Pathophysiology

The pathophysiology of BIA-ALCL is unknown<sup>4,6,10</sup>. The development of this cancer may be due to several factors, including bacterial biofilm growth, textured implant surface, immune response, and patient genetics<sup>1,5</sup>.

Textured implants and the breast microbiome (especially Gram-negative bacteria) can potentially trigger malignant transformation by increasing the risk of chronic antigen-driven inflammation (predominantly via Th1 and Th17 lymphocytes)<sup>1,4,5,9,10</sup>. The central hypothesis is that concavities on textured implants predispose to subclinical infection and/or chronic inflammation because the larger surface area and embossed surface increase bacterial adhesion and biofilm formation as compared with smooth implants<sup>1,6,11</sup>.

Hu et al. 2015<sup>13</sup> analyzed the biofilm formed in humans and pigs, which found that lymphocytic response was higher in textured implants than that in smooth implants. In addition, most cells present in the infiltrate were T lymphocytes, and the number of B and T cells linearly increased with the increasing bacterial load<sup>4</sup>.

Honghua et al. 2016<sup>14</sup> reported that the prevalence of Gram-negative *Ralstonia* spp. increased in the implant capsule microbiome collected from patients with BIA-ALCL as compared with controls<sup>5,6</sup>. A study analyzed healthy and cancerous breast tissues in patients with BIA-ALCL and found that both tissues had similar microbiome; however, the number of bacteria was significantly lower in healthy tissues<sup>5</sup>.

A study found that Gram-negative bacteria were identified in ALCL, whereas Gram-positive bacteria were isolated from capsular contractures<sup>12</sup>. Another study suggested that nosocomial infection was the etiologic agent due to the clustering pattern and the presence of multiple events<sup>1</sup>. The time of disease development supports this hypothesis because it is similar with the time of onset of inflammation, immune activation, and transformation to cancer triggered by biofilms. Moreover, no cases of BIA-ALCL were found in the years preceding the use of textured implants<sup>5</sup>. Silicon particles embedded in implant capsules have been suggested to possibly initiate an inflammatory response<sup>11</sup>.

Host genetic factors appear to play a role in this disease, including *Janus Kinase and Signal Transducer and Activator of Transcription 3 (JAK-*



*STAT3*) mutations related to cell proliferation, differentiation, and apoptosis, mutations in *tp53* and DNA methyltransferase 3A (*DNMT3A*), and genetic alterations associated with chronic inflammation<sup>2,5,10</sup>.

Despite the increasing evidence that chronic inflammation is an etiological factor in this type of cancer, conclusions should be cautiously drawn because this disease is poorly understood<sup>6</sup>.

## DISCUSSION

Epidemiological data on BIA-ALCL demonstrate that the estimated incidence of this disease significantly varies according to the type of study and evaluated variables. The incidence varies by country and type of implant (textured or not). Differences in disease incidence between countries may be due to differences in the frequency of using smooth and textured implants. Nonetheless, the role of genetic predisposition and race in this variability cannot be ruled out.

With respect to the types of breast implant surfaces and their possible involvement in BIA-ALCL, data from the literature review corroborate the hypothesis that textured implants play a significant role in the disease etiology. Disease incidence was higher in patients with textured implants or history of previous use of these implants. However, given the limited data on BIA-ALCL and the current market for breast implants, the causative role of textured implants on disease development was not confirmed, suggesting the latter as a risk factor. Differences in the incidence of BIA-ALCL among different filling materials were also not significant.

Most implants used in the past few years are notably textured, which may constitute a major analysis bias because, polyurethane-coated implants would pose a 10.84-fold higher risk for BIA-ALCL than textured implants despite the low utilization of the former in a proportional regression analysis.

The most accepted hypothesis on disease pathophysiology is that textured implants have a larger surface area and thus a higher interface with the environment, which promotes bacterial adhesion and biofilm formation. Gram-negative bacteria in biofilms associated with chronic inflammation can activate the immune system predominantly via Th1 and Th17 responses. Chronic inflammation and host genetic factors (*JAK-STAT3*, *tp53*, and *DNMT3A* mutations) can trigger the malignant transformation of T cells, potentially leading to BIA-ALCL.

## CONCLUSION

BIA-ALCL is a rare and poorly understood type of cancer. The analyzed data indicate that there is no

direct cause and effect relationship between breast implants, especially textured implants, and BIA-ALCL, and thus, this type of cancer can be considered a risk factor but not a causative agent.

Therefore, follow-up should be long-term, and plastic surgeons should acknowledge the existence of BIA-ALCL to ensure timely diagnosis and effective treatment.

Health professionals should explain to patients the characteristics and incidence of BIA-ALCL. In addition, given that this cancer is manifested in approximately 10 years, these professionals should perform a thorough physical examination of the breasts and inform patients that unexpected symptoms may warrant complementary examinations.

Data from this literature review may lay the foundation for future studies to assess risk factors and pathophysiology and help develop and implement public policies for the prevention, early diagnosis, and management of BIA-ALCL.

## COLLABORATIONS

**DSSR** Analysis and/or data interpretation, Conception and design study, Conceptualization, Data Curation, Final manuscript approval, Investigation, Methodology, Project Administration, Resources, Supervision, Writing - Original Draft Preparation, Writing - Review & Editing

**BSR** Analysis and/or data interpretation, Conceptualization, Data Curation, Investigation, Methodology, Project Administration, Realization of operations and/or trials, Writing - Original Draft Preparation, Writing - Review & Editing

## REFERENCES

- Loch-Wilkinson A, Beath KJ, Knight RJW, Wessels WLF, Magnusson M, Papadopoulos T, et al. Breast implant-associated anaplastic large cell lymphoma in Australia and New Zealand: high-surface-area textured implants are associated with increased risk. *Plast Reconstr Surg*. 2017 Oct;140(4):645-54.
- Rastogi P, Deva AK, Prince HM. Breast implant-associated anaplastic large cell lymphoma. *Current Hematologic Malig Rep*. 2018 Dec;13(6):516-24.
- Keech JA Jr, Creech BJ. Anaplastic T-cell lymphoma in proximity to a saline-filled breast implant. *Plast Reconstr Surg*. 1997 Aug;100(2):554-5.
- Berlin E, Singh K, Mills C, Shapira I, Bakst RL, Chadha M. Breast implant-associated anaplastic large cell lymphoma: case report and review of the literature. *Case Rep Hematol*. 2018 Jan;2018:2414278.
- Leberfinger AN, Behar BJ, Williams NC, Rakszawshi KL, Potochny JD, Mackay DR, et al. Breast implant - associated

- anaplastic large cell lymphoma: a systematic review. *JAMA Surg.* 2017 Dec;152(12):1161-68.
6. Johnson L, O'Donoghue JM, McLean N, Turton P, Khan AA, Turner SD, et al. Breast implant associated anaplastic large cell lymphoma: The UK experience. Recommendations on its management and implications for informed consent. *Eur J Surg Oncol.* 2017 Aug;43(8):1393-401.
  7. Campanale A, Boldrini R, Marletta M. 22 Cases of Breast implant-associated ALCL: awareness and outcome tracking from the Italian Ministry of Health. *Plast Reconstr Surg.* 2018 Jan;141(1):11e-19e.
  8. Jong D, Vasmel WL, Boer JP, Verhave G, Barbé E, Casparie MK, et al. Anaplastic large-cell lymphoma in women with breast implants. *JAMA.* 2008 Nov 5;300(17):2030-5.
  9. Ezekwudo DE, Ifabiyi T, Gbadamosi B, Haberichter K, Yu Z, Amin M, et al. Breast implant-associated anaplastic large cell lymphoma: a case report and review of the literature. *Case Rep Oncol Med.* 2017 Oct;2017:6478467:[aprox.6 telas].
  10. Chacko A, Lloyd T. Breast implant-associated anaplastic large cell lymphoma: a pictorial review. *Insights into Imaging.* 2018 Oct;9(5):683-6.
  11. O'Neill AC, Zhong T, Hofer SOP. Implications of breast implant - associated anaplastic large cell lymphoma (BIA-ALCL) for breast cancer reconstruction: an update for surgical oncologists. *Ann Surg Oncol.* 2017 Oct;24(11):3174-3179.
  12. Gallardo GR, Pardo JC, Olivares ER, Moreno RI, Bulnes LC, Rodríguez AV, et al. Breast implant and anaplastic large cell lymphoma meta-analysis. *J Invest Surg.* 2017 Feb;30(1):56-65.
  13. Hu H, Jacombs A, Vickery K, Merten SL, Pennington DG, Deva AK. Chronic biofilm infection in breast implants is associated with an increased T-cell lymphocytic infiltrate: implications for breast implant-associated lymphoma. *Plast Reconstr Surg.* 2015 Feb;135(2):319-29.
  14. Hu H, Johani K, Almatroudi A, Vickery K, Van Natta B, Kadin ME, et al. Bacterial Biofilm Infection Detected in Breast Implant-Associated Anaplastic Large-Cell Lymphoma. *Plast Reconstr Surg.* 2016 Jun;137(6):1659-69.

---

**\*Corresponding author:**

**Daniel Sundfeld Spiga Real**

Rua Dr. Domingos Faro, 285, Jardim Alvorada, São Carlos, SP, Brazil.

Zip code: 13562-003

E-mail: dplasticsurgery@hotmail.com