




Neurofibromatosis type 1 with infraorbital nerve involvement: a case report

Neurofibromatose tipo 1 com acometimento do nervo infraorbital: relato de caso

MARCUS VINÍCIUS CAPANEMA
GONÇALVES^{1*} 

SÉRGIO MOREIRA DA COSTA¹ 

LILIANE CARVALHO JAMIL¹ 

KLAUS RODRIGUES DE OLIVEIRA¹ 

PAULA PIMENTEL ROCHA BOTELHO¹ 

CAMILA MATOS VERSIANI¹ 

ANDREIA SOUTO DA MOTTA¹ 

■ ABSTRACT

Neurofibromatosis type 1 (NF1) is a rare autosomal dominant disease with multiple clinical manifestations. Its most significant presentation is cutaneous or subcutaneous neurofibromas (myelin sheath tumors), which may be associated with other systemic manifestations such as café-au-lait spots and eye involvement. Neurofibromas can affect several peripheral nerves, including the facial nerves. This report presents a case of a 1-year-old patient with NF1 with right infraorbital nerve neurofibroma in which the proposed access for surgical treatment allowed adequate visualization of the tumor with good aesthetic results, preservation of the soft tissues, and normal facial growth.

Keywords: Neurofibroma; Neurofibromatosis type 1; Face; Orbital pseudotumor; Eye socket.

■ RESUMO

A neurofibromatose tipo 1 é uma doença autossômica dominante rara, com manifestações clínicas diversas. Sua apresentação mais marcante é a presença de neurofibromas (tumores da bainha neural) cutâneos ou internos, que também podem ocorrer de forma esporádica, associados a outras manifestações sistêmicas, como manchas café com leite e lesões oculares. Por serem tumores da bainha de mielina, os neurofibromas podem acometer diversos nervos periféricos, incluindo nervos da face. Apresentamos o caso de um paciente de 1 ano, portador de neurofibromatose tipo 1, com neurofibroma em nervo infraorbital direito, com o acesso proposto para tratamento cirúrgico que fornecesse ampla visualização e acesso a lesão, sem comprometimento estético importante, permitindo preservação de partes moles e adequado crescimento facial.

Descritores: Neurofibroma; Neurofibromatose 1; Face; Pseudotumor orbitário; Órbita.

Institution: Hospital Felício Rocho,
Belo Horizonte, MG, Brazil.

Article received: January 5, 2019.
Article accepted: July 8, 2019.

Conflicts of interest: none.

DOI: 10.5935/2177-1235.2019RBCP0237

¹ Hospital Felício Rocho, Barro Preto, Belo Horizonte, MG, Brazil.

INTRODUCTION

Neurofibromatosis type 1 (NF1) is an autosomal dominant disease and the most common type (96%) of neurofibromatosis. The other two types, neurofibromatosis type 2 (3%) and schwannomatosis, are clinically distinct from NF1 and not discussed in this study^{1,2}. NF1 is characterized by the presence of neurofibromas, skin and skeletal changes, and involvement of multiple organs and systems.

Neurofibromas, benign tumors consisting of Schwann cells, fibroblasts, mast cells, and perineural cells, may occur as solitary nodules or be associated with NF1, which manifests as solitary, multiple, or diffuse nodules. Nodules, the most common manifestation of NF1, occur in up to 60% of patients². The prevalence of NF1 is similar between the sexes, and the disease may be cutaneous or subcutaneous. The cutaneous form can be pedunculated, nodular, or flattened, and the number of nodules increases until adulthood². Subcutaneous neuromas may affect the deep tissues, including the periorbital region, retroperitoneal space, gastrointestinal tract, and mediastinum². Plexiform neuromas, the pathognomonic form of the disease², consist of subcutaneous neurofibromas that grow in a single nerve as well as in multiple fascicles and branches of a nerve or plexus.

Plexiform neuromas show a fascicular growth pattern ("bag of worms") and, in contrast to the cutaneous form, have an increased risk of malignant degeneration².

Neurofibrosarcomas, malignant tumors of the peripheral nerves, are rarer, representing 5–10% of soft tissue sarcomas, and primarily affect young adults³.

Epidemiology

The prevalence of NF1 worldwide is one case per 3,000 inhabitants, but it varies among countries and regions, reaching a prevalence of one case per 960 inhabitants in Israel¹. Regardless of the affected population, 50% of cases are due to family inheritance, while the others are caused by a *de novo* mutation of the disease-causing gene.

The life expectancy of affected patients is reduced by 8–21 years, and the leading cause of early death is the development of malignant tumors, which are more common in affected patients than in the general population¹.

Pathophysiology

NF1 is an autosomal dominant genetic disease with a 50% frequency of sporadic mutations¹. It is caused by a mutation in the NF1 tumor suppressor

gene located on chromosome 17q11.22 that expresses neurofibromin, a protein that negatively regulates RAS proto-oncogenes. Neurofibromin inactivates RAS by binding to RAS-GTP. The absence of neurofibromin activates RAS, which dysregulates cell growth and survival and leads to tumorigenesis and other abnormalities, including pigmentary lesions, skin tumors, and bone changes¹.

Clinical manifestations

Clinical manifestations are varied and may include dermal and plexiform neurofibromas, neurofibrosarcomas, pigmentary abnormalities (the most common non-neoplastic manifestations due to the common embryonic origin between melanocytes and Schwann cells), ophthalmic changes such as Lisch nodules, glaucoma and glioma, bone dysplasia (resulting from bone formation dysfunction due to osteoclast and osteoblast dysregulation), the involvement of several organs, and behavioral alterations. Neurofibromas may appear on any peripheral nerve; however, it is estimated that approximately 25% of symptomatic cases occur in the head and neck⁴.

Plexiform neurofibromas involving the eyelid, eye socket, periorbital areas, and facial structures may lead to visual loss in children at the age of visual maturity and occur predominantly along the trigeminal nerve pathway⁵. Although most cases of blindness are secondary to optic nerve gliomas, periorbital plexiform neurofibromas also cause vision loss secondary to amblyopia and glaucoma⁵.

Diagnosis and treatment

The diagnosis of NF1 is based on a thorough physical examination and family history of neurofibromatosis. A genetic analysis may be useful for diagnostic confirmation in challenging cases, including children younger than 6 years of age and patients without a family history of NF1. The National Institutes of Health proposed diagnostic criteria to improve early detection rates. Approximately 30% of patients with the disease meet at least one of the criteria by 1 year of age, 97% of patients meet two criteria by 8 years of age, and all patients meet all criteria by 20 years of age^{2,6}.

Diagnostic criteria for NF1:

Two or more of the following features: at least six café-au-lait spots (>5 mm in diameter in prepubertal children and >15 mm in postpubertal children); freckles in the axillary or inguinal region; optical glioma; at least two Lisch nodules (iris hamartomas); at least two neurofibromas of any type or one plexiform

neurofibroma; a single bone lesion; and a first-degree relative with NF1^{2,5} (Figure 1).

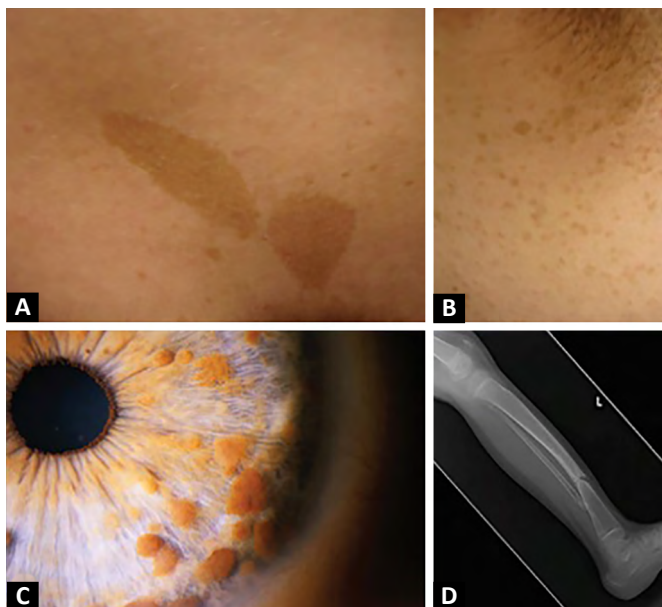


Figure 1. Non-neoplastic lesions caused by neurofibromatosis type 1 (NF1). A. Café-au-lait spots; B. Freckles in skin folds; C. Lisch nodules; D. Tibial pseudarthrosis and fracture in an affected child. Source: J.L. Anderson and D.H. Gutmann³.

The differential diagnosis includes Legius syndrome, skin hyperpigmentation, and tumors misdiagnosed as neurofibromas such as lipomas¹.

NF1 is progressive throughout life; nonetheless, its severity may vary significantly among affected patients.

NF1 has no definitive treatment, and its management is usually based on clinical follow-up and symptomatic treatment of systemic manifestations. Children who receive the early diagnosis should undergo immediate and long-term follow-up by a multidisciplinary team, including ophthalmological and dermatological consultations and routine blood pressure measurements considering the occurrence of renal artery vasculopathy^{7,8}.

Dermal neurofibromas usually cause itching, pain, bleeding, and aesthetic problems. Their management includes the surgical removal of larger lesions, laser ablation of smaller lesions, use of emollients, and psychological support^{1,5}.

All NF1 patients who wish to have children should be referred for genetic follow-up. Women should be advised of potential risks during pregnancy, including hypertension and increases in neurofibroma number and size⁷.

OBJECTIVE

This study aimed to describe a case of a 1-year-old child with infraorbital nerve neurofibroma

manifesting as an expansive and deforming mass in the right hemiface treated surgically with the facial approach to enable adequate tumor exposure and possible preservation of the facial tissues and aesthetics.

CASE REPORT

T.J.R.R., a male patient aged 1 year and 11 months, was followed up at the Dermatology Department for café-au-lait spots on the body surface and at the Ophthalmology Department for iris hamartomas (Lisch nodules), both of which are clinical manifestations of NF1². The patient was referred to the plastic surgery service for the assessment of an expansive and fibrotic lesion in the right maxilla, facial deformity including widening and lifting of the right nasal wing, and deformity in the ipsilateral lower eyelid. No visual, neurological, or neuromotor developmental delays were noted.

Computed tomography examination revealed a mass in the right maxillary sinus, involvement of the infraorbital nerve, and enlargement of the infraorbital foramen, possibly without bone involvement (Figure 2). An incisional biopsy identified the mass as a neuroma.

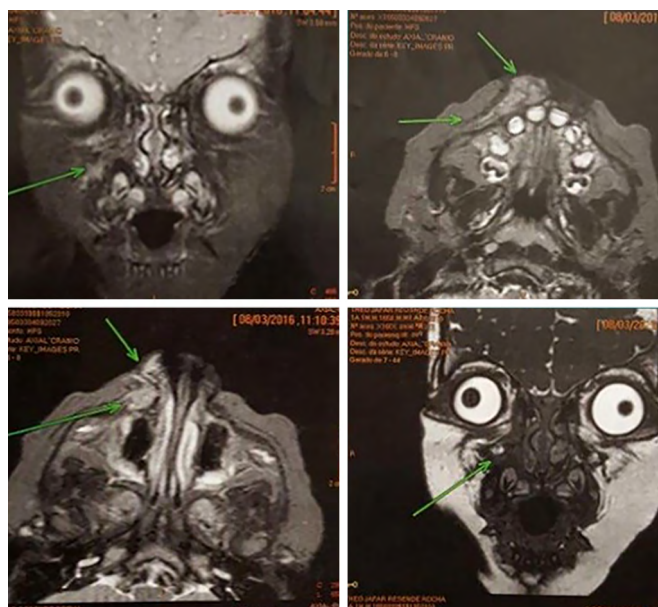


Figure 2. Magnetic resonance image showing an infraorbital lesion and widening of the infraorbital foramen.

The patient underwent complete resection of the mass by an open approach with access through a Weber-Ferguson incision. A retrograde resection (from bone to skin) was performed to preserve as much soft tissue as possible (Figures 3A, 3B). The origin of the infraorbital nerve and the surrounding mass and tissues were resected, and a flap and the superficial fat layer were preserved to cover the defect. There was no apparent bone involvement (Figures 4A, 4B).

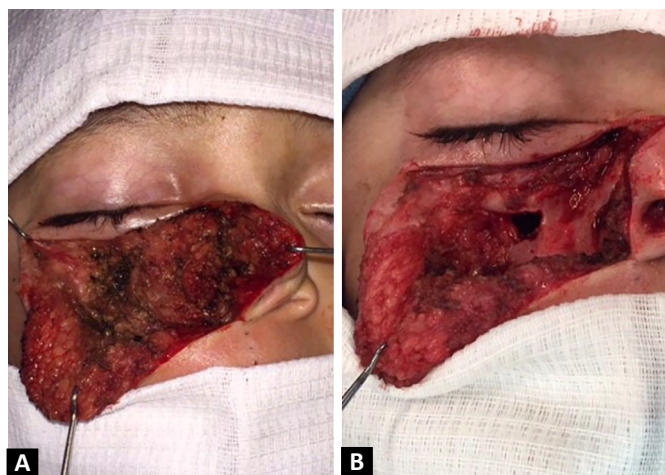
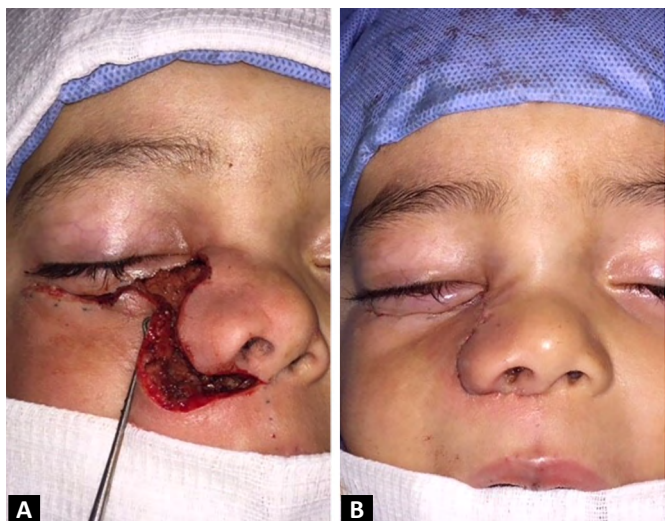

Figure 3. **A.** (Left): facial access showing a mass on the right face. **B.** (Right): resected mass showing the infraorbital foramen.



Figures 4A and 4B. Surgical site after resection (left) and surgical planes (right).

Histopathological examination of the surgical specimen indicated the presence of a neurofibroma surrounded by fibrotic tissue without involvement of the infraorbital foramen despite its widening.

The patient developed mild edema in the immediate postoperative period without complications associated with the surgical procedure. During the 3-year postoperative period, the affected hemiface had mild insensitivity to touch at the infraorbital nerve (which was difficult to measure because of the patient's age) without other sequelae or signs of relapse. The aesthetic results were good, with improved position of the nasal wing without pathological scarring or scar retraction.

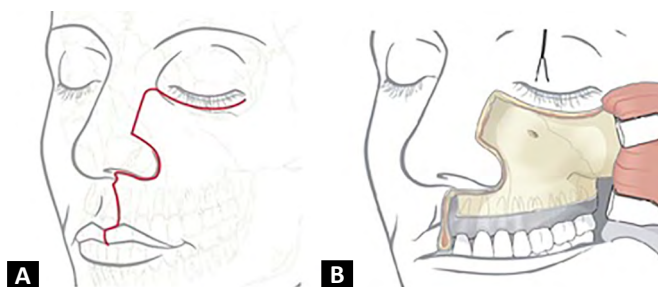
DISCUSSION

Surgical treatment of neurofibromas associated with NF1 can be challenging for the plastic surgeon,

especially those located on the face since they may cause skin deformities and sensory and motor sequelae due to peripheral nerve involvement. Moreover, affected children experience incomplete growth and development of the bones and soft tissues, demanding less aggressive resections.

The infraorbital nerve is the end of the maxillary branch of the trigeminal nerve (fifth cranial nerve), which emerges from the infraorbital foramen approximately 1 cm below the inferior orbital margin and is responsible for skin sensitivity in the medial portion of the cheek, part of the nose, lower eyelid, and upper lip⁹.

The Weber-Ferguson incision can be used to reach tumors in the maxilla and lower orbit and provides adequate access to these regions. Access may begin in the vermilion of the upper lip following the philtrum in the wing of the nose following the lateral part of the nasal dorsum and continuing to the lower eyelid, 3–4 mm below the ciliary margin. After a full-length incision is made, the flap is retracted after sub- or supraperiosteal dissection, depending on the surgical objective and tumor invasiveness¹⁰ (Figures 5A, 5B).



Figures 5A and 5B. Access through a Weber-Ferguson incision resulting in adequate exposure of the maxilla and infraorbital foramen. Source: AO Surgery Reference.

This type of incision allowed adequate tumor visualization. We began retrograde subperiosteal resection of the skin to preserve the unaffected soft tissues. This approach allowed resection of the entire tumor and preservation of a flap suitable for covering the defect without apparent deformities. Other possible incisions would be direct access to the tumor, intraoral incision in the vestibular gingival sulcus, or lateral access to the tumor.

Incisions in the skin over the lesions may result in unnecessary skin resections and visible scars and deformities. An intraoral incision, despite ensuring optimal bone exposure, does not provide adequate retraction of soft tissues. Lateral incisions are adequate in extensive dissections of the parotid and facial nerve branches to gain adequate tumor access.

CONCLUSION

The surgical approach through a Weber-Ferguson incision improved access to tumors in the infraorbital nerve with adequate exposure of the lesion, preservation of the soft tissues, and good aesthetic results, minimizing sequelae.

COLLABORATIONS

MVCG	Analysis and/or data interpretation, Conception and design study, Investigation, Writing - Original Draft Preparation, Writing - Review & Editing
SMC	Supervision
LCJ	Investigation, Writing - Review & Editing
KRO	Supervision
PP	Original Draft Preparation
CMV	Visualization
ASM	Visualization & Review

REFERENCES

1. Gutmann DH, Ferner RE, Listernick RH, Korf BR, Wolters PL, Johnson KJ. Neurofibromatosis type 1. *Nat Rev Dis Primers*. 2017 Feb;23(3):17004. DOI: <http://dx.doi.org/10.1038/nrdp.2017.4>
2. Kresiek JL, Walsh M. Neurofibromatosis: a review of NF1, NF2 and Schwannomatosis. *J Pediatr Genet*. 2016;5(2):98-104. DOI: <http://dx.doi.org/10.1055/s-0036-1579766>
3. Vasconcelos RAT, Coscarelli PG, Alvarenga RP, Acioly MA. Malignant peripheral nerve sheath tumor with and without neurofibromatosis type 1. *Arq Neuro-Psiquiatr* 2017;75(6):366-371. DOI: <http://dx.doi.org/10.1590/0004-282X20170052>
4. Bray DP, Chan AK, Chin CT, Jacques L. Large Cervical Vegus Nerve Tumor in a Patient with NF1 Treated with Gross Total Resection. *J Brachial Plex Peripher Nerve Inj*. 2016;11(1):e48-e54. DOI: <http://dx.doi.org/10.1055/s-0036-1594010>
5. Avery RA, Katowitz JA, Fisher MJ, Heidary G, Dombi E, Packer RJ, et al. Orbital/Periorbital plexiform neurofibromas in children with NF1. *Ophthalmology*. 2016 Jan;124(1):123-132. DOI: <http://dx.doi.org/10.1016/j.ophtha.2016.09.020>
6. Gutmann, et al. Neurofibromatosis type 1. *Handbook of Clinical Neurology*. 2015;132(4). DOI: <http://dx.doi.org/>
7. Dunning-Davies BM, Parker APJ. Annual review of children with neurofibromatosis type 1. *Arch Dis Child Educ Pract*. 2016;101:102-11. DOI: <http://dx.doi.org/10.1136/archdischild-2014-308084>
8. Hirbe AC, Gutmann DH. NF1: A multidisciplinary approach to care. *Lancet Neural*. 2014 Aug; 13(8):834-43. DOI: [http://dx.doi.org/10.1016/S1474-4422\(14\)70063-8](http://dx.doi.org/10.1016/S1474-4422(14)70063-8)
9. Neligan P, Warren R. *Plastic Surgery*. 3rd ed. Philadelphia: Saunders; 2013. v. 3.
10. Colton C, Krikler S, Schatzker J, Trafton P. AO-Foundation: Weber Ferguson Midface. *AO Surgery*. 2019;6(4).

***Corresponding author:**

Marcus Vinícius Capanema Gonçalves

Alameda Oscar Niemeyer, 1100, 1501C, Vila da Serra, Nova Lima, MG, Brazil.

Zip code: 34006-065

E-mail: marcusvic1@hotmail.com