







Rhinodelation or non-surgical rhinoplasty: a safe and reproducible approach

Rinomodelação ou rinoplastia não-cirúrgica: uma abordagem segura e reprodutível

RENATO MATTA RAMOS^{1,2*} 
HAILEN ESPITIA BOLIVAR³ 
PEDRO SALOMÃO PICCININI² 
EDUARDO SUCUPIRA³ 

Institution: Pontifícia Universidade
Católica do Rio Grande do Sul,
Porto Alegre, RS, Brazil.

Article received: October 14, 2018.
Article accepted: April 21, 2019.

Conflicts of interest: none.

DOI: 10.5935/2177-1235.2019RBCP0242

■ ABSTRACT

Introduction: Rhinoplasty often leads to unpredictable results, even in the hands of experienced surgeons. However, in specific cases, rhinodelation with fillers, a non-surgical procedure to correct minor nasal external changes, can be used. **Methods:** This study describes the application technique of fillers (hyaluronic acid or calcium hydroxyapatite) for nasal modeling. Patients undergoing nasal filling between 2009 and 2012 were included. Edema of the nasal tip, pain, and the degree of patient satisfaction with the outcome were assessed. **Results:** Thirty-nine patients were included in the study. Regarding the outcomes of rhinodelation with hyaluronic acid, 52% patients presented with mild edema, 74% had mild pain, 15% were very satisfied, and 74% were satisfied with the result. For the outcomes of rhinodelation with calcium hydroxyapatite, 67% patients presented with moderate edema, 50% had moderate pain; 17% had severe pain, and 84% were satisfied with the result. **Conclusion:** Rhinodelation with resorbable fillers is a simple procedure with acceptable esthetic results. However, a deep anatomical knowledge is necessary to decrease the risk of complications. **Keywords:** Nose; Rhinoplasty; Dermal Fillers; Acquired nasal deformities; Nasal diseases.

¹ Be-You Medical Spa, Cirurgia Plástica, Lima, Lima, Peru.

² Hospital São Lucas da Pontifícia Universidade Católica do Rio Grande do Sul, Porto Alegre, RS, Brazil.

³ Hospital Santa Casa da Misericórdia do Rio de Janeiro, Rio de Janeiro, RJ, Brazil.

■ RESUMO

Introdução: A rinoplastia é uma cirurgia que muitas vezes apresenta resultados imprevisíveis, mesmo em mãos de cirurgiões experientes. Neste sentido, a rinomodelação com preenchedores é um procedimento não-cirúrgico para corrigir pequenas alterações externas nasais em casos específicos. **Métodos:** Os autores descrevem a técnica de aplicação de preenchedores (ácido hialurônico ou hidroxiapatita de cálcio) para modelação nasal. Foram incluídos todos os pacientes submetidos ao preenchimento nasal, entre 2009 e 2012. Foi avaliado o edema da ponta nasal, a dor e o grau de satisfação dos pacientes com o resultado. **Resultados:** Foram incluídos 39 pacientes no estudo. Com relação aos desfechos analisados com ácido hialurônico: 52% apresentaram edema leve; 74% tiveram dor leve; 15% se mostraram muito satisfeitos e 74% satisfeitos com o resultado. Com relação aos pacientes submetidos à rinomodelação com hidroxiapatita de cálcio: 67% apresentaram edema moderado; 50% dor moderada; 17% dor intensa e 84% se mostraram satisfeitos com o resultado. **Conclusão:** A rinomodelação com preenchedores reabsorvíveis é um procedimento simples, com resultados estéticos aceitáveis, sendo necessário um profundo conhecimento anatômico para diminuir o risco de complicações. **Descritores:** Nariz; Rinoplastia; Preenchedores dérmicos; Deformidades adquiridas nasais; Doenças nasais.

INTRODUCTION

Rhinoplasty is a surgery that, even in experienced hands, presents unpredictable results, due to the anesthetic risks, possible functional and esthetic sequelae, and the necessary recovery period. As a result, rhinomodelation with fillers has been gaining popularity among both patients and medical professionals^{1,2}.

The idea arose at the end of the 19th century by Dr. Robert Gersuny, who used paraffin with the aim of increasing the nasal dorsum. Decades later, Robert Kotler and Jack Startz introduced silicone injections, leading to a high rate of granulomas and ulcers. In 1981, bovine collagen was introduced as the first facial filler approved for cosmetic use³; however, with the need for a safer product, calcium hydroxyapatite (CaHA) was used to shape some defects in the nose^{4,5}. Subsequently, with the popularization and experience amassed by plastic surgeons and dermatologists using hyaluronic acid (HA), this became the most commonly used filler due to its reversibility with the use of hyaluronidase in the event of hypercorrection or inadvertent vascular lesions and its lower durability when compared to CaHA⁶.

Some complications reported from the use of fillers (both HA and CaHA) include infection, ischemia, and necrosis due to vasospasm, intra-arterial injection, or extrinsic vascular compression in injections of large volumes at the tip or other

areas with little tissue distensibility, chronic pain, or formation of osteophytes by injection in the periosteum, or ischemia in the dermis and epidermis from very superficial injections².

OBJECTIVE

Our objective was to describe in detail an application technique of nasal fillers, taking into account safety aspects, and to present a comparison between various characteristics of CaHA and HA, expanding the vision of their properties to facilitate in choosing the most suitable filler for each case.

METHODS

A retrospective analysis was performed of all patients who attended the clinic between 2009 and 2012 seeking improvement of their appearances through rhinomodelation and who did not wish to undergo a rhinoplasty.

Patients with clinical diseases contraindicating general anesthesia; those with functional breathing alterations; those under 20 and over 60 years; those with known allergies to HA or CaHA; who previously underwent nose filling procedures, rhinoplasty surgery, or fixation threads in the nose, and those with changes in the nose with the indication of rhinoplasty surgery were excluded.

All patients signed an informed consent form, and the rhinomodelation product (HA or CaHA) was chosen according to the information provided during the consultation. A plastic surgeon performed the application of the product.

All patients were reassessed the day following the procedure and after 14 days, at which point the product was reapplied in cases that the surgeon or patient considered the initial nasal deformity to require additional correction.

Edema of the nasal tip was evaluated on the day after the procedure by the subjective opinion of the professional who performed the application, taking into account the intensity of skin erythema, the hardness of the treated area upon palpation, and the increase in the tip volume. The edema was evaluated on a scale from no edema to mild, moderate, or intense edema.

Pain was evaluated on the day following the procedure by the patient by slightly pressing the nasal tip with the finger pad of the index finger of the dominant hand and measuring the pain on a scale of 1 to 5 (1=no pain, 2 = mild pain, 3=moderate pain, 4=intense pain and 5=unbearable pain).

The degree of satisfaction with the results was evaluated after 2 weeks by the patient assessing the pre- and post-procedure photographs before any reapplication, and it was measured on a scale from 1 to 5 (1=very satisfied, 2=satisfied, 3=slightly satisfied, 4=dissatisfied and 5=totally dissatisfied, would not recommend and would not do it again).

Technique

After adequate antisepsis of the face with aqueous chlorhexidine, a topical anesthetic containing lidocaine 23% + tetracaine 7% gel was applied for 10 minutes, followed by the application of the dermal filler (CaHA or HA).

Application in the nasal spine: the syringe and needle were placed in direct orientation to the nasal spine joining the nasolabial angle (Figure 1).

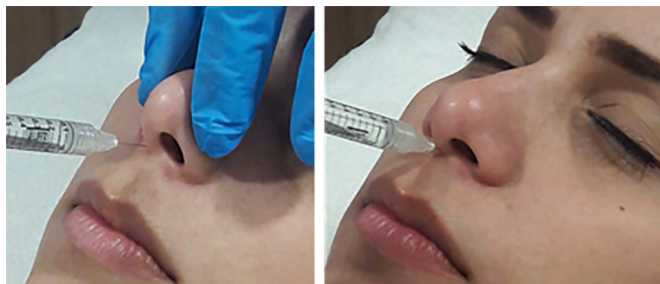

Figure 1. Application in the nasal spine.

Recommendations: This was used for cases with closed nasolabial angles (less than 95–100 degrees in women and 93–98 degrees in men⁷). When feeling

the bone with the tip of the needle, retreat 1–2 mm; aspirate to avoid an intra-arterial application and then delicately place the product, observing the opening of the nasolabial angle. This area does not need much digital modeling, but it requires compression to avoid ecchymosis.

Application in the columella: ingress from the base towards the nasal tip in the midline. The product is placed between the medial crus of each alar cartilage and the caudal septum (Figure 2).

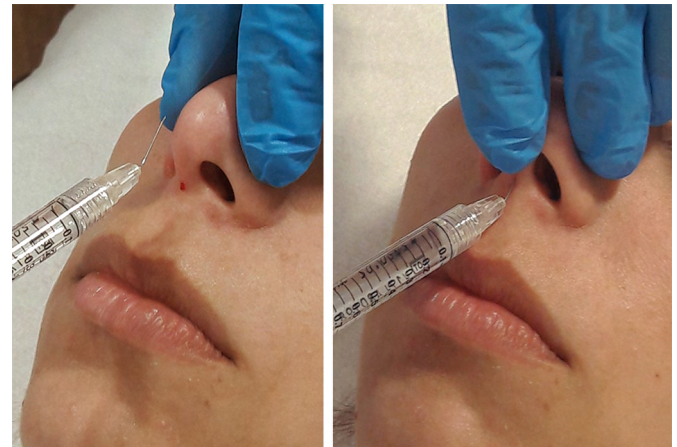

Figure 2. Application in the columella.

Recommendations: This was used for cases with an easily depressible tip and a weak columella. The needle is inserted at an angle of 45 degrees to facilitate its application. The syringe is aspirated and the application of the product is delicately done in a retrograde direction, repeating the application as many times as necessary to achieve the result. The volume is large enough to provide support to the columella but not to leave it large and irregular. The objective is analogous to a columellar strut to sustain the tip. Modelling and digital compression for one minute are necessary, raising the nasal tip cranially.

Application in the tip: The ingress is straight up to the interdomal space (Figure 3).

Recommendations: This is used for cases that are ill-defined, with a round tip and without projection. A straight needle is used to aspirate and delicately apply the material with low pressure in the retrograde direction. The color of the tissue is observed throughout the procedure, paying attention to any sign of ischemia (mottling, paleness, purplish coloration, reduction of temperature, or excessive redness). Immediate modeling and digital compression for one minute are necessary, providing shape and finesse to the tip, seeking to shape the product in such a way as to produce a triangular or diamond shape to the nasal tip.

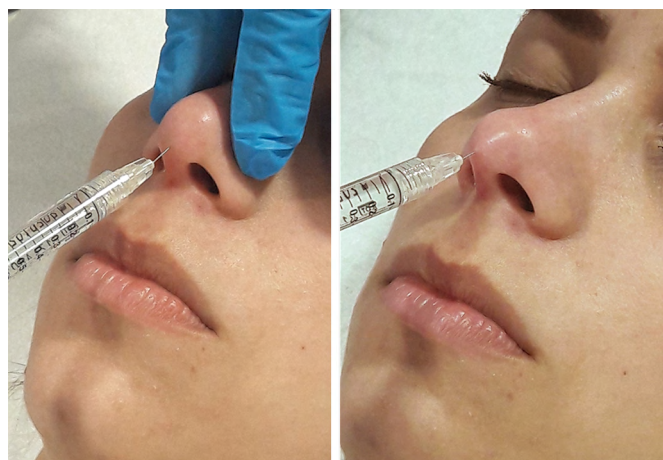

Figure 3. Application in the tip.

Application in the dorsum: the ingress is straight up to the supraperiosteal space of the nasal bone in the cranial direction (Figure 4).

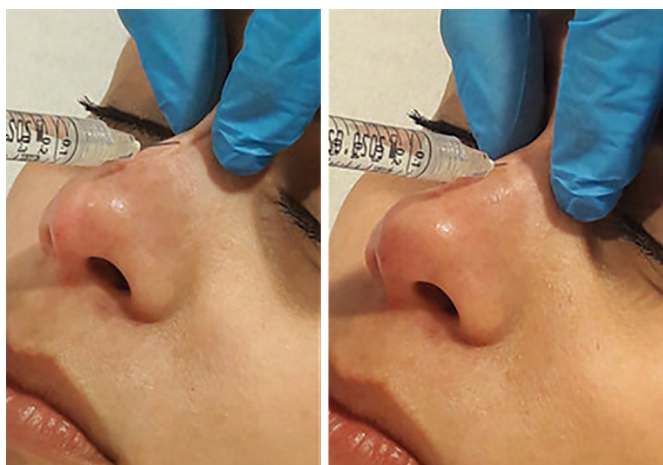

Figure 4. Application in the dorsum.

Recommendations: This is used for cases with irregularities or depressions on the dorsum. Needle ingress is held at an angle of 30 degrees to aspirate and delicately apply the material, spreading the product symmetrically with the help of the other hand. Lifting the skin and pinching it helps to find the correct plane. Superficial application is avoided in order to not provoke the Tyndall effect in the skin, and scraping the needle in the periosteum is avoided to prevent pain or periosteal reaction. Immediate digital modeling and delicate compression for one minute are necessary.

After the application, skin-colored paper tape is placed over the nose in the shape of a usual rhinoplasty until the following day.

RESULTS

Forty-two patients seeking nasal filling and who met the selection criteria were evaluated; 2 patients

were excluded (they did not return for the 14 day evaluation). One patient had signs of hypoperfusion when hyaluronic acid was applied in the nasal tip (skin pallor), so hyaluronidase was used, providing a satisfactory evaluation the next day. This was considered a complication, but it was not included in the analysis due to variations that it would cause in the evaluation of the results. A total of 39 patients were included in this study. Patient characteristics are summarized in Table 1.

Table 1. Patient Characteristics.

Characteristics	No. of patients	%
Patients included in the study.	39	100
Women	33	85
Men	6	15
Age 20–40 years	30	77
Age 40–60 years	9	23
Rhinomodulation with HA	27	69
Rhinomodulation with CaHA	12	31
Complications with hypoperfusion (HA)	1	-

HA: Hyaluronic Acid; CaHa: Calcium Hydroxyapatite.

The results evaluated the following day and at 14 days are summarized in Table 2 and Figures 5–12.

Table 2. Results.

Characteristics evaluated	HA (N: 27)	CaHA (N: 12)
Edema		
Without edema	0	0
Mild edema	14 (52%)	4 (33%)
Moderate edema	13 (48)	8 (67%)
Moderate edema	0	0
Pain		
Without pain	0	0
Mild pain	20 (74%)	4 (33%)
Moderate pain	7 (26%)	6 (50%)
Intense pain	0	2 (17%)
Unbearable pain	0	0
Degree of satisfaction (at 14 days)		
Very satisfied	4 (15%)	10 (84%)
Satisfied	20 (74%)	0
Not very satisfied	3 (11%)	2 (16%)
Dissatisfied	0	0
Totally dissatisfied, would not recommend, and would not do it again	0	0
Reapplication of the product	24 (89%)	2 (17%)

HA: Hyaluronic Acid; CaHa: Calcium Hydroxyapatite.

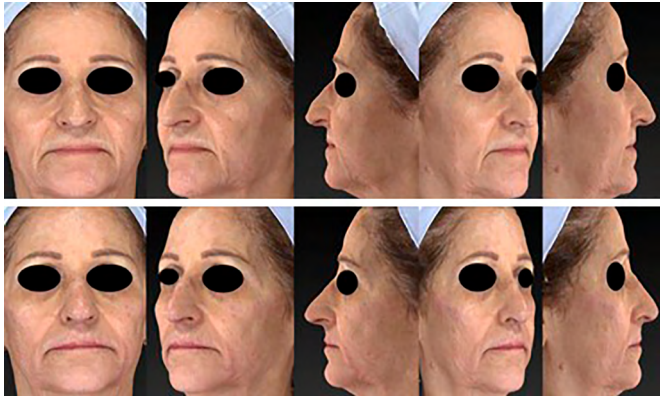

Figure 5. Frontal, oblique, and side aspects. Top line: Before. Bottom line: After. Before and after 2 weeks of rhinomodelation with HA in the nasal spine, columella and tip of the dorsum.

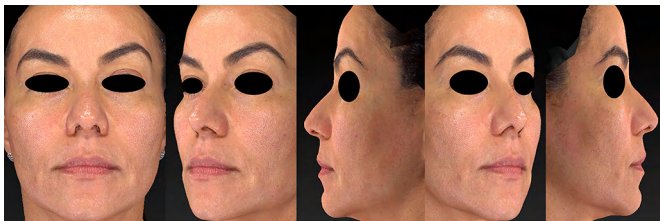

Figure 6. Frontal, oblique, and side aspects. Top line: Before. Bottom line: After HA. Before and after 2 weeks of rhinomodelation with HA in the nasal spine, columella, and tip of the dorsum.

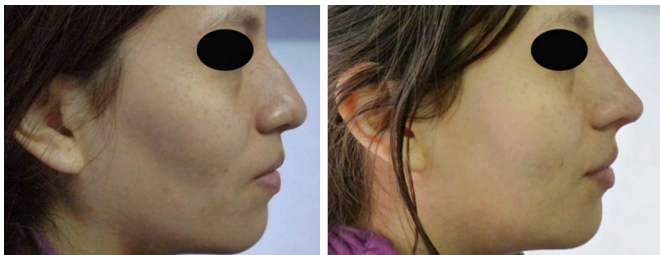

Figure 7. Pre-procedure and immediate result of rhinomodelation with CaHa in the nasal spine, columella, nasal tip and dorsum.

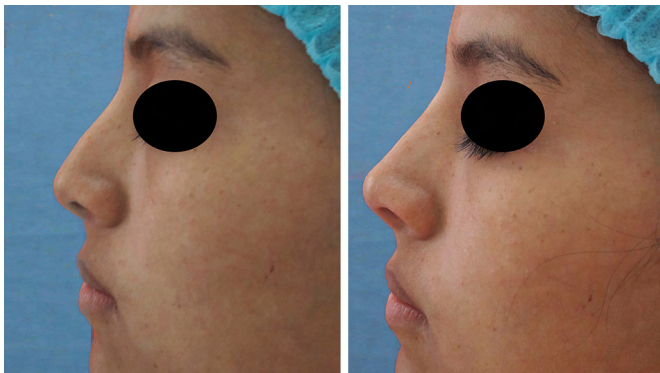


Figure 8. Pre-procedure and immediate result of rhinomodelation with CaHa in the nasal spine, columella, nasal tip and dorsum.

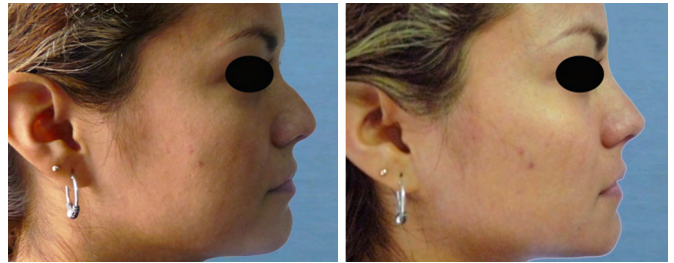


Figure 9. Pre-procedure and immediate result of rhinomodelation with CaHa in the nasal spine, columella, nasal tip, and dorsum

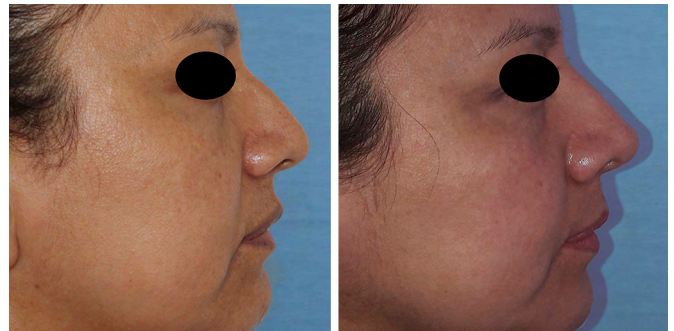


Figure 10. Pre-procedure and at 14 days after rhinomodelation with HA in the columella, nasal tip, and dorsum.

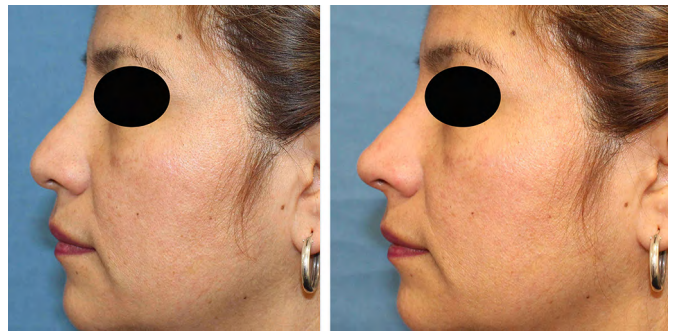

Figure 11. Pre-procedure and immediate result of rhinomodelation with HA in the nasal spine, columella, nasal tip, and dorsum.

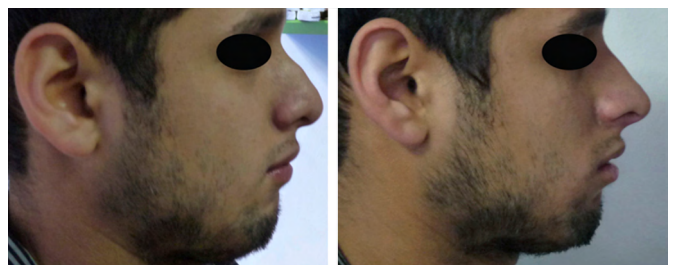

Figure 12. Pre-procedure and immediate result of rhinomodelation with CaHa in the nasal spine, columella, nasal tip, and dorsum.

Patients who were not very satisfied with the HA reported little change in the results. Patients who were not very satisfied with the CaHA reported discomfort due to edema and pain in the nose.

DISCUSSION

Discrete volumetric variations in the frontonasal angle, nasal dorsum, and nasolabial angle lead to significant differences in our perception of nasal esthetics².

With respect to rhinodelation, several factors must be considered before choosing the product. Two of the most important characteristics of these products to be considered are elasticity (ability to resist deformation) and viscosity (ability to resist applied force preventing propagation) of the product⁸. Therefore, a filler with high elasticity and viscosity provides greater support while using a smaller volume⁹.

On the tissue application plane, we recommend the supraperiosteal use of CaHA and HA in the subcutaneous tissue or deep dermis of all other nasal areas that can be corrected, such as the dorsum, tip, columella, and nasolabial angle¹⁰. Regarding the durability of the product, the literature shows a lifespan of 6–30 months in patients treated with CaHA¹¹. As for the use of other products as a complement, we recommend the use of botulinum toxin type A (12U) in all cases that present hyperactivity of the depressor muscle of the septum¹².

Although most researchers do not staunchly prefer one or the other, HA has become the most commonly used filler due to the safety offered by hyaluronidase, an enzyme that allows a certain degree of reversibility to the action of HA¹³. In cases with signs of poor perfusion, the application of HA should be stopped, the area kneaded, and hyaluronidase injected (10 units per each 0.1 ml of HA injected). The use of antiplatelets, peripheral vasodilators, or hyperbaric oxygen can also be useful⁶.

In our study, we found that HA led to a higher incidence of edema and mild pain, while CaHA led to a higher percentage of edema and moderate and intense pain on the day following the procedure. The necessity of reapplication in 2 weeks was less frequent with the use of the CaHA, which is in agreement with the literature^{8,14-15}. Both products presented a high degree of satisfaction with the esthetic results.

Some limitations of this study include the limited number of patients, the subjective evaluation by a single professional of the edema, the non-evaluation of the durability of each product, the short follow-up period (2 weeks), and the fact that possible differences between different brands of both products were not assessed.

CONCLUSIONS

Rhinodelation with resorbable fillers is a simple procedure with acceptable esthetic results in selected cases, and a deep anatomical knowledge is necessary to decrease the risk of complications.

COLLABORATIONS

RMR	Analysis and/or data interpretation, Data Curation, Final manuscript approval, Investigation, Methodology, Writing - Review & Editing
HEB	Writing - Review & Editing
PSP	Final manuscript approval, Methodology, Writing - Original Draft Preparation, Writing - Review & Editing
ES	Analysis and/or data interpretation, Conception and design study, Data Curation, Final manuscript approval, Supervision

REFERENCES

- Lin G, Lawson W. Complications using grafts and implants in rhinoplasty. *Operative Techniques in Otolaryngology-Head and Neck Surgery*. 2007;18(4):315-323.
- Bray D, Hopkins C, Roberts DN. Injection rhinoplasty: Non-surgical nasal augmentation and correction of post-rhinoplasty contour asymmetries with hyaluronic acid: How we do it. *Clin Otolaryngol*. 2010 Jun;35(3):227-230.
- Kontis TC, Rivkin A. The history of injectable facial fillers. *Facial Plast Surg*. 2009 May;25(2):67-72.
- Rivkin A, Soliemanzadeh P. Nonsurgical injection rhinoplasty with calcium hydroxyapatite in a carrier gel Radiesse: A 4-year retrospective clinical review. *Cosmet Dermatology*. 2009;22:619-624.
- Stupak H, Moulthrop TH, Wheatley P, Tauman AV, Johnson Junior CM. Calcium hydroxylapatite gel (Radiesse) injection for the correction of post-rhinoplasty contour deficiencies and asymmetries. *Arch Facial Plast Surg*. 2007 Mar/Apr;9(2):130-136.
- Kurkjian TJ, Ahmad J, Rohrich RJ. Soft-tissue fillers in rhinoplasty. *Plast Reconstr Surg*. 2014 Feb;133(2):121e-6e.
- Armijo BS, Brown M, Guyuron B. Defining the ideal nasolabial angle. *Plast Reconstr Surg*. 2012;129(3):759-64.
- Jasin ME. Nonsurgical rhinoplasty using dermal fillers. *Facial Plast Surg Clin North Am*. 2013 May;21(2):241-252.
- Sundaram H, Voigts B, Beer K, Meland M. Comparison of the rheological properties of viscosity and elasticity in two categories of soft tissue fillers: Calcium hydroxyapatite and hyaluronic acid. *Dermatol Surg*. 2010 Nov;36(Suppl 3):1859-1865.
- Helmy Y. Non-surgical rhinoplasty using fillers, Botox and thread remodeling: Retro analysis of 332 cases. *J Cosmet Laser Ther*. 2018 Oct;20(5):293-300.
- Schuster B. Injection rhinoplasty with hyaluronic acid and calcium hydroxyapatite: A retrospective survey investigating outcome and complication rates. *Facial Plast Surg*. 2015 Jun;31(3):301-7.
- Redaelli A. Medical rhinoplasty with hyaluronic acid and botulinum toxin A: A very simple and quite effective technique. *J Cosmet Dermatol*. 2008 Sep;7(3):210-20.
- Kim DW, Yoon ES, Ji YH, Park SH, Lee BI, Dhong ES. Vascular complications of hyaluronic acid fillers and the role of hyaluronidase in management. *J Plast Reconstr Aesthet Surg*. 2011 Dec;64(12):1590-5.
- Becker H. Nasal augmentation with calcium hydroxyapatite in a carrier-based gel. *Plast Reconstr Surg*. 2008 Jun;121(6):2142-7.
- Rokhsar C, Ciocon DH. Nonsurgical rhinoplasty: An evaluation of injectable calcium hydroxylapatite filler for nasal contouring. *Dermatol Surg*. 2008 Jul;34(7):944-6.

*Corresponding author:

Renato Matta Ramos

Be-You Medical Spa, Calle Libertadores, 125, San Isidro, Lima, Perú.

Zip code: 15073

E-mail: renatomatta82@hotmail.com