











Scalp reconstruction with large dorsal muscle-free flap after dog bite scalping

Reconstrução de couro cabeludo com retalho livre de músculo grande dorsal após escalpelamento por mordida de cachorro

DANIEL NOWICKI KAAM ^{1*} 
ANDRÉ COELHO NEPOMUCENO ^{1,2} 
GABRIEL DINIZ NISHIMURA ² 
FERNANDO GIOVANETTI MORANO ¹ 
JULIANO PEREIRA ¹ 
JULIANA GULELMO STAUT ¹ 
JOSE CARLOS MARQUES DE FARIA ² 
RODRIGO PINTO GIMENEZ ¹ 

■ ABSTRACT

Introduction: Scalping is characterized by trauma in the scalp region, which can be classified as partial or total. Scalping trauma is extremely mutilating and stigmatizing, especially when exposing the bone without periosteum, leading to chronic osteomyelitis and external table erosion. When there are extensive scalp lesions above 200cm², and with periosteum, the lesion is required a large amount of tissue with microsurgical flap, which is not available in all centers. This work aims to report a case of a 69-year-old female patient who suffered trauma due to total avulsion of a big scalp of 550cm² with exposure of a skull cap without periosteum and total unviability of the scalp after a dog bite. Due to the total unviability of the avulsed scalp, we opted to transplant a large dorsal muscle free flap with microvascular anastomosis of the thoracodorsal pedicle with the superficial temporal vessels. The flap evolved with good perfusion, and partial grafting was performed in the bloody area. **Methods:** Retrospective analysis of the medical records of the patient in question. This paper follows the Declaration of Helsinki's standards and the approval of the Ethics and Research Committee. **Conclusion:** The free flap of the large dorsal muscle proved effective in this case of reconstruction of the scalp's extensive lesion (550cm²) with partial periosteum lesion due to scalping. The flap recovered the shape of the skull and the protective function of the skull cap.

Keywords: Plastic surgery; Microsurgery; Scalp; Myocutaneous flap; Injuries and injuries.

Institution: Plastic Surgery Service Prof. Dr.
Ricardo Baroudi, Campinas, SP, Brazil.

Article received: July 3, 2020.
Article accepted: July 23, 2020.

Conflicts of interest: none

DOI: 10.5935/2177-1235.2021RBCP0025

¹ Plastic Surgery Service Prof. Dr. Ricardo Baroudi, Plastic Surgery, Campinas, SP, Brazil.

² Pontifical Catholic University of Campinas, Campinas, SP, Brazil.

■ RESUMO

Introdução: O escalpelamento é caracterizado pelo trauma em região do couro cabeludo, que pode ser classificado como parcial ou total. O trauma por escalpelamento é extremamente mutilante e estigmatizante, principalmente quando expõe o osso sem periósteo, que pode levar a quadro de osteomielite crônica e erosão de tábua externa. Quando há lesões extensas de couro cabeludo acima de 200cm² e com lesão de periósteo é necessária grande quantidade de tecido com retalho microcirúrgico, que não está disponível em todos os centros. O objetivo deste trabalho é relatar caso de paciente de 69 anos, feminina, que sofreu trauma por avulsão total de couro cabeludo de grande extensão de 550cm² com exposição de calota craniana sem periósteo e inviabilização total do escalpe após mordida de cachorro. Devido à inviabilização total do escalpe avulsionado, optou-se pelo transplante de retalho livre de músculo grande dorsal com anastomose microvascular do pedículo toracodorsal com os vasos temporais superficiais. O retalho evoluiu com boa perfusão e na área cruenta foi realizado enxertia parcial. **Métodos:** Análise retrospectiva de prontuário da paciente em questão. O presente trabalho segue os padrões de declaração de Helsinque e aprovação do comitê de ética e pesquisa. **Conclusão:** O retalho livre de músculo grande dorsal mostrou-se eficaz neste caso de reconstrução de lesão extensa do couro cabeludo (550cm²) com lesão parcial de periósteo devido ao escalpelamento. O retalho recuperou a forma do crânio e a função de proteção da calota craniana.

Descritores: Cirurgia plástica; Microcirurgia; Couro cabeludo; Retalho miocutâneo; Ferimentos e lesões.

INTRODUCTION

The presence of extended defects in the scalp presents itself as a major reconstructive challenge for the plastic surgeon^{1,2}. These defects have a wide etiology, such as traumatic, thermal or electrical burns, benign and malignant or congenital tumor resections, sequelae of radiotherapy treatments and infections. Deformities can range from small defects, which can be closed primarily, to extensive defects, which require tissue expansion or even free flap transfer for closure.

Scalping is trauma caused by partial or total avulsion of the scalp, resulting from canine bites, accidents with industrial machinery and boat engines^{3,4}.

The accident imposes physical sequelae and intense psychological and social suffering throughout the treatment and throughout the patients' lives, since it causes significant damage to self-esteem, identity, body perception, mood, sociability, and global affective relationships besides contributing to change the dynamics and family economy⁵.

The most serious injuries are caused by electrical burn^{5,6}. The bone table is often impaired in these lesions, leading to necrosis of one or both tables of the calvary⁷⁻¹⁰. The scalping caused by canine biting or some industrial machinery usually preserves the external bone table, but in most cases, compromises the periosteum¹¹. Extensive and complex defects involving exposed vital structures are not repairable by local or regional techniques. In these difficult cases, free tissue transfer is the best solution for coverage. Flap survival rates above 95% with low complication rates have been described¹.

This study aims to report a case of microsurgical reconstruction with a large dorsal muscle-free flap due to total scalping per dog bite in a 69-year-old female patient.

CASE REPORT

Female, white, 69-year-old hypertensive patient, victim of scalping by a dog bite, on 12/03/2018, in which the scalp tissue was totally devitalized with loss of tissue anatomy. She was sent to Santa Casa de Limeira when the debridement of devitalized tissues was performed

under general anesthesia and later transferred to the hospital of PUC-Campinas for plastic surgery evaluation and conduct.

On physical examination, the patient presented with an extensive scalp lesion with an area of 550 cm² (frontal-occipital: 25 cm and biparietal: 22 cm), with exposure of the skull cap with 50% of the periosteum area involved in the central parietal region (Figure 1). On December 11, 2018, the right great dorsal musculocutaneous flap was transplanted with end-to-end microvascular anastomosis between the right superficial temporal artery and the thoracodorsal artery and, subsequently. Subsequently, the end-to-end microanastomosis was performed between the right superficial temporal vein and the thoracodorsal vein with the flap's good tissue perfusion. Before vascular microanastomosis, both the pedicle vessels and the recipient's vessels were washed with 20 ml of 0.9% saline solution (250 ml) with unfractionated heparin (2.5 ml). Both vascular anastomoses were end-to-end type and made with simple stitches of 10.0 nylon thread (Ethicon W.2850). The temporal vein offered greater technical difficulty, as it was shorter due to the trauma. In the postoperative period, the patient used 20 mg subcutaneous clexane once daily for three days and 200 mg acetylsalicylic acid orally once daily for 30 days.

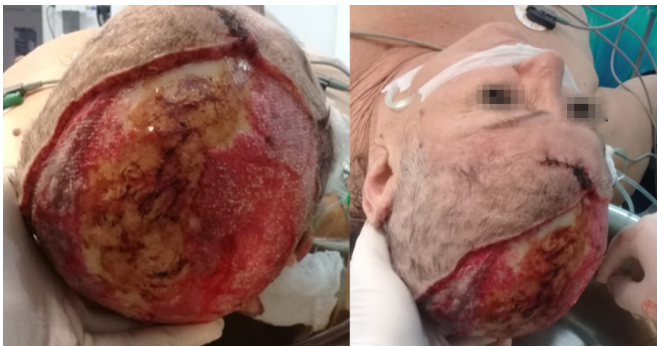

Figure 1. Preoperative: Extensive scalping with an area of 550cm² and periosteum lesion

Concomitantly with the fixation of the muscular part of the large dorsal flap at the edges of the residual scalp, a partial skin graft of the left thigh was obtained with Blair knife for grafting into the muscle bed of the flap, along with the simultaneous closure of the donor area of the right dorsal large flap, which occurred with several points of attachment of Vicryl 2.0 and tubular suction drain number 4.8. The surgery lasted a total time of 6 hours and 35 minutes. The patient progressed well in the postoperative period and without complications, hospitalized in the ICU for two days, for rigorous hemodynamic monitoring, and another three days in the ward. After one month of surgery, the first photos were documented (Figure 2).

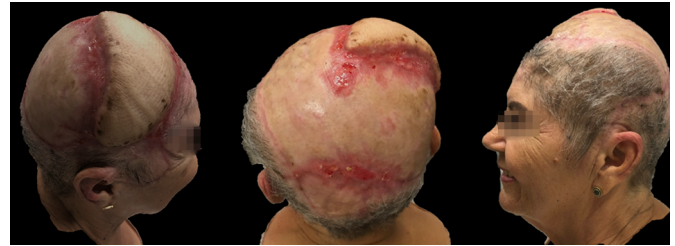

Figure 2. Postoperative 1 month

After six months, the patient underwent a new surgery under general anesthesia for flap slimming, thus providing a better aesthetic contour of the flap on the scalp (Figures 3 and 4).

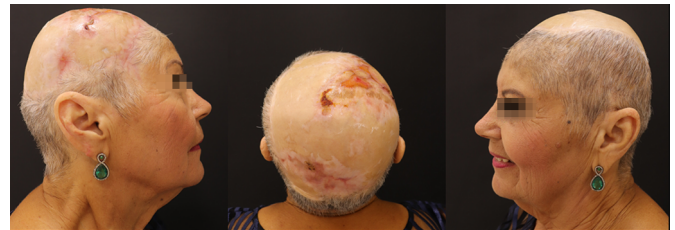

Figure 3. Postoperative period of 6 months after flap weight loss

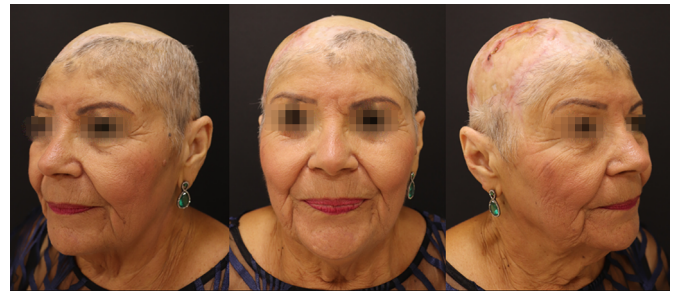

Figure 4. Postoperative period of 6 months after flap weight loss

The current methodology was the retrospective analysis of the medical records of the patient in question. The present work follows the standards of Helsinki's declaration and the ethics and research committee's approval under number 2486.

DISCUSSION

In this case report, the patient presented extensive loss of scalp (550cm²) with a partial lesion of the periosteum in the central parietal part, thus making it impossible to make grafting on a skull cap and local flaps. The exposed skull cap without periosteum, even with daily dressings, is a common source of chronic osteomyelitis and erosion of the external table, making it necessary to cover the wound with a muscle flap to bring perfusion to this previously devitalized area. The muscle flap has the advantage over the skin flap due to its higher capillary density. Furthermore, the

muscle with pedicle parallel to its axis is preferable to the perforating flap due to its vessels' better accommodation against the skull cap¹⁻¹³.

As in this case, large avulsions and total avulsions of the scalp, undoubtedly the best results are achieved through immediate microsurgical reimplantation. For reimplantations, there is a need to preserve at least one main vascular pedicle¹². However, the patient's avulsed scalp was totally unfeasible by the dog's bite in the present case, making it impossible.

Beasley et al., in 2004¹³, propose a staging system for the selection of the type of flap to be used for reconstruction, based on the etiology and size of the defect, previous treatment and future treatment planning. For scalp defects, they suggest: smaller than 200cm² can be closed primarily or with local flaps; for smaller under 200 cm² associated with severe trauma, osteomyelitis or osteoradionecrosis, previous radiation, previous local flap and postoperative radiotherapy plan recommend muscle flaps free from the abdominal rectum or latissimus dorsi with cutaneous graft; muscle flaps free of latissimus dorsi with skin graft are used; in those over 600 cm², the combination of two latissimus muscle flaps free from the dorsum with a skin graft should be used¹⁻¹³.

The latissimus muscle of the back associated with the skin graft is currently the flap of choice for scalp reconstruction, whose reimplantation is not feasible¹². The thoracodorsal vascular pedicle measured approximately 8.5cm. The arterial diameter is approximately 2.5 mm, permeates the muscle with dimensions of approximately 25x35cm and can be dissected with a cutaneous island of 10x22cm, infused by perforating vessels, allowing the primary closure of the donor area. For scalp wounds, the length of the thoracodorsal pedicle allows anastomosis in both superficial and cervical vessels.

The intermuscular blood supply of the latissimus of the back allows the muscle to be divided into distinct muscle flaps to cover complex three-dimensional defects. If a larger amount of tissue is required, the serratus muscle and the scapular flap can be added to the vascular pedicle¹⁻¹³. In this case, a musculocutaneous flap was used, in which the cutaneous part of the patient had the function of perfusion coverage and monitoring of the flap and the muscle part as an excellent vascularized receptor bed for partial grafting.

The head and neck region has an extensive bilateral vascular network, easily accessible for free tissue transfer. The preferred receptor vessel in the upper third of the face is the superficial temporal artery and vein. If this vessel is not available, lower branches of the external carotid system (facial, upper thyroid and transverse cervical) can be used^{1,12}.

Among the most frequent complications of this type of procedure are total or partial necrosis of the flap, non-integration of the cutaneous graft and seromas in the donor area (large dorsal muscle). In the series of Ioannides et al., in 1999¹¹, in which 31 patients with scalp defects treated with free flaps were reported, there was a loss of only one (3.2%) free flap of large dorsal muscle, due to venous congestion, being within acceptable limits of 6.6% for this area of the body reported by Kroll et al., in 1996¹⁴. There was only a small partial loss of the skin graft, with no major complications in the present case.

Multiple methods have been described to refine scalp reconstruction, including serial excision, local flap transposition, tissue expansion and follicular micrografts in muscle flaps with skin grafts¹².

Scalp reconstruction with a large dorsal muscle-free flap can reestablish the skull cap's cover with sufficient perfusion to nourish the outer table and prevent or treat any subclinical infection. The form is also restored satisfactorily. The limitation is due to the area of alopecia, which can be circumvented by employing hair prosthesis ("wigs") or adornments such as scarves. In this case, the transplantation of hair follicle units or tissue expansion would not be a good option since the residual area with hair is very scarce, and most of the flap was composed of muscle with skin graft and scar areas.

As the patient is satisfied, using scarves and hair prosthesis, no more surgical complements were proposed at the moment. The patient, who is a hairdresser by profession, went through the trauma of scalp avulsion and reported having refound her self-esteem after reconstructive plastic surgery.

CONCLUSION

The free flap of the large dorsal muscle effectively reconstructed extensive scalp lesions with 550cm² and partial periosteum lesions due to scalping. The flap recovered the shape of the skull and the protective function of the skull cap.

COLLABORATIONS

DNK

Analysis and/or data interpretation, Conception and design study, Conceptualization, Data Curation, Final manuscript approval, Formal Analysis, Funding Acquisition, Investigation, Methodology, Project Administration, Realization of operations and/or trials, Supervision, Validation, Writing - Original Draft Preparation, Writing - Review & Editing

| | |
|-------------|--|
| ACN | Analysis and/or data interpretation, Conception and design study, Conceptualization, Formal Analysis, Methodology, Realization of operations and/or trials, Supervision, Visualization, Writing - Review & Editing |
| GDN | Conceptualization, Formal Analysis, Investigation, Methodology |
| FGM | Investigation, Supervision, Visualization |
| JP | Supervision |
| JGS | Supervision |
| JCMF | Realization of operations and/or trials |
| RPG | Investigation, Supervision, Visualization |

REFERENCES

1. Neligan PC. *Cirurgia plástica: princípios*. 3a ed. Rio de Janeiro: Elsevier; 2015.
2. Cunha CB, Sacramento RMM, Maia BP, Marinho RP, Ferreira HL, Goldenberg DC, et al. Perfil epidemiológico de pacientes vítimas de escarpelamento tratados na Fundação Santa Casa de Misericórdia do Pará. *Rev Bras Cir Plást*. 2012 Mar;27(1):3-8. DOI: <http://dx.doi.org/10.1590/S1983-51752012000100003>
3. Van Driel AA, Mureau MA, Goldstein DP, Gilbert RW, Irish JC, Gullane PJ, et al. Aesthetic and oncologic outcome after microsurgical reconstruction of complex scalp and forehead defects after malignant tumor resection: an algorithm for treatment. *Plast Reconstr Surg*. 2010 Ago;126(2):460-70.
4. Lutz BS, Wei FC, Chen HC, Lin CH, Wei CY. Reconstruction of scalp defects with free flaps in 30 cases. *Br J Plast Surg*. 1998 Abr;51(3):186-90.
5. Ribeiro NS. Necessidade e dilemas das famílias vítimas de escarpelamento atendidas na FSCMP: desafios para o serviço social [dissertação]. Belém: Universidade Federal do Pará (UFPA); 2009.
6. Newman MI, Hanasono MM, Disa JJ, Cordeiro PG, Mehrara BJ. Scalp reconstruction: a 15-year experience. *Ann Plast Surg*. 2004 Mai;52(5):501-6.
7. Spies M, McCauley RL, Mudge BP, Herndon DN. Management of acute calvarial burns in children. *J Trauma*. 2003;54(4):765-9.
8. Hartford CE. Preservation of devitalized calvarium following high-voltage electrical injury: case reports. *J Trauma*. 1989 Mar;29(3):391-4.
9. Dalay C, Kesiktas E, Yavuz M, Ozerdem G, Acarturk S. Coverage of scalp defects following contact electrical burns to the head: a clinical series. *Burns*. 2006 Mar;32(2):201-7.
10. Wright HR, Drake DB, Gear AJ, Wheeler JC, Edlich RF. Industrial high-voltage electrical burn of the skull, a preventable injury. *J Emerg Med*. 1997 Jun;15(3):345-9.
11. Ioannides C, Fossion E, McGrouther AD. Reconstruction for large defects of the scalp and cranium. *J Craniomaxillofac Surg*. 1999 Jun;27(3):145-52.
12. Mélega JM. *Cirurgia plástica: reconstrução de couro cabeludo e calota craniana*. Cap 66.
13. Beasley NJ, Gilbert RW, Gullane PJ, Brown DH, Irish JC, Neligan PC. Scalp and forehead reconstruction using free revascularized tissue transfer. *Arch Facial Plast Surg*. 2004 Jan/Fev;6(1):16-20.
14. Kroll SS, Schusterman MA, Reece GR, Miller MJ, Evans GR, Robb GL, et al. Choice of flap and incidence of free flap success. *Plast Reconstr Surg*. 1996 Set;98(3):459-63.

*Corresponding author:

Daniel Nowicki Kaam

Avenida Benjamin Constant, 1971, Apt 1603, Cambuí, Campinas, SP, Brazil.

Zip Code: 13025-005

E-mail: danielnkaam@gmail.com