



Abdominal liposuction: evolving from high to medium definition

Lipoaspiração abdominal: evoluindo de alta para média definição

ROGERIO SCHÜTZLER GOMES ^{1*} 
GABRIELA VALENTE NICOLAU ¹ 

Institution: Hospital Carlos Corrêa, Plastic Surgery Service, Florianópolis, SC, Brazil.

Article received: October 20, 2020.
Article accepted: January 10, 2021.

Conflicts of interest: none

DOI: 10.5935/2177-1235.2021RBCP0059

■ ABSTRACT

Introduction: Currently, the concept of high-definition liposuction (HDL or HD Lipo) is increasingly accepted. However, we noticed patients' search for results with not-so-vigorous marking, especially in the abdominal region, what we have called medium-definition liposuction or MD Lipo. This study aims to present a series of clinical cases performed by the MD Lipo technique, using the conventional liposuction method.

Methods: Retrospective study where patients underwent liposuction to obtain abdominal definition under the linea alba, semilunaris and tendinous intersections. We use cylindrical and malleable silicone tubes in the dressing. **Results:** One hundred and seven cases were included, of which 85 completed the 6-month follow-up. After 6 months, the results were considered good by all patients and medical staff. **Discussion:** The concept of HD Lipo is recent and has been receiving increasing acceptance. The search for more natural and smooth results led to developing the term medium or moderate definition liposuction (MD Lipo). We believe that every plastic surgeon can perform this additional abdominal definition finish with his preferred method of liposuction, either low energy (syringe, liposuction device and vibroliposuction device) or high energy (laser liposuction or ultrasonic liposuction). We can use silicone tubes to better adherence of the skin to aponeurosis and better define the grooves formed. **Conclusion:** The technique of medium definition abdominal liposuction (MD Lipo) has been described, using the conventional method of liposuction, in the alba and semilunaris lines and the tendinous intersections of the rectus abdominis muscle.

Keywords: Lipectomy; Bandages; Trends; Plastic surgery; Aesthetics.

¹ Hospital Carlos Corrêa, Plastic Surgery Service, Florianópolis, SC, Brazil.

■ ABSTRACT

Introduction: Currently the concept of high definition liposuction (HD Lipo) is increasing. However, we realize the patients' search for smoother and more natural results, especially in the abdominal region, what we have called medium definition liposuction or MD Lipo. The objective of this study is to present a series of clinical cases performed by the technique of MD Lipo, using conventional method of liposuction. **Methods:** Retrospective study in which patients were submitted to liposuction to obtain the abdominal definition, under linea Alba, linea semilunar and tendinous intersections, previously marked, until the formation of a visible groove in these places. We used cylindrical and malleable silicone tubes in dressings. **Results:** 107 cases were included, of which 85 completed the 6-month follow-up. After 6 months, the results were considered good by all patients and medical staff. **Discussion:** The concept of HD Lipo is recent and has received increasing acceptance. The search for more natural and smooth results, led to the development of the term MD Lipo. We believe that every plastic surgeon can perform abdominal definition, with his preferred method of liposuction, whether low energy (syringe, aspirator, and vibroliposuction), or high energy (Laser liposuction or Ultrasonic Liposuction), and can use silicone tubes for better adherence of the skin to the aponeurosis and better definition of the grooves. **Conclusion:** A medium definition abdominal liposuction technique (MD Lipo) was described, using the conventional method of liposuction, in the Alba and semilunar lines, as well as the tendon intersections of the rectus abdominis muscle.

Keywords: Lipectomy; Bandages; Trends; Surgery, Plastic; Aesthetic.

INTRODUCTION

According to ISAPS (International Society of Aesthetic Plastic Surgery) ¹, in 2018, liposuction was the second most performed surgical procedure among plastic surgeons, totaling 1,732,620 surgeries worldwide, representing a growth of 10 % concerning the previous survey, and 26% when compared to 2014, denoting the increase in procedures and visibility of this surgery.

Since the late 1980s, there has been an increase in anatomical interest in the subcutaneous tissue and its fascias². In this search, in 1988, Bozola and Psillakis³ described the abdominal shape similar to a lyre. In the same sense, in 1989, Avelar² observed the existence of areas of convexities and concavities, studies that inspired the later polishing of the human body contour, promoting results within a more natural aesthetic pattern.

With the advent of superficial liposuction, performed in the subdermal plane, described in the late 80⁴ and early

90⁵⁻⁷, other possibilities and indications arose that traditional liposuction, deep or subfascial, did not allow, such as removing fat from more superficial areas aiming to promote skin retraction, to reduce the indications for abdominoplasty⁵ drastically.

Combining the concepts, in 1993, Mentz et al.⁸ were the first to perform superficial liposuction to define the abdominal muscle lines, coining the term abdominal etching, in eight male patients of athletic size. In 1997, Ersek and Salisbury⁹ described superficial abdominal liposuction in 25 male cases.

In 2003, Hoyos et al.¹⁰, during the Colombian Congress of Plastic Surgery and later in a 2007 publication¹⁰, conceptualized a new type of liposuction: high definition liposculpture, HDL or HD Lipo, from the English term high definition. The described technique combined the concepts of superficial liposuction to obtain more robust results, refining the previous work⁸, associated with a global, three-dimensional and artistic body approach. For this, he pointed out differences between male and female patients, in which not only the abdomen and the back, arms and legs are

treated, recommending the use of the third-generation ultrasonic liposuction device Vaser®, to obtain better results¹¹.

However, nowadays, the tendency to define body contour has evolved to obtain smoother results. In our practice, we have observed since 2018¹² that most patients ask for HD Lipo, which is already widespread in society. However, they aim for results that are not so evident concerning the musculature marking, which has been more recently called medium or moderate definition liposuction, MD Lipo¹³ for short. In this line of reasoning, some classification proposals have emerged¹⁴⁻¹⁶.

The purpose of this study is to present a liposuction technique that meets the current desires of patients, which is easy for plastic surgeons to learn, using conventional liposuction material, accessible from an economic point of view, with satisfactory aesthetic results and a low incidence of complications.

OBJECTIVES

Describe superficial abdominal liposuction technique, with the definition of the alba and semilunaris lines and the tendinous intersections of the rectus abdominis muscle, using conventional liposuction material.

METHODS

The present study is a series of retrospective cases of patients undergoing MD Lipo in a private hospital in the city of Florianópolis, state of Santa Catarina, Brazil, from May 2018 to May 2019, with a minimum follow-up of 6 months. The study was submitted and authorized for publication by the hospital's medical ethics committee, and followed the Helsinki declaration rules and all patients signed an informed consent form, including authorization to publish images for academic purposes.

The inclusion criteria observed were the clinical picture of abdominal lipodystrophy assessed by the surgeon; body mass index less than 28; stable weight for at least 1 year; without prior abdominoplasty.

On the day of the surgery, with the patients in an orthostatic position, the alba, semilunaris lines and the tendinous intersections of the rectus abdominis muscle were marked (Figures 1 and 2).

All patients underwent the procedure under general anesthesia. The incisions were standardized with two 7mm orifices in the pubic region. Wet infiltration was used, with infiltrate ratio: 1:2 aspirate, or super wet, with infiltrate ratio: 1:1 aspirate, with saline solution associated with epinephrine concentration 1:500,000 and lidocaine at a concentration of 0.05%.

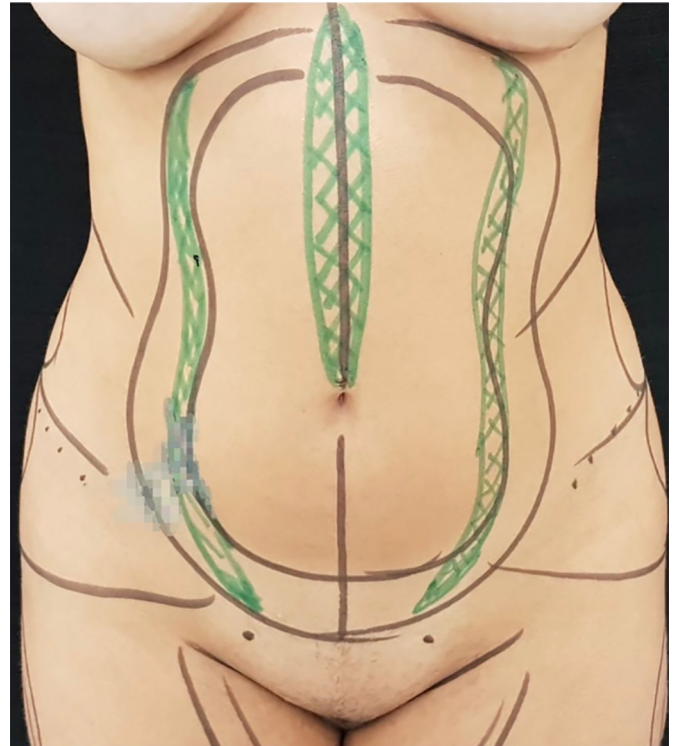


Figure 1. Immediate preoperative marking, female pattern. In black the areas of liposuction, in green the projections of the semilunaris lines and alba line.

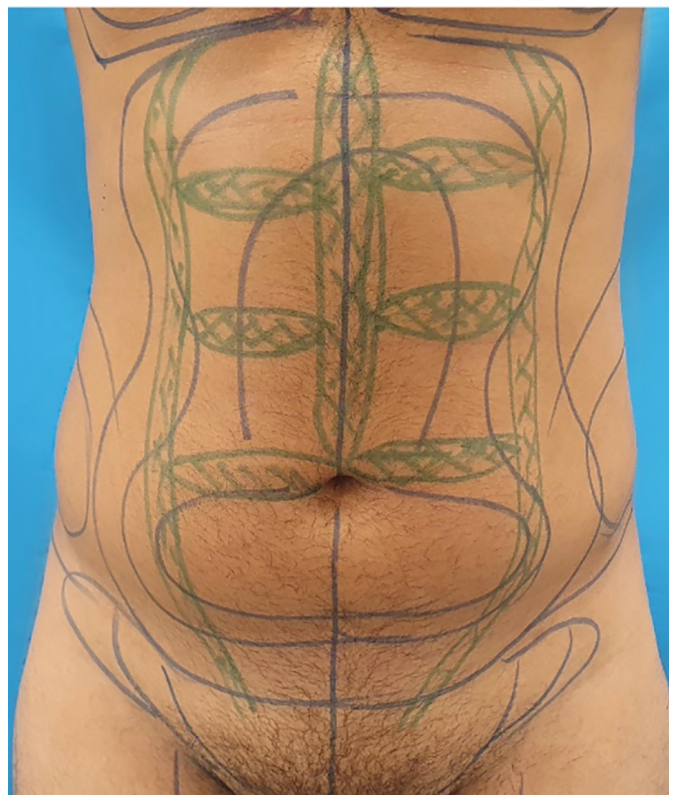


Figure 2. Immediate preoperative marking, male pattern. In blue the areas of liposuction; in green the projections of the semilunaris lines, alba line, and tendinous intersections of the rectus abdominis muscle. The latter, with slight misalignment to give a non-artificial appearance, more natural.

The liposuction was obtained with 60ml syringes and latches, with 4mm diameter cannulas, 5 Mercedes-type orifices, 30 and 35cm in length.

Fat removal was performed using a standardized abdominal liposuction technique, divided into type I, type II and type III (Figure 3), performed in this order:

Lipo type I: removal of fat from the deepest layer of subcutaneous cellular tissue (SCCT), or lamellar layer, below the fascia of Scarpa;

Lipo type II: performed in the areolar layer of the SCCT, above the fascia of Scarpa, preserving the most superficial region of the areolar layer;

Lipo type III: it is the definitive liposuction performed in the areolar layer even more superficial than the Lipo type II, closer to the deep dermis, under

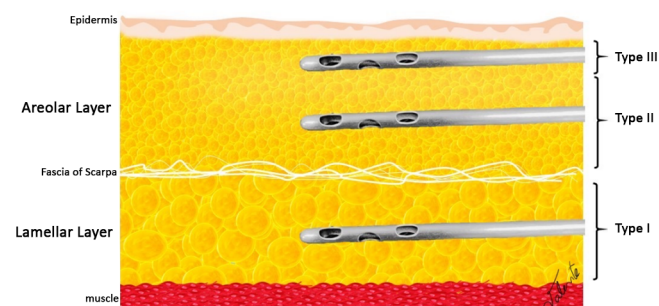


Figure 3. Standardization of liposuction: Lipo type I: removal of fat from the deepest layer of subcutaneous cellular tissue (SCCT), lamellar layer, below the fascia of Scarpa; Lipo type II: performed in the areolar layer of the SCCT, above the fascia of Scarpa, aiming at reducing the volume of this compartment, preserving the most superficial region of the areolar layer; Lipo type III: it is the liposuction of definition, performed in the areolar layer even more superficial than the Lipo type II, closer to the deep dermis, under the alba and semilunar lines.

the alba and semilunaris lines (Figure 1). The same surgical material and the same accesses are used, but aiming at the vigorous removal of fat, with the aid of the contralateral hand to grasp the tissue through which the cannula slid, alternating with compression and aspiration movements, until the formation of a visible groove in these places inspected by the surgeon with the clamping or pinch test maneuver, making sure that the cannula holes are not facing the dermis. In cases where the patient requested more definition of the tendinous intersections of the rectus abdominis muscle, 3 incisions were added in the line alba, of 3mm each, for superficial areolar type III liposuction also with cannulas of 4mm in diameter, until the formation of a groove in these locations (Figure 2).

All data referring to the volume withdrawn were recorded by region in milliliters, possible documentation due to the use of graduated syringes and accounting according to the document developed by the team (Figure 4).

Subsequently, the surgical incisions were closed with continuous polyglecaprone 4.0 (Monocryl®)

suture without the use of drains. Then, the dressings were performed as previously described¹², using 7mm diameter hollow malleable silicone tubes (Figure 5), positioned over the sinuous contour of the semilunaris line, as well as rectilinear positioning of the supraumbilical alba line (Figure 6) and on the tendinous intersections, in the cases in which they were addressed (Figures 7 and 8). Such tubes were fixed vertically with microporous tape, complementing with horizontal fixations over the entire abdominal extension (Figure 8). Additionally, rectangular foam with cotton lining was used throughout the trunk, over the silicone tubes, and maintained by the modeling strap.

The patients had their dressings maintained for 5 to 6 days when the silicone tubes were removed (Figure 9), and the foam was indicated for 15 days and the modeling strap for 30 days.

The patients had their dressings maintained for 5 to 6 days when the silicone tubes were removed (Figure 9), and the foam remained indicated for 15 days and the modeling belt for 30 days. The participants were followed up through consultations before and after the surgery on the 5th or 6th day, 21st to 28th day, and third and sixth months. The standardized photographic recording was performed with the Cannon SX30IS model in 4 steps. The first stage during the preoperative period, the second in the 3rd month and the third in the 6th month (Figures 10 to 16).

The complications investigated through clinical examination were seroma, ischemia, irregularity, infection, hyperchromia, unaesthetic scarring, late edema and need for reoperation.

RESULTS

One hundred seven patients were included. All cases were operated on by the same surgeon from May 2018 to May 2019, with follow-up of at least 6 months. Of these, 22 patients were excluded due to lack of follow-up after 6 months of surgery, with 85 patients remaining 10 (8.5%) men and 75 (91.5%) women, between 18-58, with mean, median and modal age of 37, 35 and 28 years old, respectively.

Of the remaining 85 patients, all underwent MD Lipo with the demarcation of the semilunaris and alba lines above the umbilical scar. Of these, 10 male patients and 1 female patient requested the addition of more evident demarcation at the tendinous intersections of the rectus abdominis muscle through additional incisions. Type III liposuction, of definition, added an average time of 20 minutes for alba and semilunaris lines and 30 minutes when also approaching tendinous intersections.

Region	Back Inf E	Back Sup E	Fat on hips E	Back Inf D	Back Sup D	Fat on hips D	Region	Abd Sup D	Abd Sup E	Abd Inf D	Abd In E	Thigh In E	Thigh In D	Arm D	Arm E
Infiltration							Infiltration								
1 st Syringe	1.	1.	1.	1.	1.	1.	1 st Syringe	1.	1.	1.	1.	1.	1.	1.	1.
2 nd Syringe	2.	2.	2.	2.	2.	2.	2 nd Syringe	2.	2.	2.	2.	2.	2.	2.	2.
sum							sum								
3 rd Syringe	3.	3.	3.	3.	3.	3.	3 rd Syringe	3.	3.	3.	3.	3.	3.	3.	3.
sum							sum								
4 th Syringe	4.	4.	4.	4.	4.	4.	4 th Syringe	4.	4.	4.	4.	4.	4.	4.	4.
sum							sum								
5 th Syringe	5.	5.	5.	5.	5.	5.	5 th Syringe	5.	5.	5.	5.	5.	5.	5.	5.
sum							sum								
6 th Syringe	6.	6.	6.	6.	6.	6.	6 th Syringe	6.	6.	6.	6.	6.	6.	6.	6.
sum							sum								
7 th Syringe	7.	7.	7.	7.	7.	7.	7 th Syringe	7.	7.	7.	7.	7.	7.	7.	7.
sum							sum								
8 th Syringe	8.	8.	8.	8.	8.	8.	8 th Syringe	8.	8.	8.	8.	8.	8.	8.	8.
sum							sum								
9 th Syringe	9.	9.	9.	9.	9.	9.	9 th Syringe	9.	9.	9.	9.	9.	9.	9.	9.
Soma							sum								
10 th Syringe	10.	10.	10.	10.	10.	10.	10 th Syringe	10.	10.	10.	10.	10.	10.	10.	10.
sum							Vol. Total								
11 th Syringe	11.	11.	11.	11.	11.	11.									
sum															
12 th Syringe	12.	12.	12.	12.	12.	12.									
sum															
13 th Syringe	13.	13.	13.	13.	13.	13.									
sum															
14 th Syringe	14.	14.	14.	14.	14.	14.									
sum															
15 th Syringe	15.	15.	15.	15.	15.	15.									
sum															
16 th Syringe	16.	16.	16.	16.	16.	16.									
sum															
17 th Syringe	17.	17.	17.	17.	17.	17.									
sum															
18 th Syringe	18.	18.	18.	18.	18.	18.									
sum															
19 th Syringe	19.	19.	19.	19.	19.	19.									
sum															
20 th Syringe	20.	20.	20.	20.	20.	20.									
sum															
21 st Syringe	21.	21.	21.	21.	21.	21.									
Vol. Total															

Region	MD SLD	MD SLE	MD LA	MD IT
Infiltration				
1 st Syringe	1.	1.	1.	1.
2 nd Syringe	2.	2.	2.	2.
sum				
3 rd Syringe	3.	3.	3.	3.
sum				
4 th Syringe	4.	4.	4.	4.
Vol. Total				

Graft	Method	Volume

Volume Total (ml)	
Infiltrated	
Grafted	
Liposuction	

Florianópolis, _____

LABEL

Figure 4. Table used in the transoperative period to control the volumes removed (in milliliters) from the liposuction areas and also from the abdominal definition areas. The use of liposuction with graduated syringes allows this objective evaluation, helping to water replacement, more accurate control of the volumes taken from each region, helping to obtain results closer to the ideal.




Figure 5. Silicone tubes, cylindrical and hollow, to better adapt to the abdominal definition lines, used for greater skin adhering to aponeurosis.

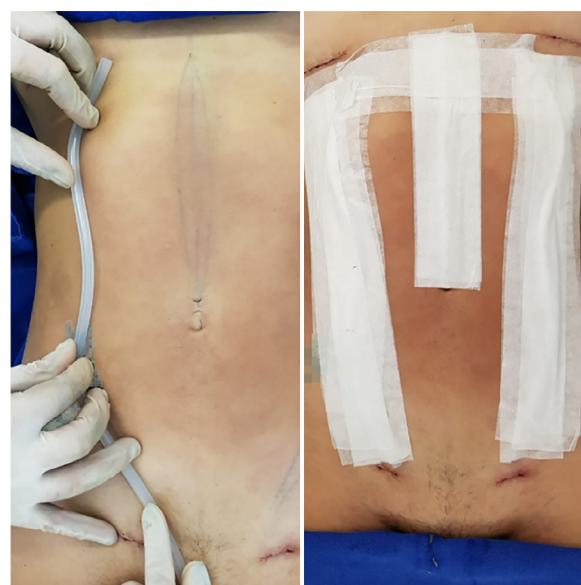


Figure 6. On the left, positioning the silicone tube on the semilunar line. On the right, silicone tubes positioned and fixed with micropore®, female pattern.

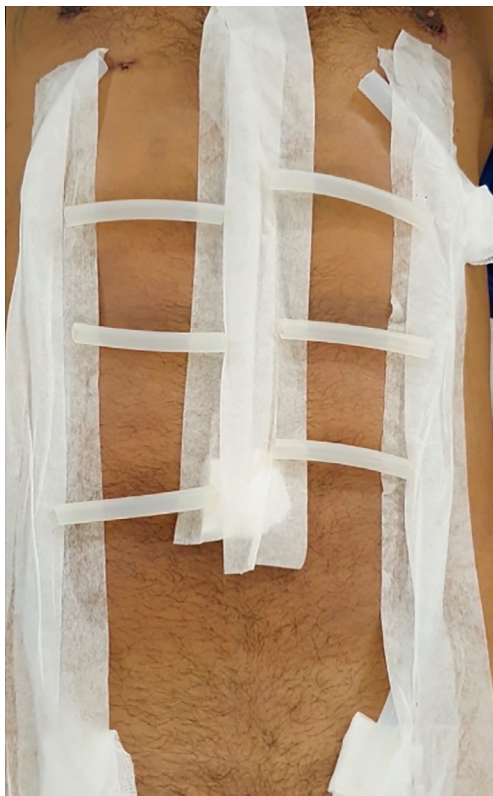

Figure 7. When defining the tendon intersections, we used the same silicone tubes positioned on these areas, slightly misaligned to give a more natural aspect.

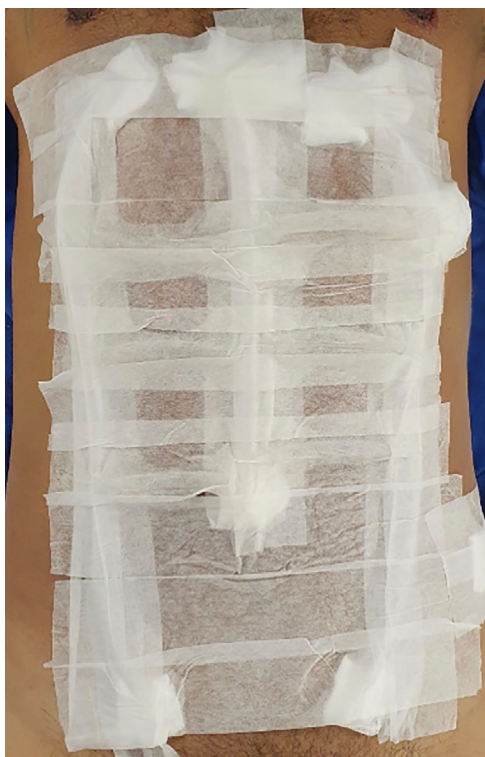

Figure 8. Final aspect of fixed silicone tubes, including tendon intersections. In the end, microporation was done on the entire abdominal region, performed in all cases.

The silicone tubes' marks were very evident on the first return (Figure 9), being more discreet in the subsequent consultation. There was mild discomfort of abdominal movement due to the presence of fixed tubes, considered tolerable by the patients. After 6 months, the results were considered good (Figures 10 to 16) by patients and medical staff by comparing photographs.

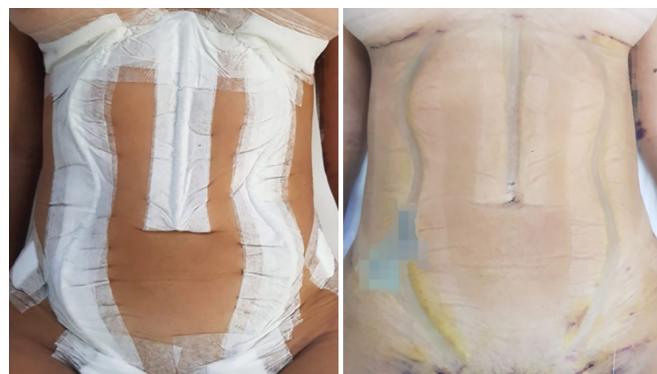

Figure 9. Aspect on the first return, with 5 to 6 days. On the left, with tubes and micropore® fixed. In the right, aspect after removal of the dressing, with well-pronounced definition grooves.

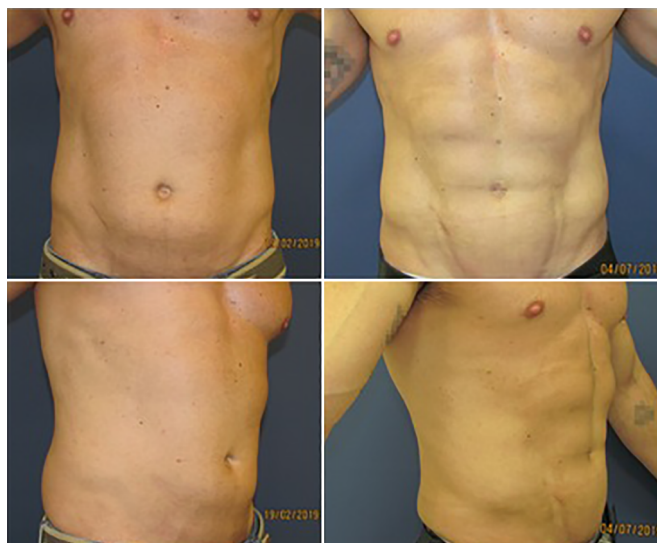

Figure 10. Male patient, 36 years old, practicing intense physical activity daily. Upper left, preoperative anterior view. Upper right, postoperative anterior view 6 months. Lower left, preoperative oblique view. Lower right, postoperative oblique view 6 months.

There was 1 case of seroma resolved with a puncture on the seventh post-operative day (5ml) and 2 cases of allergic dermatitis, which started two weeks after the surgery and ended with topical and systemic use of corticosteroids for one week. There was a case of unsightly adherence in the left semilunar line initially treated with a subcision to release the adherence, but which evolved with seroma, in turn, resolved after 3 punctures and, later, with lipografting.

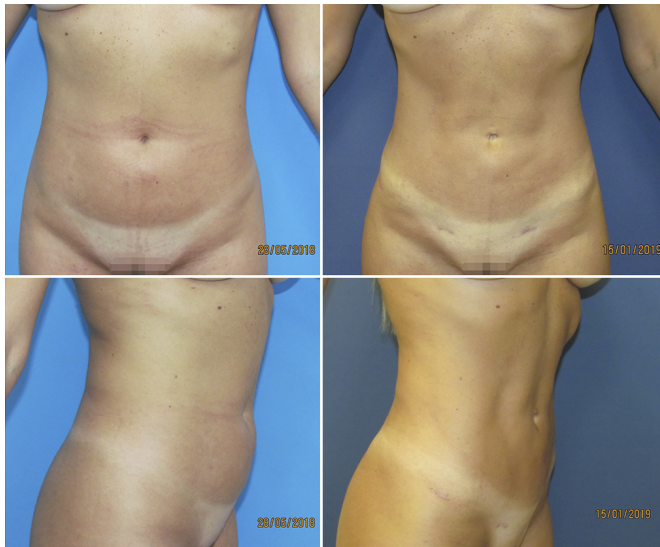


Figure 11. Female patient, 33 years old, practicing moderate physical activity 3 times a week. Upper left, preoperative anterior view. Upper right, postoperative anterior view 6 months. Lower left, preoperative oblique view. Lower right, postoperative oblique view 6 months.

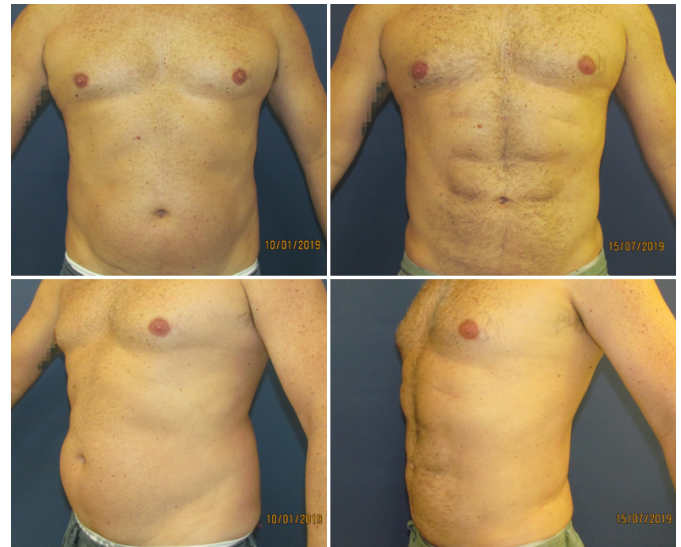

Figure 13. Male patient, 42 years old, sedentary. Upper left, preoperative anterior view. Upper right, postoperative anterior view 6 months. Lower left, preoperative oblique view. Lower right, postoperative oblique view 6 months.

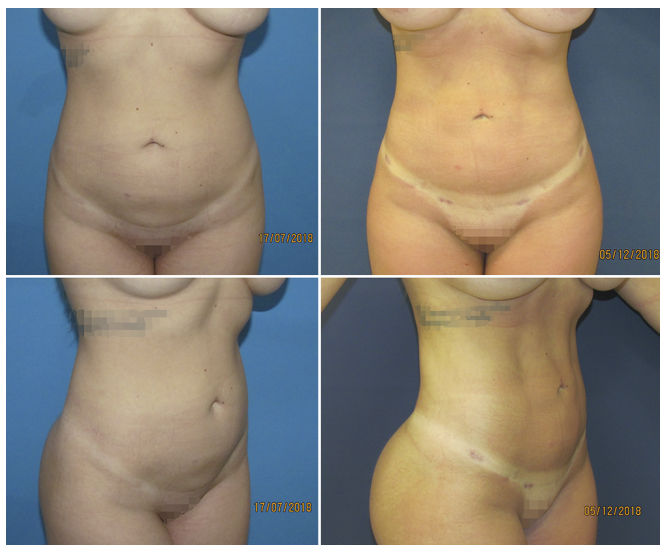

Figure 12. Female patient, 28 years old, sedentary. Upper left, preoperative anterior view. Upper right, postoperative anterior view 6 months. Lower left, preoperative oblique view. Lower right, postoperative oblique view 6 months.

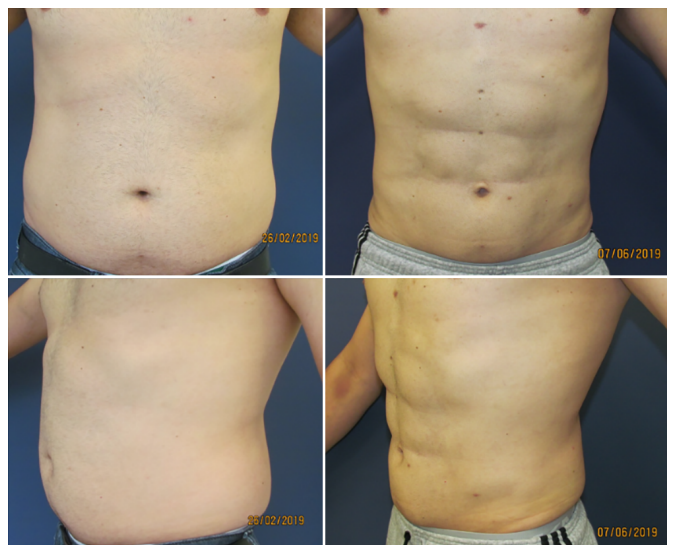


Figure 14. Male patient, 42 years old, practicing moderate physical activities 3 times a week. Upper left, preoperative anterior view. Upper right, postoperative anterior view 3 months. Lower left, preoperative oblique view. Lower right, postoperative oblique view 3 months.

Two patients requested reoperation for complementary fat removal with Lipo type II due to the asymmetry. Both were performed under local anesthesia on an outpatient regimen, with a male case in a 20ml aspirated right upper abdomen; and a female case in the left lower abdomen aspirated 30ml.

No color changes, ischemia, unaesthetic scarring, prolonged edema, hematoma or infection were observed.

DISCUSSION

The contribution of Hoyos et al. (2007, 2014)^{10,11} with high-definition liposuction or HD Lipo, opened a new

chapter in the history of liposuction, elevating the artistic concept, shifting to the search for more anatomical results and more athletic bodies. The concept of high-definition liposuction has recently been discussed with great interest in the subject and several studies published in Brazil^{12,14,17} and the world¹⁸⁻²⁰ and fat graft use within the abdominal rectum sheath²¹ and classification proposals¹³⁻¹⁶. As graduating from 0 to 3¹⁴; in light, only semilunar lines and alba line, intermediate, associated with "V" demarcation of the lower abdomen and iliac crest, and high definition added the marking of the serratus muscle and abdominal metamers¹⁵; and low, medium and high definition, based only on photographic examples¹⁶.

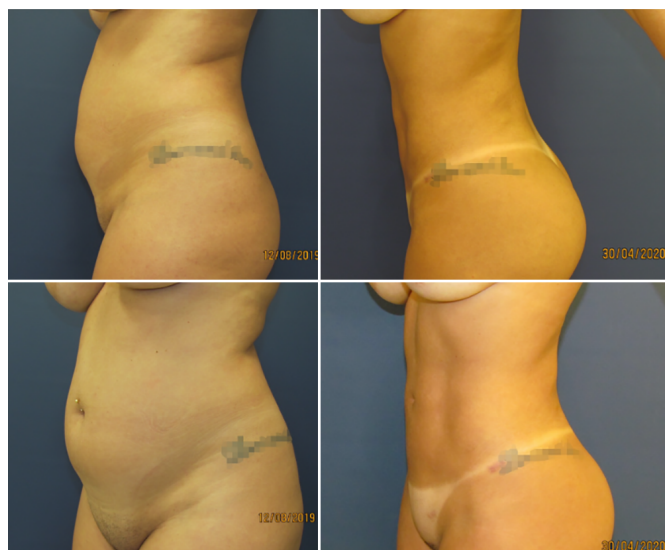


Figure 15. Female patient, 27 years old, sedentary. Upper left, preoperative oblique view. Upper right, postoperative oblique view 8 months. Bottom left, preoperative profile view. Lower right, postoperative profile view 8 months.

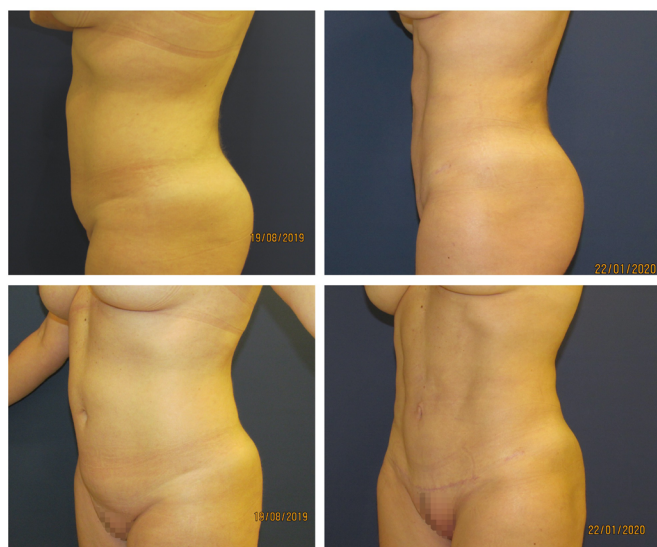


Figure 16. Female patient, 44 years old, sedentary. Upper left, preoperative oblique view. Upper right, postoperative oblique view 6 months. Bottom left, preoperative profile view. Lower right, postoperative profile view 6 months.

Evaluating the evolution of aesthetic procedures and the growing search for naturalness, in our daily practice, we observed since the beginning of 2018 that most patients request the term HD Lipo, but crave softer reliefs than the requested technique. In this same sense, it should be remembered that the volumes preserved on the rectus abdominis muscles between the lines of definition are fatty remnants. Thus, the greater the difference in the volume of preserved adipose tissue and the regions of aspirated grooves, causing greater definition, the greater the chances of artificial results and possible

anatomical distortions caused by future variations in body weight. However, when less adipose tissue is preserved between these grooves, as in MD Lipo, the reliefs are smoother and physiologically less susceptible to disharmonious changes due to possible weight fluctuation.

The present MD Lipo technique is guided by the patient's desire, who mostly seek liposuction to decrease measures and improve body contour and, secondarily, want abdominal definition. We understand that liposuction should be done at three levels of depth, from bottom to top, as described above, as well as we believe that the emptying of the areolar layer, or Lipo type II, must precede the definition liposuction (Lipo type III), both for better adapting to the results intended immediately by the patient, as well as for presenting less chance of future anatomical distortion.

Even though we have been practicing moderately defined liposuction concepts since 2018, the term was first mentioned in an ISAPS Brasil event in April 2019 by Borille¹³, later published in the same year¹⁶. During the event, discussions pointed to the need to separate the intensities of definition of liposuction, as distinct techniques since MD Lipo aims to promote smoother and more natural results, as well as to demystify the need to change the liposuction method used in order to attribute the current aesthetic focus to the surgeon's technical ability as the real promoter of the results.

Currently, defining liposuction has been described using a syringe¹², liposuction device^{14,22}, vibroliposuction^{16,18,19} and laser¹⁷, as well as third generation ultrasound^{10,11} and others²⁰. Although many studies have reported the superiority of different technologies for performing this type of surgery, there is a lack of robust evidence for such statements. The methodology found in the literature is diverse and incompatible in different aspects such as inclusion of patients, surgical technique and result evaluation system by both surgeons and patients, making it impossible to compare them.

Another divergence observed is the need for an additional operative step when there is the use of high-energy liposuction devices (ultrasound and laser), which require a greater financial investment and require additional time to prepare the equipment in the room, in addition to needing to emulsify first the fat and then suck it up. The present technique took an additional surgical time of 20 to 30 minutes.

As mentioned by Wall Junior et al., in 2018²³, unlike processes and technologies that use ultrasound, radiofrequency and laser, traditional liposuction does not apply thermal energy and, therefore, there is no

possibility of burns or related inflammatory response. Studies associated with the use of Vaser[®] reported epidermal injury, thermal lesion in the insertion portal and hyperpigmentation¹⁸.

About the possible advantages of liposuction performed with high-energy devices, it is argued that greater skin retraction, reduced recovery period, less ecchymosis and less post-operative pain. In 2012²⁴, a controlled, randomized, blinded clinical trial was published comparing conventional liposuction with Vaser[®], in which it was concluded that there is greater skin retraction and less blood loss when using the device. It is also reported that there was no difference in the results between the different methods in relation to pain, edema and final results. However, such evidence was challenged both by sampling and methodology, financial conflict, and commercial bias²⁵. In addition, data were published showing the occurrence of seromas, burns in the access and distance portals, in addition to prolonged edema, unsatisfactory definition, hyperpigmentation, nodular fibrosis, Mondor syndrome^{23,26}, as well as a high level of technical knowledge of the required device^{27,28} and high investment in its acquisition. Subsequently, in 2018, Hoyos et al.²⁹, in a series associated with lipoabdominoplasty, made several comments in the need for better scientific evidence regarding the statements regarding the use of technology.

Pereira-Netto et al., in 2018³⁰, in a systematic review, observed that 5 comparative studies between liposuction associated with laser and traditional liposuction concluded that the association with technology would be superior in reducing subcutaneous tissue, skin retraction and patient satisfaction; however, all presented methodological flaws that precede their conclusions regarding the high level of evidence.

Particularly, we prefer the syringe liposuction technique as it allows an objective and precise analysis of the volumes removed. Since the measurement in milliliters of the volumes removed from each region, both in the stage of conventional liposuction and in the definition liposuction (Figure 4), allows strict control of the volumes aspirated. To increase technical quality and promote less chance of asymmetries and, therefore, reduce the possibility of new interventions to improve results. In our experience, the surgical time is equivalent to the other low-energy methods that we have used previously, such as the liposuction device and the vibroliposuction device.

We used a dressing with hollow cylindrical silicone tubes (Figure 5), according to previously published observational research¹², aiming at better adhesion of the skin to the abdominal aponeurosis

and obtaining more visible grooves on the first return, in order to cause a good initial psychological impact to the patient. Subsequently, the use of similar tubes was published²²; in addition to this material, there are reports of the use of foams (Reston[®])²⁶ and gauze and cotton pads¹³ to help obtain the definition. However, such materials transmit a straight-line design, a right angle at the edges (Reston[®]) and a tendency not to properly preserve the curved anatomy of the semilunaris line, previously mentioned³. We observed that Reston[®] has physical characteristics that do not allow adequate adaptation to the curves of the semilunaris lines and have a right-angled edge, which can negatively interfere with the liposuction site. We believe that the use of silicone tube dressings requires a better level of evidence.

Our study observed 3.73% of complications, with dermatitis, adherence, and seroma occurring with 1.86%, 0.93% and 0.93%, respectively. Two reinterventions were carried out for complementary withdrawal, as described above. There were no changes in color, ischemia, unsightly scar, prolonged edema, hematoma or infection. The incidence of seroma was extremely low even without the use of drains, and there were no cases of hematoma even with chemical prophylaxis for thrombosis. Contact dermatitis can be related to the dressing used but was resolved without major complications; there was no pressure injury described by Niddam et al., in 2020²², mentioned in a study using similar dressings.

Empirically, we observed greater satisfaction, both for patients and the medical team, with MD Lipo compared to the traditional technique with no definition previously performed. Furthermore, as well as Jewell et al. (2002)²⁷ we believe that just like any form of technology applied to surgery, it is important to examine whether the new modality is superior to the existing technique in terms of its efficiency, safety and quality of clinical results, as well as it is important to compare complications and clinical results found in the literature. From a surgical perspective, the advances in the devices used must be superior to the existing technology and provide overwhelming evidence for this before affirming superiority.

Finally, we believe that the definition result, be it HD Lipo or MD Lipo, is dependent on the plastic surgeon: his aesthetic sensitivity, anatomical knowledge and experience, regardless of the device of his choice.

CONCLUSION

A medium-definition abdominal liposuction technique or MD Lipo has been described, using

conventional liposuction instruments in the alba and semilunaris lines and the tendinous intersections of the rectus abdominis muscle.

COLLABORATIONS

RSG Analysis and/or data interpretation, Conception and design study, Conceptualization, Data Curation, Final manuscript approval, Investigation, Methodology, Project Administration, Realization of operations and/or trials, Supervision, Validation, Visualization, Writing - Original Draft Preparation, Writing - Review & Editing

GVN Analysis and/or data interpretation, Conception and design study, Final manuscript approval, Methodology, Project Administration, Validation, Writing - Review & Editing

REFERENCES

- International Society of Aesthetic Plastic Surgery (ISAPS). International survey on aesthetic/cosmetic procedures performed in 2018 [Internet]. West Lebanon: ISAPS; 2018; [acesso em 2020 Ago 08]. Disponível em: <https://www.isaps.org/wp-content/uploads/2019/12/ISAPS-Global-Survey-Results-2018-new.pdf>
- Avelar J. Regional distribution and behavior of the subcutaneous tissue concerning selection and indication for liposuction. *Aesthetic Plast Surg.* 1989;3(13):155-65.
- Bozola AR, Psilakis J. Abdominoplasty: a new concept and classification for treatment. *Plast Reconstr Surg.* 1988 Dez;82(6):983-93.
- Gasperoni C, Salgarello M, Emiliozzi P, Gargani G. Subdermal liposuction. *Aesthetic Plast Surg.* 1990;14(2):137-42.
- Gasperoni C, Salgarello M. Rationale of subdermal superficial liposuction related to the anatomy of subcutaneous fat and the superficial fascial system. *Aesthetic Plast Surg.* 1995 Jan/Fev;19(1):13-20.
- Gasparotti M, Lewis CM, Toledo LS. Superficial liposculpture: manual of technique. New York: Springer-Verlag; 1993.
- Souza EBS, Abdalla PCSP, Moia SMS, Cação EG, Federico R, Chávez RS. Lipomioscultura. In: Souza EBS, org. Lipomioscultura. Rio de Janeiro: Di Livros Editora Ltda.; 2009. p. 139-71.
- Mentz HA, Gilliland MD, Patronella CK. Abdominal etching: differential liposuction to detail abdominal musculature. *Aesthetic Plast Surg.* 1993;17(4):287-90.
- Ersek RA, Salisbury AV. Abdominal etching. *Aesthetic Plast Surg.* 1997 Set/Out;21(5):328-31.
- Hoyos AE, Millard JA. VASER-assisted high-definition liposculpture. *Aesthet Surg J.* 2007 Nov/Dez;27(6):594-604.
- Hoyos A, Prendergast PM. High definition body sculpting: art and advanced lipoplasty techniques. Berlin: Springer-Verlag; 2014.
- Gomes RS, Mattiello CM, Rendon NB, Garcia EB, Gomes HFC, Ferreira LM. Lipoaspiração abdominal de alta definição e tubos de silicone. *Rev Bras Cir Plást.* 2018 Out;33(4):567-71.
- Borille G. Medium definition liposuction. *Med Clin Res.* 2019;4(12):1-3.
- Viaro MSS. Lipoaspiração de definição abdominal. *Rev Bras Cir Plást.* 2019;34(3):336-43.
- Cucchiari JV. High definition liposuction classification. *Plast Reconstr Surg Glob Open.* 2019 Set;7(9):e2440.
- Saad A, Combina LN, Altamirano-Arcos C. Abdominal etching. *Clin Plast Surg.* 2020 Jul;47(3):397-408.
- Motta RP. Lipoaspiração laser-assistida de alta definição. *Rev Bras Cir Plást.* 2018;33(1):48-55.
- Husain TM, Salgado CJ, Mundra LS, Perez C, AlQattan HT, Bustillo E, et al. Abdominal etching: surgical technique and outcomes. *Plast Reconstr Surg.* 2019 Abr;143(4):1051-60.
- Saad AN, Arbelaez JP, Benito J. High definition liposculpture in male patients using reciprocating power-assisted liposuction technology: techniques and results in a prospective study. *Aesthet Surg J.* 2020 Fev;40(3):299-307.
- Cucchiari JV. Abdominal etching: surgical technique and outcomes. *Plast Reconstr Surg.* 2020 Abr;145(4):1051-60.
- Danilla S. Rectus abdomin fat transfer (RAFT) in lipoabdominoplasty: a new technique to achieve fitness body contour in patients that require tummy tuck. *Aesthet Surg J.* 2017 Jun;41(6):1389-99.
- Niddam J, Hersant B, Aboud C, Sawan D, SidAhmed-Mezi M, Meningaud JP. Postoperative complications and patient satisfaction after abdominal etching: prospective case series of 25 patients. *Aesthetic Plast Surg.* 2020;44(3):830-5. DOI: <https://doi.org/10.1007/s00266-019-01558-4>
- Wall Junior SH, Claiborne JR. Discussion: a report of 736 high-definition lipoabdominoplasties performed in conjunction with circumferential VASER liposuction. *Plast Reconstr Surg.* 2018 Set;142(3):676-8.
- Nagy MW, Vanek Junior PF. A multicenter, prospective, randomized, single-blind, controlled clinical trial comparing vaser-assisted lipoplasty and suction-assisted lipoplasty. *Plast Reconstr Surg.* 2012 Abr;129(4):681e-9e.
- Swanson E. Improved skin contraction after VASER-assisted lipoplasty: is it a change we can believe in? *Plast Reconstr Surg.* 2012 Nov;130(5):754e-6e.
- Danilla S, Babaitis RA, Jara RP, Quispe DA, Andrades PR, Erazo CA, et al. High-definition liposculpture: what are the complications and how to manage them?. *Aesthetic Plast Surg.* 2020 Abr;44(2):411-8.
- Jewell ML, Fodor PB, Pinto EBS, Al Shammari MA. Clinical application of VASER-assisted lipoplasty: a pilot clinical study. *Aesthet Surg J.* 2002 Mar;22(2):131-46.
- Pinto EBS, Abdalla PCSP, Maciel CM, Santos FPT, Souza RPM. Liposuction and VASER. *Clin Plast Surg.* 2006 Jan;33(1):107-15.
- Hoyos A, Perez ME, Guarín DE, Montenegro A. A report of 736 high-definition lipoabdominoplasties performed in conjunction with circumferential VASER liposuction. *Plast Reconstr Surg.* 2018 Ago;142(3):662-75.
- Pereira-Netto D, Montano-Pedroso JC, Aida ALS, Marson WL, Ferreira LM. Laser-assisted liposuction (LAL) versus traditional liposuction: systematic review. *Aesthetic Plast Surg.* 2018 Abr;42(2):376-83.

*Corresponding author:

Rogério Schützler Gomes

Avenida Trompowsky, 291, Torre 1, Sala 303, Centro, Florianópolis, SC, Brazil.

Zip Code: 88015-300

E-mail: plasticarogério@gmail.com