



Short Communication

Record of postmortem injuries caused by the Neotropical social wasp *Agelaia fulvofasciata* (Degeer) (Hymenoptera, Vespidae) on pig carcasses in the Eastern Amazon region: implications in forensic taphonomy



Rodrigo R. Barbosa^{a,*}, Cesar Carriço^a, Raimundo N.P. Souto^b, Sergio R. Andena^c, Alexandre Ururahy-Rodrigues^d, Margareth M.C. Queiroz^d

^a Programa de Pós-Graduação em Biologia Animal, Universidade Federal Rural do Rio de Janeiro, Rio de Janeiro, RJ, Brazil

^b Laboratório de Artrópodes, Universidade Federal do Amapá, Centro de Ciências Biológicas, Macapá, AP, Brazil

^c Universidade Estadual de Feira de Santana, Departamento de Ciências Biológicas, Feira de Santana, BA, Brazil

^d Laboratório de Transmissores de Leishmanioses, Fundação Oswaldo Cruz, Rio de Janeiro, RJ, Brazil

ARTICLE INFO

Article history:

Received 29 January 2015

Accepted 8 May 2015

Available online 18 July 2015

Associate Editor: Rodrigo Krüger

Keywords:

Autopsy

Forensic Entomology

Savanna

ABSTRACT

Postmortem injuries are a source of misinterpretations in forensic analysis and therefore are subject matter of taphonomic interest. Many types of injuries can cause different artifacts, which deserve attention of the forensic pathologists when evaluating corpses, either at the crime scene or during an autopsy. Insects can be important biotaphonomic agents and their activity may result in artifacts that resemble antemortem injuries. Here, we describe postmortem injuries caused by the Neotropical wasp *Agelaia fulvofasciata* (Degeer, 1773) on domestic pig carcasses weighting 15 kg. The specimens showed extensive injuries to the lower lip, similar to lacerations, and some minor lesions on the snout and anus. In addition, we observed the same wasp species preying on larvae of Sarcophagidae (*Peckia* sp.). Besides causing postmortem injuries, the ability of this species to detect carcasses in the early and fresh decomposition stages should be noted. Thus, future applications aiming criminal, any biotaphonomic events caused by carrion insects need to be disclosed.

© 2015 Published by Elsevier Editora Ltda. on behalf of Sociedade Brasileira de Entomologia. This is an open access article under the CC BY-NC-ND license (<http://creativecommons.org/licenses/by-nc-nd/4.0/>).

The origin and the age of injuries found on corpses may be important to help diagnose of *causa mortis* in forensic analysis (Kondo et al., 1999; Cecchi, 2010). Many types of injuries can cause different artifacts, which deserve attention of the forensic pathologists when evaluating corpses, either at the crime scene or during an autopsy (Ohshima, 2000). Reports in the literature describe the way that both vertebrates and/or invertebrates may change a crime scene. These animals, usually, take off parts of the tissue, modifying the pattern, size and shape of the injuries related or not to the death and also cause postmortem injuries playing an important role as biotaphonomic agents (Patel, 1994; Roger et al., 2002; Ururahy-Rodrigues et al., 2008). Even some pets may cause injuries or deform corpses when they are the only food source (Tsokos and Schulz, 1999; Roger et al., 2002). Extension of injuries and/or bite patterns may infer in defining which animal caused the initial injury

or death. There are records of postmortem injuries caused by rats, hamsters and dogs in corpses found indoors (Ropohl et al., 1995; Tsokos and Schulz, 1999; Roger et al., 2002). Scavenger species, however, are more frequently reported feeding on corpses placed in open field due to its easy access (Asamura et al., 2004).

Many taxa of arthropods, especially fly larvae and beetles, produce surface and internal injuries, not always easily detected by forensic pathologists (Roger et al., 2002; Amendt et al., 2007). Additionally, other arthropods, which are not usually found on decomposing corpses, may also cause postmortem injuries. Such injuries may confuse pathologists in terms of the nature and chronology of the injury, due to similarities with the antemortem injuries (Denic et al., 1997; Roger et al., 2002; Campobasso et al., 2009). Postmortem injuries caused by Formicidae (Hymenoptera) have been extensively recorded (Byard, 2005; Campobasso et al., 2009); however, reports concerning lesions caused by Vespidae are rarely seen in a forensic context.

The presence of Polistinae wasps, which includes the genus *Agelaia* (Lepelletier, 1836), on decomposing animals is common

* Corresponding author.

E-mail: rodrigor1@hotmail.com (R.R. Barbosa).




Fig. 1. Habitus in lateral view of social wasp *Agelaiia fulvofasciata*.

(Jeanne et al., 1995; O'Donnell, 1995; Gomes et al., 2007; Moretti et al., 2008; Noll and Gomes, 2009; Moretti et al., 2011). The *Agelaiia* genus has 33 species that are widely distributed in the Neotropical region, extending from northern Argentina to Mexico and are known for their necrophagous habits and as predators of other insects (Carpenter, 1993). In Brazil 15 species have been recorded. Only recently researchers pointed out the use of social wasps in forensic analysis. There are no published records, however, of postmortem injuries caused by these wasps (Gomes et al., 2007; Moretti et al., 2008). Here, we report postmortem injuries caused by the Neotropical swarm-forming wasp *Agelaiia fulvofasciata* (Degeer, 1773) on domestic pig carcasses in northern Brazil pointing out their biotaphonomic importance.

The study was carried out in Macapá capital of Amapá State, Northeast Brazil. Domestic pig (*Sus scrofa*, L.) carcasses weighting 15 kg from a pig farm were used as experimental models for decomposition. The experiment was conducted during the dry season (20–27 November 2011) in two different phytophysognomies: Amazonian Savanna (00°12'38.87"N, 51°07'27.41"W) and Gallery Forest (00°12'35.01"N, 51°07'24.79"W). The decomposition of the carcasses and the entomofauna activity were recorded daily. Specimens of *A. fulvofasciata* were collected directly from the carcasses with an entomological net and in traps as described by Barbosa et al. (2009).

Specimens of *A. fulvofasciata* (Fig. 1) were observed grouped in the oral, ocular and anal regions of the pig model one day of postmortem (Fig. 2). The wasps took parts of the tissue from the lower lip causing injuries, similar to lacerations, measuring

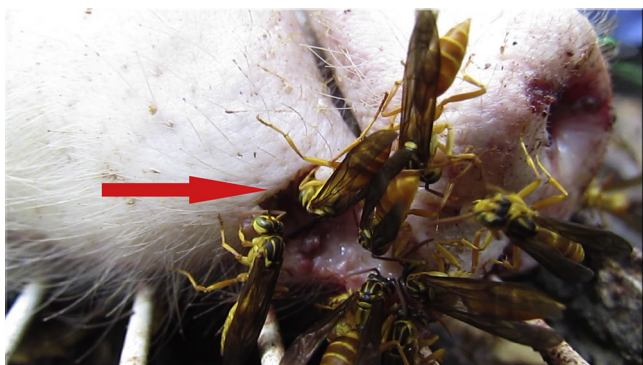

Fig. 2. Arrow pointing biotaphonomic activity of specimens of *Agelaiia fulvofasciata*.

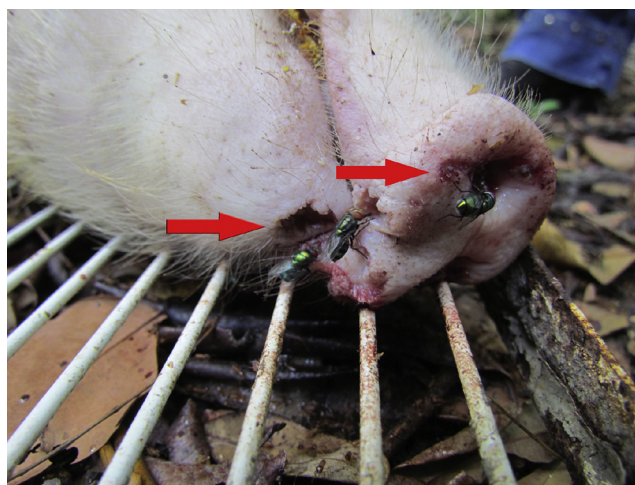


Fig. 3. Arrow pointing postmortem injuries (artifacts) produced by biotaphonomic activity of *Agelaiia fulvofasciata*.

approximately 4 cm in diameter and 2.5 cm in depth, and some minor lesions on the snout and anus (Fig. 3). On the second postmortem day, the wasps were no longer feeding on the carcass due to active decomposition; they were, however, preying on larvae of Sarcophagidae (*Peckia* sp.). In addition, the injuries were the first places colonized by the larvae of Calliphoridae and Sarcophagidae. Sixty-seven specimens of *A. fulvofasciata* were collected, 53 from the Gallery Forest and 14 from the Amazonian Savanna. In both areas, the activity of these specimens occurred from the fresh stage until the active decay (2–4 days of PMI). In the Savanna area, specimens were sampled but predation or necrophagy were not registered.

Agelaiia fulvofasciata, widely distributed in the Amazon region, is known locally as “caba de peixe” (fish wasp) and is often seen in popular markets feeding on fish carcasses (O'Donnell 1995; Silveira et al., 2005, 2008). Moreover, due to its aggressive behavior, sting accidents are common and very painful (Galvão et al., 2005). Records of necrophagy by other species of *Agelaiia* (*A. pallipes* and *A. vicina*) have been reported in Brazil but only in the Southeast region; however injuries such as those described herein have not yet been reported (Gomes et al., 2007; Moretti et al., 2008; Oliveira-Costa and Celino, 2011). Thus, besides causing postmortem injuries, this species is able to detect carcasses in the early decomposition stage, which demonstrates their forensic importance as biotaphonomic agents.

Carrion insects are useful in the elucidation of the cause of death and in cases of neglect (Catts and Goff, 1992; Benecke, 2001). These biotaphonomic agents, however, may cause confusion when a corpse is being examined as they can produce injuries capable of misleading forensic examiners due to the nature and the age of the lesion, especially when such insects are not found on the corpse at the time of discovery (Patel, 1994; Denic et al., 1997). These injuries may resemble ulcers, burns or abrasions, making it difficult, for the examiners to determine if they were antemortem, perimortem or postmortem. Even experienced crime scene professionals may have questions on the separation of postmortem from perimortem injuries, such as those reported by Denic et al. (1997) concerning injuries caused by cockroaches (Blattaria) on infants that were confused with antemortem burns. Byard (2005) also reported three cases in which postmortem injuries caused by ants resembled perimortem lesions in different cases involving suicide, homicide, and natural death, raising doubts on the times of the injuries.

Ants can both inhibit colonization of carrion by necrophagous flies and predate large amounts of immatures (eggs and larvae) on

animal carcasses and human corpses. This behavior is particularly important because it may interfere in the calculation of the postmortem interval (PMI), as observed by Wells and Greenberg (1994), Lindgren et al. (2011) and Moretti et al. (2013).

Biotaphonomic episodes are important factors to consider in a crime scene (Haskell et al., 1997; Ururahy-Rodrigues et al., 2008), because the activity of scavengers and opportunist animals may significantly mask the real cause of death (Byard, 2005). Ururahy-Rodrigues et al. (2008) showed an important biotaphonomic event related to the activity of the beetle *Coprophanaeus lancifer*, which, besides causing extensive injuries in pig carcass, changed its position relative to the ground and caused eviscerations in the abdominal region and dismemberments of extremities of the locomotor limbs. Any modification of the crime scene may affect the forensic evaluation, which may result in serious misinterpretation in a criminal investigation (Patel, 1994). During the autopsy, all injuries should be understood adequately to avoid compromising the investigation. Therefore any biotaphonomic event caused by carrion insects must be investigated, especially in criminal applications.

Conflict of interest

The authors declare no conflicts of interest.

Acknowledgements

This work was supported by PROEP-CNPq (process n° 400153/2011-4), and Plano de Objetivos e Metas (POM-IOC/FIOCRUZ) for financial support. We would like to thank to CAPES for grants and scholarships and Marina Vianna Braga for helpful review of the manuscript.

References

- Amendt, J., Campobasso, C.P., Gaudry, E., LeBlanc, H.N., Hall, M.J.R., 2007. Best practice in forensic entomology – standards and guidelines. *Int. J. Leg. Med.* 121, 90–104.
- Asamura, H., Takayanagi, K., Ota, M., Kobayashi, K., Fukushima, H., 2004. Unusual characteristic patterns of postmortem injuries. *J. Forensic Sci.* 49, 592–594.
- Barbosa, R.R., Mello-Patiu, C.A., Mello, R.P., Queiroz, M.M.C., 2009. New records of calyptrate dipterans (Fanniidae, Muscidae and Sarcophagidae) associated with the decomposition of domestic pigs in Brazil. *Mem. Inst. Oswaldo Cruz* 104, 923–926.
- Benecke, M., 2001. A brief history of forensic entomology. *Forensic Sci. Int.* 120, 2–14.
- Byard, R.W., 2005. Autopsy problems associated with postmortem ant activity. *Forensic Sci. Med. Pathol.* 1, 37–40.
- Campobasso, C.P., Marchetti, D., Introna, F., Colonna, M.F., 2009. Postmortem artifacts made by ants and the effect of ant activity on decompositional rates. *Am. J. Forensic Med. Pathol.* 30, 84–87.
- Carpenter, J.M., 1993. Biogeographic patterns in the Vespidae (Hymenoptera): two views of Africa and South America. In: Goldblatt, P. (Ed.), *Biological Relationships between Africa and South America*. Yale University Press, New Haven/London, pp. 139–155.
- Catts, E.P., Goff, M.L., 1992. Forensic Entomology in criminal investigations. *Ann. Rev. Entomol.* 37, 253–272.
- Cecchi, R., 2010. Estimating wound age: looking into the future. *Int. J. Leg. Med.* 124, 523–536.
- Denic, N., Huyer, D.W., Sinal, S.H., Lantz, P.E., Smith, C.R., Silver, M.B., 1997. Cockroach: the omnivorous scavenger. Potential misinterpretation of postmortem injuries. *Am. J. Forensic Med. Pathol.* 18, 177–180.
- Galvão, C.E.S., Iwai, L.K., Santos, L.D., Mendes, M.A., Palma, M.S., Castro, F.F.M., Neto, E.C., Kalil, J., 2005. Análise proteômica das principais proteínas antigênicas do veneno da vespa *Agelaia pallipes*. *Rev. Bras. Alerg. Immunopatol.* 28, 20–25.
- Gomes, L., Gomes, G., Oliveira, H.G., Junior, J.J.M., Desuo, I.C., Queiroz, M.M.C., Giannotti, E., von Zuben, C.J., 2007. Occurrence of Hymenoptera on *Sus scrofa* carcasses during summer and winter seasons in southeastern Brazil. *Rev. Bras. Entomol.* 51, 394–396.
- Haskell, N.H., Hall, R.D., Cervenka, V.J., Clark, M.A., 1997. On the body: insects' life stage presence and their postmortem artifacts. In: Haglung, W.D., Sorg, M.H. (Eds.), *Forensic Taphonomy: The Post Mortem Fate of Human Remains*. CRC Press, pp. 415–448.
- Jeanne, R.L., Hunt, J.H., Keeping, M.G., 1995. Foraging in social wasps: *Agelaia* lacks recruitment to food (Hymenoptera: Vespidae). *J. Kansas Entomol. Soc.* 68, 279–289.
- Kondo, T., Ohshima, T., Eisenmenger, W., 1999. Immunohistochemical and morphometrical study on the temporal expression of interleukin-1 α (IL-1 α) in human skin wounds for forensic wound age determination. *Int. J. Leg. Med.* 112, 249–252.
- Lindgren, N.K., Bucheli, S.R., Archambeault, A.D., Bytheway, J.A., 2011. Exclusion of forensically important flies due to burying behavior by the red imported fire ant (*Solenopsis invicta*) in southeast Texas. *Forensic Sci. Int.* 204, e1–e3.
- Moretti, T.C., Giannotti, E., Thyssen, P.J., Solis, D.R., Godoy, W.A.C., 2011. Bait and habitat preferences, and temporal variability of social wasps (Hymenoptera: Vespidae) attracted to vertebrate carrion. *J. Med. Entomol.* 48, 1069–1075.
- Moretti, T.C., Thyssen, P.J., Godoy, W.A.C., Solis, D.R., 2008. Necrophagy by the social wasp *Agelaia pallipes* (Hymenoptera: Vespidae, Epiponini): possible forensic implications. *Sociobiology* 51, 393–398.
- Moretti, T.C., Solis, D.R., Godoy, W.A.C., 2013. Ants (Hymenoptera: Formicidae) collected with carrion-baited traps in Southeast Brazil. *Open Forensic Sci. J.* 6, 1–5.
- Noll, F.B., Gomes, B., 2009. An improved bait method for collecting Hymenoptera, especially social wasps (Vespidae Polistinae). *Neotrop. Entomol.* 38, 477–481.
- O'Donnell, S., 1995. Necrophagy by neotropical swarm-founding wasps (Hymenoptera: Vespidae, Epiponini). *Biotropica* 27, 133–136.
- Ohshima, T., 2000. Forensic wound examination. *Forensic Sci. Int.* 113, 153–164.
- Oliveira-Costa, J., Celino, T.B., 2011. Himenópteros frequentes em pesquisas forenses. In: Oliveira-Costa, J. (Ed.), *Entomologia Forense: quando os insetos são vestígios*, 3rd ed. Millennium, Campinas, pp. 251–282.
- Patel, F., 1994. Artefact in forensic medicine: postmortem rodent activity. *J. Forensic Sci.* 39, 257–260.
- Roger, W., Byard, M.D., Ross, A., James, F.R.C.P.A., Gilbert, J.D., 2002. Diagnostic problems associated with cadaveric trauma from animal activity. *Am. J. Forensic Med. Pathol.* 23, 238–244.
- Ropohl, D., Scheithauer, R., Pollak, S., 1995. Postmortem injuries inflicted by domestic golden hamster: morphological aspects and evidence by DNA typing. *Forensic Sci. Int.* 72, 81–90.
- Silveira, O.T., Esposito, M.C., Santos, J.N., Gemaque Jr., F.E., 2005. Social wasps and bees captured in carrion traps in a rainforest in Brazil. *Entomol. Sci.* 8, 33–39.
- Silveira, O.T., Neto, S.V.C., Silveira, O.F.M., 2008. Social wasps of two wetland ecosystems in Brazilian Amazonia (Hymenoptera, Vespidae, Polistinae). *Acta Amazon.* 38, 333–344.
- Tsokos, M., Schulz, F., 1999. Indoor postmortem animal interference by carnivores and rodents: report of two cases and review of the literature. *Int. J. Leg. Med.* 112, 115–119.
- Uruahy-Rodrigues, A., Rafael, J.A., Wanderley, R.F., Marques, H., Pujol-Luz, J.R., 2008. *Coprophanaeus lancifer* (Linnaeus, 1767) (Coleoptera, Scarabaeidae) activity moves a man-size pig carcass: relevant data for forensic taphonomy. *Forensic Sci. Int.* 182, e19–e22.
- Wells, J.D., Greenberg, B., 1994. Effect of the red imported fire ant (Hymenoptera: Formicidae) and carcass type on the daily occurrence of post feeding carrion-fly larvae (Diptera: Calliphoridae, Sarcophagidae). *J. Med. Entomol.* 31, 171–174.