

Wound healing potential of aqueous crude extract of *Stevia rebaudiana* in mice

Kuntal Das

Department of Pharmacognosy and Phytochemistry, St. John's College of Pharmacy, Vijayanagar, India.

Abstract: The present study was carried out to evaluate the wound healing potential of crude aqueous extract of *Stevia rebaudiana* (Bertoni) Bertoni, Asteraceae, in experimental animals. All experiments were conducted following standard procedures. The crude extract was administered topically in graded doses of 150, 250 and 500 mg/kg b.w. was used for evaluating the wound healing potential in excision wound model for fourteen days and orally in the incision wound model for ten days, respectively. Povidone iodine ointment was used as standard (5.0% w/w). Dose dependent activities resulted in both the wound models when compared to the standard (povidone iodine) and the control. Topical application of crude aqueous extract of *S. rebaudiana* (500 mg/kg b.w) in excision wound model decreased significantly the wound area by 15th day, *i.e.* 48.2±2.0 compared with control 94.1±1.2. Epithelization time was decreased from 17.3±0.21 to 12.0±0.10 and hydroxylproline content was increased from 32.2±0.11 to 67.6±0.10 when compared with control. In incision wound model breaking strength of wounds, wet and dry granulation of the tissue weight and hydroxyproline were increased significantly from control with AESR. In conclusion, AESR leaves accelerated wound healing activity in mice and thus supports its traditional use.

Article

Received 1 Oct 2012
Accepted 21 Jan 2013
Available online 1 Feb 2013

Keywords:

Stevia rebaudiana
aqueous extract
wound healing
incision
excision

ISSN 0102-695X
DOI 10.1590/S0102-695X2013005000011

Introduction

A large number of plants are used by folklore traditions in India for treatment of cuts, wounds and burns. Various research data revealed that plants may worked as healing and regeneration of the tissue by multiple mechanisms. There are several reports stating that the extracts of several plants, used for wound healing properties (Stephen et al., 2010; Pirbalouti et al., 2010; Subhashini & Arunachalam, 2011; Dewangan et al., 2012). Oflate, *Stevia rebaudiana* (Bertoni) Bertoni, plant (SR) was originated from South America (Paraguay and Brazil), belongs to the family Asteraceae (Bertoni, 1905), claimed as a potent wound healing plant. The leaf part is most medicinally important in traditional system of medicine and it has hypoglycemic, oral contraceptive, cardiovascular, and antimicrobial activities. It is also used for weight loss, digestive and skin problems (Mourey, 1992; Ghosh et al., 2008). Traditional uses and earlier reports have revealed, enhanced healing with less scarring of cuts, wounds, burns, acne, seborrhea, dermatitis, and psoriasis after topical application of aqueous *Stevia* extracts (Mourey, 1992; Rita Elkins, 1997). These are mainly comprised of stevioside, steviobioside, rebaudioside A, B, C, D, dulcoside A, B (Leung & Foster, 1996). The non sweet constituents mainly are labdane, diterpenes, triterpenes, sterols and flavonoids. Stevioside

is the main constituent, is abundantly available in the plant (10-18% w/w in dry basis). It plays major role in various fields like sugar substitute, medicinal fields and also folk remedies. Though this plant have been screened scientifically for evaluation of their various activities in different pharmacological models, but the potential of wound healing activity of the traditionally used *Stevia* plant is remains unexplored. Hence in the focus of *Stevia*'s use in the management of diverse diseases and treatment of skin ulcer in folklore medicine, the present study was conducted to investigate the excision and incision wound healing potential of SR aqueous leaf extract in mice.

Materials and Methods

Materials

Cuttings of *Stevia rebaudiana* (Bertoni) Bertoni, Asteraceae, plants, collected from Ankur Nursery, Ripponpet (Shimoga, Karnataka), India, were used as a test plant for the present study. The plant was authenticated by Dr. T. N. Shivananda, Principal Scientist, Dept of Medicinal and Aromatic Plant Division, Indian Institute of Horticultural Research, Bangalore, India and the specimen copy was preserved in the dept herbarium (Herbarium No: SJPC/09/*Stevia*/2008-09) for future reference. The plant sample (leaves) was collected and oven dried at 60 °C for

6 h. The dried leaves were stored at 4 °C and were used for the further process.

Preparation of *Stevia* extract

Dried *Stevia* leaves (250 g) was extracted with distilled water using reflux condenser for 6 h after standardization of the method. Oven temperature was maintained at 45 °C. Extract was collected and filtered using Whatman No 1 filter paper and the filtrate was then subjected to evaporation under reduced pressure to get a soft extract. The yield of the extract was 28% (w/w).

Phytochemical screening methods

Aqueous extract was evaluated for presence of various phytoconstituents by performing different qualitative chemical tests reported. The results of preliminary phytochemical screenings studies for crude aqueous extract of *S. rebaudiana* (AESR) leaf showed the presence of tannins, carbohydrate, saponins, diterpenes, flavonoids and polyphenolic compounds (Khandelwal, 2005). Further the presence of the active constituents was confirmed by thin layer chromatography (TLC).

Animals

The protocol of the study was approved by the Local Ethical Committee for animal experimentation (Ref no. IJAHSM/IAEC/2008/008). The mice were obtained from NIMHANS, Bangalore, India and kept in animal house in standard conditions of temperature (28±2 °C) and relative humidity (46±6%) with 12-h light-dark cycle and adequate ventilation. They were provided food and water ad libitum during the whole period of the experiment.

An acute toxicity study was conducted according to the staircase method. Toxicity studies conducted as per internationally accepted protocol drawn under OECD (Organization for Economic Co-operation and Development) guidelines 420 in Swiss albino mice at a dose level of extracts up to 2000 mg/kg. The animals were physically active and were consuming food and water in a regular way. Male albino Swiss mice weighing 25-30 g were used in wound healing model experiments. A total of three animals would be used for each dose level investigated. The starting dose for the sighting study was selected from the fixed dose levels of 5, 50, 300 and 2000 mg/kg as a dose expected to produce evident toxicity. The extracts were administered in a single dose by gavage using a stomach tube or a suitable intubation canula. A period of 24 h would be allowed between the dosing of each animal. All animals were observed for the body weights, relative weights of the kidneys, livers, lungs and hearts, food consumption etc for fourteen days.

Wound healing activity

Excision and incision wound models were used to evaluate the wound healing activity of AESR.

Excision wound model

The mice were anaesthetized prior to creation of the wounds, with 1 mL of intravenous ketamine hydrochloride (10 mg/kg body weight). The dorsal fur of the animal was shaved with an electric clipper and the area of the wound to be created was outlined on the back of the animals with methylene blue using a circular stainless steel stencil. A full thickness of the excision wound of 2.5 cm in width (circular area 4.90 cm²) and 0.2 cm depth was created along the markings using toothed forceps, a surgical blade and pointed scissors (Figure 1). The entire wound left open (Diwan et al., 1982; Patil & Kulkarni, 1984). All the surgical interventions were carried out under sterile condition. The animals were divided into five groups of six each and the following treatments were given once daily for fourteen days:

Group I: Control (no treatment).

Group II: Standard and treated with Povidone iodine ointment (5.0%), (topically).

Group III: AESR of 150 mg/kg b.w. (topically)

Group IV: AESR of 250 mg/kg b.w. (topically)

Group V: AESR of 500 mg/kg b.w. (topically)

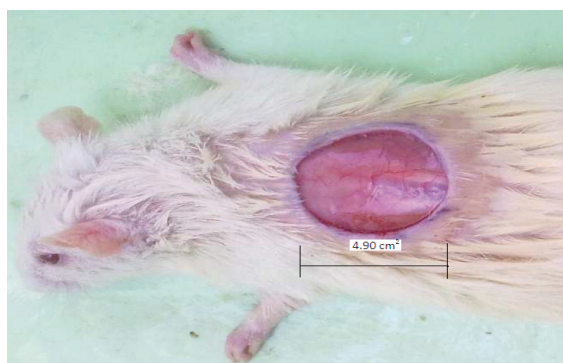

Figure 1. Excision model in mice (arrow mark show excision wound in mice).

The measurements of the wound areas of the excision wound model were taken on 1st, 5th and 15th day following the initial wound using transparent paper and a permanent marker. The recorded wound areas were measured with graph paper. Progressive decrease in the wound size was monitored periodically. Wound closure, epithelialisation time and weight of the tissue were studied. The period of epithelialisation was calculated as the number of days required for falling of the dead tissue remnants without any residual raw wound. In the excision wound model, granulation tissue formed on the wound was excised on the 15th postoperative day and its weight

recorded. The tissue was dried in an oven at 60 °C and the dry weight was again noted. Acid hydrolysate of the dry tissue was used for the determination of hydroxyproline (Neuman & Logan, 1950).

Incision wound model

The mice were anaesthetized prior to and during creation of the wounds, with 1 mL of intravenous ketamine hydrochloride (10 mg/kg body weight). The dorsal fur of the animals was shaved with an electric clipper. A longitudinal paravertebral incision of 6 cm long was made through the skin and cutaneous tissue on the back as described by Dash et al., (2009). After the incision, the parted skin was sutured 1 cm apart using a surgical thread and curved needle. The wounds were left undressed (Figure 2). The sutures were removed on the 8th post wound day the experiment was carried out under sterile conditions. The animals were divided into five groups of six animals each and following treatments were applied:

Group I: Control (normal saline).

Group II: Standard Povidone iodine ointment (5.0%).

Group III: AESR of 150 mg/kg b.w.

Group IV: AESR of 250 mg/kg b.w.

Group V: AESR of 500 mg/kg b.w.

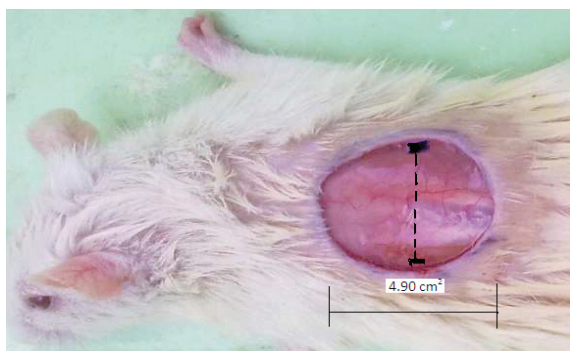


Figure 2. Incision model in mice (arrow mark show tying of thread in mice).

Finally the skin-breaking strength was measured by the method of Lee (1968) on the 10th day evening after the last application. Then the granulation tissue was taken on the 11th day for determination of hydroxyproline.

Histopathological study

The healing tissues obtained on the 11th day from all groups of animals of the incision wound model were processed for histological study. A specimen sample of the tissue was isolated from the healed skin of each group of mice for the histopathological examination (Sadaf et al., 2006). The cross sectional full thickness skin specimens

from each group were collected at the end of the experiment to evaluate the histopathological alterations. Samples were fixed in 10% buffered formalin, processed and blocked with paraffin and then sectioned into 5 µm thick sections. The amount of collagen was quantified using Vangeison stain. The different animal groups were assessed blindly by the pathologist and results were compared with the control groups.

Statistical analysis

The results were subjected to statistical analysis by using one way ANOVA followed by Turkey Kramer Multiple Comparison Test. Values of $p < 0.05$ were considered statistically significant.

Result

Acute toxicity study

The acute toxicity test after oral administration of 2000 mg/kg of extracts revealed no toxicity at this dose. There were no significant alterations in water or food consumption, or body weight during the experiment. The body weights, relative weights of the kidneys, livers, lungs and hearts were not statistically different from those of the control group. The LD50 of the extract was found to be >2000 mg/kg body wt.

Wound area

The effect of different concentration of AESR on excision wound model in mice was tabulated in Table 1. AESR (500 mg/kg b.w) treated animals showed significant reduction in the wound area ($p < 0.05$), faster rate of epithialization (12.0 ± 0.10) and increased dry weight of the tissue ($p < 0.05$) when compared with the control group of animals. The granulation tissue weight and hydroxyproline content were moderately high ($p < 0.05$) in comparison to the control group of animals.

Further, the results of the wound healing effect of SR extracts in the incision wound model presented in Table 2. All extracts show the significant effects of wound healing potential by does dependent manner. In an incision wound model, SR-treated animals (500 mg/kg b.w) were demonstrated significant skin-breaking strength up to 458.6 ± 4.22 when compared to control animals (343.12 ± 3.12). Significant increase in the weight of the granulation tissue and hydroxyproline content ($p < 0.05$) were also observed in animals treated with the same concentration of the *Stevia* extract (500 mg/kg b.w) when compared to the control group of animals.

Histological evaluation

Histological evaluation was carried out for both the treated and untreated mice. Histological examination revealed the wound healing process of the wounded tissue in AESR (500 mg/kg b.w) treated mice was comparably close to the reference drug treated mice. No healing was observed in negative control group. Granulation tissue primarily contains fibroblasts, collagen fibers, very less oedema and newly generated blood vessels which were also observed in leaf extract treated mice. The histopathological examination provided additional evidence for the experimental wound healing studies which was based on the contraction value of wound area and the measurement of tensile strength. There was a full thickness epidermal regeneration which covered completely the wound area. The epidermis was thick and disorganized, especially when compared with the adjacent normal skin. In all, complete epithelialization (Figure 3a), more collagen fibers and less infiltration of tissue were observed in treated mice (Figure 3 b-e).

Discussion

Wound healing is a complex process of restoring cellular structures and tissue layers in damaged tissue together to its normal state and commencing in the fibroblastic stage where the area of the wound undergoes shrinkage (Chitra et al., 2009). It comprises of different phases such as contraction, granulation, epithelization and collagenation (Ayyanar & Ignacimuthu, 2009; Wild et al., 2010). Wound healing can be discussed in three phases viz. Inflammatory phase, proliferative phase and maturational or remodelling phase. The inflammatory phase is characterized by haemostasis and inflammation. Proliferative phase is followed by epithelialization, angiogenesis and collagen deposition. In the maturation phase, the wound undergoes contraction resulting in a smaller amount of apparent scar tissue (Phillips et al., 1991). Granulation tissue which is formed in the final part of the proliferative phase is primarily made up of fibroblasts, collagen, oedema and new small blood vessels. The increase in dry granulation tissue weight in the test

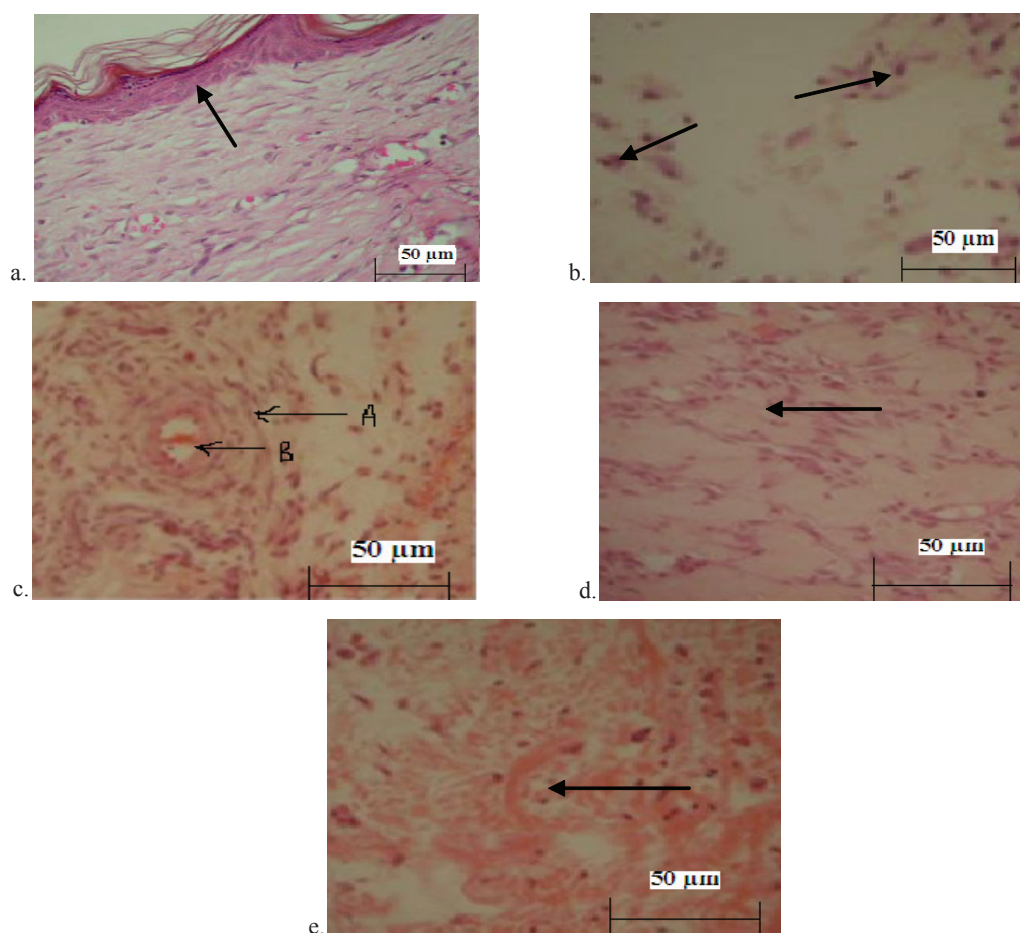


Figure 3. a. Control; b. Treated with extract (150 mg/kg), arrow mark show the layer of arrow marks show the less collagen fibers formation) epithelialisation); c. Treated with extract (250 mg/kg) A indicates more collagen fibers and less infiltration tissue, B. blood vessel; d. Treated with extract (500 mg/kg) arrow mark indicated more organized collagen fibers a of sign of faster healing); e. Treated with povidone iodine ointment arrow mark show more collagen formation, tissue infiltration with macrophages).

treated animals suggests higher protein content (Devipriya & Shyamladevi, 1999). AESR demonstrated a significant increase in the hydroxyproline content of the granulation tissue indicating increased collagen turnover. Collagen is a major protein of the extracellular matrix and is the major component that ultimately contributes to wound strength (Pattanayak et al., 2008). Breakdown of collagen liberates free hydroxyproline and its peptides. Measurement of the hydroxyproline could be used as an index for collagen turnover (Sasidharan et al., 2012). In this investigation two models were used to assess the effect of the AESR as both applied topically and orally. The 500 mg/kg b.w AESR was recorded similar effectiveness when compared to the group treated with a commercial brand of povidone iodine ointment but the magnitude was lesser than standard. The results of the present investigation showed that SR has a definite wound healing action.

The data from excision model revealed that all the different three doses of AESR exhibited significant wound healing promoting activity. However, the effect was found to be concentration related fashion where 500 mg/kg b.w. dose resulted with significant wound-healing activity by decreasing period of epithelialization, formation of granulation tissue, synthesis of collagen and by increased in the rate of wound contraction as compared to the control animals. Further the hydroxyproline content of the granulation tissue of the animals treated with AESR (500 mg/kg b.w) was significantly increased when compared to the control and the group of animals treated with the same at 150 and 250 mg/kg b.w respectively indicating increased collagen turnover. In addition, increased in breaking strength, dry and wet tissue weight in incision model were also indicated the presence of higher protein content. The preliminary phytochemical analysis of AESR revealed the presence of tannins, carbohydrate, saponins, diterpenes, flavonoids and polyphenolic compounds. Flavonoids are known to reduce lipid peroxidation not only by preventing or slowing the onset of cell necrosis but also by improving vascularity. Hence, any drug that inhibits lipid peroxidation is believed to increase the viability of collagen fibrils by increasing the strength of collagen fibres, increasing the circulation, preventing the cell damage and by promoting the DNA synthesis (Getie et al., 2002). Studies were revealed that flavonoids (Tsuchiya et al., 1996) are also known to promote the wound healing process mainly due to their astringent and antimicrobial properties which appear to be responsible for the wound healing and increased rate of epithelialisation (Tsuchiya et al., 1996). Tannins are the main components of many plant extracts and they act as free radical scavengers (Bekerecioglu et al., 1998; Marja et al., 1999; Raquel et al., 2000). Overall the histopathological examinations showed that healing process of the wounded tissue in AESR group was comparably close to the reference drug treated group, whereas no healing was observed in negative control

group (untreated). The histopathological observations were provided additional evidence for the experimental wound healing studies based on the contraction value of wound areas and the measurement of tensile strength (Figure 3 a-e). An increased in blood vessel and the role of antioxidant were also revealed earlier (Allen et al., 2005). Flavonoids (Vinothapooshan et al., 2010) tannins (Chaudhari & Mengi, 2006) and saponins (Murthi et al., 2011) are also known to promote the wound-healing process mainly due to their astringent and antimicrobial property, which seems to be responsible for wound contraction and increased rate of epithelialisation (Deshmukh et al., 2009). Similar types of wound-healing activity were reported on *Vernonia arborea* (Manjunatha et al., 2005) and *Pentas lanceolata* (Nayak et al., 2005).

It was observed that all the extracts were comparable with the standard. Thus it may be concluded that AESR has the potential to satisfy all requirements of an ideal dressing material in that it provides an environment at the surface of the wound in which healing took place at the maximum rate consistent with the formation of granulation tissue. The plant extracts left no prominent scar at the wound sites while povidone iodine ointment treated groups had prominent scars. This property which is lacking in povidone iodine and other synthetic drugs used for wound treatment in general is of cosmetic importance especially to people who are prone to scar formation. So the study provides a rationale for the use of *Stevia* preparations in the traditional system of medicine to promote wound healing. This effect may be explained by several mechanisms such as coating the wound, forming complexes with proteins of microorganism cell wall, chelating free radicals and reactive oxygen species, stimulating the contraction of the wound and increasing the formation of new capillaries and fibroblasts. Further the extract did not produce any adverse effect and because of this it is possible to recommend its use in the treatment of wounds.

Conclusion

The study thus demonstrated the wound healing activity of aqueous extract of the leaf of SR and found to be effective in the functional recovery of the wound healing by dose dependent manner. The result may be attributed to the phytoconstituents present in it which may be either due to their individual or cumulative effect that enhanced wound healing and provided scientific evidence to the ethnomedicinal futures of *Stevia rebaudiana*.

Acknowledgement

The author is thankful to the institution for providing all the necessary facilities required for the experiment and to Mr. Anil Kumar Kathiriyai, M. Pharm

student, Department of Pharmacology, St. John's Pharmacy College, India for his active help in this research.

References

- Allen LV, Popovich NG, Ansel HC 2005. Ansel's Pharmaceutical dosage form and drug delivery system. Baltimore: Lippincott Williams & Wilkins; p. 278-281.
- Ayyanar M, Ignacimuthu S 2009. Herbal medicines for wound healing among tribal people in Southern India: ethnobotanical and scientific evidences. *Int J Appl Res Nat Prod* 2: 29-42.
- Bekerecioglu M, Tercan M, Ozyazan I 1998. The effect of *Ginkgo biloba* (Egb 761) as a free radical scavenger on the survival on skin flaps in rats. *Sci J Plast Reconstr Hand Surg* 32: 135-139.
- Bertoni MS 1905. Le Kaa He-e. Sa nature et ses propriétés. *Ancient Paraguayos I*: 1-14.
- Chaudhari M, Mengi S 2006. Evaluation of phytoconstituents of *Terminalia arjuna* for wound healing activity in rats. *Phytother Res* 20: 799-805.
- Chitra S, Patil MB, Ravi K 2009. Wound healing activity of *Hyptis suaveolens* (L) poit (Lamiaceae). *Int J Pharm Technol Res* 1: 737-744.
- Dash GK, Mondal S, Murty PN 2009. Evaluation of wound healing effects of *Argemone mexicana* Linn. leaves. *Herbal Heritage I*: 136-141.
- Deshmukh PT, Fernandes J, Akarte A, Emmanuel T 2009. Wound healing activity of *Calotropis gigantea* root bark in rats. *J Ethnopharmacol* 125: 178-181.
- Devi PS, Shyamaladevi CS 1999. Protective effect of quercetin in cisplatin induced cell injury in the kidney. *Indian J Pharmacol* 13: 422-426.
- Dewangan H, Bais M, Jaiswal V, Verma VK 2012. Potential wound healing activity of the ethanolic extract of *Solanum xanthocarpum* schrad and wendl leaves. *Pak J Pharm Sci* 25: 189-194.
- Diwan PV, Tilloo LD, Kulkarni DR 1982. Influence of *Tridax procumbens* on wound healing. *Ind J Med Res* 75: 460-464.
- Getie M, Gebre Mariam T, Reitz R, Neubert RH 2002. Evaluation of the release profiles of flavonoids from topical formulations of the crude extract of the leaves of *Dodonea viscosa* (Sapindaceae). *Pharmazie* 57: 320-322.
- Ghosh S, Subudhi E, Nayak S 2008. Antimicrobial assay of *Stevia rebaudiana* Bertoni leaf extracts against 10 pathogens. *Int J Integr Biol* 2: 27-31.
- Khandelwal KR 2005. A text book of practical Pharmacognosy, 27th ed. Pune. Nirali Prakashan, p. 151-163.
- Lee KH 1968. Studies on mechanism of action of salicylates II. Retardation of wound healing by aspirin. *J Pharm Sci* 57: 1042-1043.
- Leung AY, Foster S 1996. Encyclopedia of common natural ingredients used in food, drugs and cosmetics, John Wiley and Sons Inc. New York. 2: 478.
- Manjunatha BK, Vidya SM, Rashmi KV, Mankani KL, Shilpa HJ, Singh S, Jagadeesh D 2005. Evaluation of wound-healing potency of *Vernonia arborea* Hk. *Indian J Pharmacol* 37: 223-226.
- Marja PK, Anu IH, Heikki JV, Jussi Pekka R, Kalevi PTSK, Marina H 1999. Antioxidant activity of plant extracts containing phenolic compounds. *J Agric Food Chem* 47: 3954-3962.
- Mourey D 1992. Life with Stevia: How sweet it is. Nutritional and Medicinal Uses. <http://healthfree.com/stevlife.html>. Accessed 12 Sep 2012.
- Murti K, Lambole V, Panchal M, Shah M, Gajera V 2011. Evaluation of wound healing activity of polyherbal formulation in rats. *Res J Pharmacogn Phytochem* 3: 112-115.
- Nayak BS, Vinutha B, Geetha B, Sudha B 2005. Experimental evaluation of *Pentas lanceolata* for wound healing activity in rats. *Fitotherapia* 76: 671-675.
- Neuman RE, Logan MA 1950. The determination of hydroxyproline. *J Biol Chem* 184: 299-306.
- Patil PA, Kulkarni DR 1984. Antiproliferative agents on healing of dead space wounds in rats. *Ind J Med Res* 79: 445-447.
- Pattanayak SP, Sunita P 2008. Wound healing, anti-microbial and antioxidant potential of *Dendrophthoe falcata* (L.f) Ettingsh. *J Ethnopharmacol* 120: 241-247.
- Phillips GD, Whitehe RA, Kinghton DR 1991. Initiation and pattern of angiogenesis in wound healing in the rats. *Am J Anat* 192: 257-262.
- Pirbalouti GA, Koohpayeh A, Karimi I 2010. The wound healing activity of flower extract of *Punica granatum* and *Achillea kellalensis* in wister rats. *Acta Poloniae Pharmaceutica Drug Res* 67: 1070-1110.
- Raquel P, Laura B, Fulgencio SC 2000. Antioxidant activity of dietary polyphenols as determined by a modified ferric reducing/ antioxidant power assay. *J Agric Food Chem* 48: 3396-3402.
- Rita Elkins MH 1997. Stevia Nature's Sweeteners. Woodland Publishing, Inc. (Web article) p. 1-29.
- Sadaf F, Saleem R, Ahmed M, Ahmad SI, Navaid ul Z 2006. Healing potential of cream containing extract of *Sphaeranthus indicus* on dermal wounds in Guinea pigs. *J Ethnopharmacol* 107: 161-163.
- Sasidharan S, Logeswaran S, Latha LY 2012. Wound healing activity of *Elaeis guineensis* leaf extract ointment. *Int J Mol Sci* 13: 336-347.
- Stephen YG, Emelia K, Francis A, Kofi A, Eric W 2010. Wound healing properties and kill kinetics of *Clerodendron splendens* G Don, A Ghanaian wound healing plant. *Pharmacog Res* 2: 63-68.
- Subhashini S, Arunachalam KD 2011. Investigations on the phytochemical activities and wound healing properties of *Adhatoda vasica* leave in Swiss albino mice. *Afric J Plant Sci* 5: 133-145.

- Tsuchiya H, Sato M, Miyazaki T, Fujiwara S, Tanigaki S, Ohyama M, Tanaka T, Iinuma M 1996. Comparative study on the antibacterial activity of phytochemical flavanones against methicillin-resistant *Staphylococcus aureus*. *J Ethnopharmacol* 50: 27-34.
- Vinothapooshan G, Sundhar K 2010. Wound healing effect of various extracts of *Adhatoda vasica*. *Int J Pharm Bio Sci I*: 530-536.
- Wild T, Rahbarnia A, Kellner M, Sobotka L, Eberlein T 2010. Basics in nutrition and wound healing. *Nutrition* 26: 862-866.

***Correspondence**

Kuntal Das
Department of Pharmacognosy and Phytochemistry, St. John's
College of Pharmacy, #6, Vijayanagar, Bangalore-560 040,
India.
sjpc@stjohns.edu.in
Tel: +919632542846
Fax: +918023350035