

Inter and intra-rater reliability of the scoliometer

Confiabilidade interavaliadores e intra-avaliador do escoliômetro

Guilherme H. Bonagamba¹, Daniel M. Coelho², Anamaria S. de Oliveira³

Abstract

Background: The scoliometer was developed to analyze the axial rotation of the trunk in patients with idiopathic scoliosis. However, there is controversy regarding the reliability of the measures obtained with this device. **Objective:** To test the intra-rater and inter-rater reliability of the scoliometer in patients with scoliosis. **Methods:** 24 volunteers of both sex with idiopathic scoliosis diagnostic (18 ± 4 years-old) and curvatures with mean and standard deviation of $24.8 \pm 12.7^\circ$ Cobb. The measurement procedure was accomplished in one day by two trained examiners. The palpation and determination of each spinal level was accomplished by just one examiner. Each examiner obtained one measure with the device for each vertebra from the thoracic and lumbar levels in each evaluation. For statistical analysis the measurements were divided by spinal levels into upper thorax, medium thorax, lower thorax and lumbar segments. The Intraclass Correlation Coefficient type 1,1 ($ICC_{1,1}$) was used to determine the intra-rater reliability while the $ICC_{3,1}$ was used to determine the inter-rater reliability. **Results:** The observed intra-rater reliability values for the medium and lower thorax and lumbar segments of the subjects ranged from very good to excellent. The inter-rater reliability of the measures of axial trunk rotations was considered good to the upper thorax and excellent for the medium and lower thorax and lumbar spine. **Conclusion:** The scoliometer is a device that has intra-rater reliability estimates ranging from very good to excellent. The inter-rater reliability for the upper and low thorax and for the lumbar spine is relatively lower than the intra-rater values for the same spinal segments, even when the errors from palpation and positioning of the instrument were eliminated.

Key-words: scoliosis; reproducibility of tests; evaluation studies; reliability.

Resumo

Contextualização: O escoliômetro foi desenvolvido para medir a rotação axial do tronco de portadores de escoliose idiopática. No entanto, a confiabilidade das medidas obtidas por esse dispositivo é controversa. **Objetivo:** Testar a confiabilidade interavaliadores e intra-avaliador do escoliômetro em pacientes com escoliose. **Métodos:** Foram avaliados 24 voluntários de ambos os sexos com escoliose idiopática (18 ± 4 anos), com curvaturas médias de $24,8 \pm 12,7^\circ$ Cobb. As medidas foram realizadas em um só dia e por dois examinadores treinados, com os níveis vertebrais demarcados por um só examinador. Os avaliadores registraram uma medida para cada vértebra dos níveis torácico e lombar em cada avaliação. Na análise dos dados, as medidas foram separadas em níveis vertebrais: torácico alto, torácico médio, torácico baixo e lombar. O ICC (1,1) foi o teste estatístico utilizado para determinar a confiabilidade intra-avaliador e o ICC (3,1), para a confiabilidade interavaliador. **Resultados:** A confiabilidade intraexaminador das medidas dos segmentos torácicos médio e baixo e lombar foi considerada de muito boa a excelente. A confiabilidade interexaminadores das medidas de rotação axial do tronco foi considerada boa para o segmento torácico alto e excelente para os segmentos torácicos médio e baixo e lombar. **Conclusões:** O escoliômetro é um instrumento que possui valores de confiabilidade de muito bons a excelentes para as medidas repetidas de um mesmo examinador. A confiabilidade interavaliadores nos segmentos torácicos médio e baixo e lombar em indivíduos com escoliose idiopática é relativamente menor que a medida intra-examinador, mesmo que sejam eliminados os erros de palpação e marcação do local de posicionamento do instrumento.

Palavras-chave: escoliose; reprodutibilidade dos testes; estudo de avaliação; confiabilidade.

Received: 23/07/2009 – Revised: 09/11/2009 – Accepted: 31/03/2010

¹Course of Physical Therapy, Faculdade de Medicina de Ribeirão Preto (FMRP), Universidade de São Paulo (USP), Ribeirão Preto (SP), Brazil

²Program of Post Graduation in Orthopedics, Traumatology and Rehabilitation

³Department of Biomechanics, Medicine and Rehabilitation of the Locomotor System

Correspondence to: Anamaria Siriani de Oliveira, Av. Bandeirantes, 3900, Vila Monte Alegre, CEP 14049-900, Ribeirão Preto (SP), Brasil, e-mail: siriani@fmrp.usp.br

Introduction

Scoliosis is a spinal deformity of a curvature of, at least, 5°. The prevalence of scoliosis ranges from 0.5% to 3.0% in the general population affecting mainly young adults and women^{1,2}. The diagnosis and clinical follow-up of idiopathic scoliosis are performed by anteroposterior radiography of the spine, in which the Cobb angle is measured, which is considered the gold standard measure for the diagnosis of scoliosis³.

Several attempts were made in order to validate some methods of scoliotic curvature identification by non-radiological analysis. These methods emerged as an alternative to the radiographic evaluation method as it reduces exposure of patients who have scoliosis to excessive radiation, it is easier to evaluate in the clinic and it has a reduced cost, when compared to radiographic examination. Examples of these non-radiographic methods are the Moiré photograph^{4,6}, the Quantec System⁷, the electric goniometer⁸ and the scoliometer^{2,3,9-14}.

The scoliometer is a device similar to the inclinometer, in which there is a metal sphere inside a water recipient that indicates the angle of axial trunk rotation. The sphere can be dislocate on a range of 0-30° for both sides on an increasing unit scale, as shown in Figure 1. The scoliometer is positioned by the examiner, perpendicularly to the axial axis of the spine on the spinous processes of vertebrae in the same level of the marks regarding the center of the scoliometer^{9,12}.

In the literature, there is no established correlation between values of axial trunk rotation observed by the evaluation with the scoliometer and their corresponding values for Cobb angles. The reference value obtained with the scoliometer, as suggested by its creator, for characterization of scoliotic curvature of at least 10° Cobb is, at least, 5° to either sides¹². Amendt et al.² suggest that values of axial trunk rotation of 7° to 10° correspond to scoliosis of, at least, 20° Cobb.

Some studies were conducted on subjects with scoliosis, predominantly female, aged between 15 and 37 years, in order to determine the reliability of the scoliometer^{2,3,9,10,13}. In two studies, the scoliometer showed excellent inter-rater and intra-rater reliability estimates and, therefore, was recommended as a reliable, practical and cheap device to use in clinical practice^{2,12}.

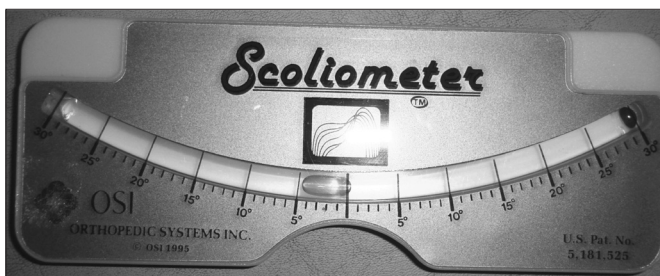


Figure 1. Scoliometer.

However, in one of these studies², statistical analysis was performed with the Pearson's "r" correlation coefficient, which is not the best statistical test used to analyze reliability, because it tends to overestimate association between the measures³.

Côté et al.³ and Murrell et al.⁹ found excellent values of intra-rater reliability, but low estimates of inter-rater reliability for the scoliometer due to low accuracy of the measure inherent to the measurement, which would limit the use of this instrument in clinical practice. In these studies, other procedures beyond the evaluation with the scoliometer were performed, such as the test of Adam and palpation and determination of the apical vertebra of the curvature of patients.

Since there is no description about the resting time between evaluations and the duration of all measurements performed, the patient could present discomfort due to the maintenance of posture adopted for the test and could present postural changes that could generate errors during the measurement procedure. Moreover, in all cited studies, the entire method of measurement with the scoliometer was tested, since each examiner performed the entire procedure, from positioning the patient to the documentation of the value of axial trunk rotation, and not only the analysis of reliability of the instrument alone^{2,3,9,10,13}.

The palpation of the spinous processes of the spine is an essential technique in the evaluation with the scoliometer. Some studies in the literature showed good inter-rater repeatability^{15,16} and excellent intra-rater repeatability of the technique¹⁵⁻¹⁷, both in thorax and in lumbar segments. They also state that if the palpation was carried out by a manual therapy specialist, repeatability is even better.

Given the above, the quantification of intra and inter-rater reliability of measures with a scoliometer is still described controversially in the literature and the aim of the present study was to test the inter-rater and intra-rater reliability of axial trunk rotation measures obtained with the scoliometer in patients diagnosed with idiopathic scoliosis.

Methods

Participants

Twenty-four volunteers of both sexes (2 men and 22 women) with a diagnosis of idiopathic scoliosis agreed to participate in this study and were evaluated. From the sample, four subjects had only simple scoliotic curvature at the thoracic level (16.7%); three, in the lumbar spine (12.5%) and five in the thoracolumbar transition (20.8%). Twelve volunteers had thoracolumbar double curve (50%). The mean age of the sample was 18 (± 4) years and the mean height was 1.60 (± 0.89) m; the

mean weight was 54.4 (\pm 9.4) kg; the mean BMI was 21.1 (\pm 3.0), and the mean Cobb angle was 24.8 \pm 12.7°.

An orthopedic physician specialist in spinal conditions performed the diagnosis of the deformity during the consultations. The diagnosis was confirmed from the patient's clinical history, physical examination and special tests and inspection of radiographs of the spine in anteroposterior view to obtain the values of the Cobb angle.

The participants of this study were recruited by convenience from the consultation list of the Clinic of Orthopedics and Spine of the Clinics Hospital of the Medicine School of Ribeirão Preto, Universidade de São Paulo (HCFMRP-USP), Ribeirão Preto (SP), Brazil, during the period from October 2006 to July 2007.

Subjects who previously underwent surgical treatment of spine or lower limb, who had length discrepancy of the lower limbs larger than 2.5 cm, which showed no idiopathic scoliosis or who presented antalgic scoliotic postures were excluded. The procedures performed in the study were explained and the consent form was provided for the subject or guardian, if the subject was younger than 18 years old. All subjects signed the consent form. The approval of the research protocol was granted by the Committee of Ethics in Human Research of the HCFMRP-USP, number 2439/2006, on August 28, 2006.

Procedures

The measurement procedure was performed by two examiners previously trained by an average of 10 hours with the scoliometer. Although there is no recommendation in the literature regarding the training time necessary for correct use of the instrument, 10 hours of training was considered sufficient by the examiners of this study for learning the evaluation method. The same scoliometer, developed by Ortophaedics Systems Incorporation®, was used by the examiners for the evaluation of all subjects in order to reduce the error associated with the measurement.

During the measurement, all subjects were barefoot. Female participants had their hair tied and were using a standard shirt that allowed the viewing of the entire back. Male subjects were evaluated shirtless. In order of not including the variability of identification by palpation of the spine levels as a variable in the study, the spinous process of each thoracic and lumbar vertebra of the spine, from T1 to L5, was identified by palpation with the subject in the standing position. The spinous processes were marked with dermographic pen by examiner 2, who had four years of experience working with manual therapy techniques.

The scoliometer is able to analyze, in degrees, the asymmetry and axial trunk rotation in the frontal plane, with the patient positioned with the trunk in anterior flexion¹². The patient should be placed in standing position, with bare

trunk, with trunk anteriorly flexed and almost parallel to the ground, with relaxed arms, hanging perpendicular to the trunk and hands folded, as shown in Figure 2. The value indicated by the metal sphere after placing the scoliometer over the spinous process is used to indicate the value of axial trunk rotation. Each examiner performed his measurement, which lasted approximately three minutes, without breaks. Examiners positioned the center of the device on the mark regarding the spinous process of each vertebra with the scoliometer perpendicular to the axial axis of the spine and measured the axial trunk rotation. Examiners had no access to the results of the other measures to avoid recall of the previous values.

Between each evaluation, the subject was instructed to leave the evaluation position to rest. Evaluation of rater 2 was made soon after the rest period, which had variable duration, according to the report of the patient. Between the first and second evaluation of rater 1, there were 15-20 minutes of interval, time when the evaluation of rater 2 was performed. Thus, two of the three evaluations, the first and last, were performed by rater 1 and one evaluation, the second, was performed by rater 2.

In each evaluation, the examiners evaluated once the 17 spinous processes from T1 to L5 from each of 24 subjects, totaling 408 measurements obtained at the end of each evaluation.

Data analysis and statistics

Measures of axial rotation performed on the 17 spinous processes (T1 to L5) were analyzed in categories according to four vertebral levels: upper thorax (T1 to T4), medium thorax (T5 to T8), lower thorax (T9 to T12) and lumbar (L1 to L5).

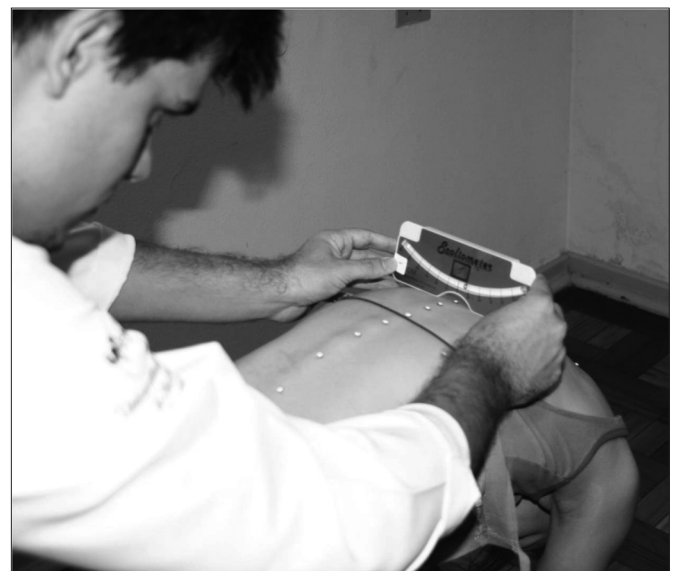

Figure 2. Evaluation performed with the scoliometer with the participant standing in trunk flexion.

The rotations to the left of the 0° mark of the scoliometer were recorded as negative, and the rotations located on the right of the center mark, as positive, in order to identify the side of the concavity of the curvature. However, values were considered in module or absolute values for reliability testing.

To determine inter-rater reliability, the measurements of each vertebral level obtained in the first evaluation of rater 1 and in the evaluation of rater 2, in the same segment, were subjected to statistical analysis using Intraclass Correlation Coefficient type 3,1 ($ICC_{3,1}$)¹⁸. To determine intra-rater reliability, the measurements of each vertebral level obtained in the first evaluation of rater 1 and in the second evaluation of the same rater, in the same segment were subjected to statistical analysis using ($ICC_{1,1}$)¹⁸. Measures of axial trunk rotation were also used to calculate the standard error and confidence interval.

For values ranging from 1.0 to 0.81, the reliability was considered excellent; from 0.80 to 0.61, very good; from 0.60 to 0.41, good; from 0.40 to 0.21, reasonable and, finally, from 0.20 to 0.00, poor¹⁸.

Results

The mean, standard error and confidence interval (CI=95%; $p < 0.0001$) of axial rotation values of the sample ($n=24$), by spine levels, are shown in Table 1.

Inter-rater and intra-rater reliability estimates for all segments of the spine to all subjects in the sample ($n=24$) are shown in Table 2.

The intra-rater reliability of axial trunk rotation measures measured by the scoliometer was considered excellent for the medium and lower thorax and lumbar segments ($ICC_{1,1}=0.87$ to 0.92) and very good for the upper thorax ($ICC_{1,1}=0.74$). The highest intra-rater reliability coefficients were obtained in measures of axial trunk rotation in the medium (T5-T8) and lower thorax segments (T9-T12).

The inter-rater reliability of axial trunk rotation measures was considered good ($ICC_{3,1}$ 0.57) for upper thorax segment and excellent for the medium and lower thorax and lumbar segments ($ICC_{3,1}$ 0.84 to 0.95).

Discussion

In the present study, the scoliometer showed to be a reliable device to evaluate the axial trunk rotation in vertebrae of patients with idiopathic scoliosis. However, the device proved to be more reliable if used by the same examiner in patients with idiopathic scoliosis in particular to evaluate curvatures in medium and lower thorax segments of the spine.

The intra-rater reliability was very good in the upper thorax segment, excellent in the medium and lower thorax and lumbar segments of the spine, and higher values were found for the medium and lower thorax segments of subjects, similar to results found by other authors^{2,3,9,12,14}. These results indicate that the scoliometer is a reliable device to measure axial trunk rotations of patients with idiopathic scoliosis in all segments of the spine, especially if the evaluation is performed by the same examiner and in the medium and lower thorax segments.

Regarding inter-rater reliability, excellent reliability values were observed for the medium and lower thorax and lumbar segments, while the upper thorax segment showed good reliability, since the error of determination of the vertebral level was not included as a variable.

The relatively lower values found for the inter-rater reliability in upper thorax segment may be due to the fact that, in the evaluated region, any accessory movement of cervical rotation of small-amplitude may generate postural compensation in the thoracic region. Thus, as the scoliometer is a device in which the value obtained depends on the oscillation of a metal sphere in the transverse plane, any placement of the upper thoracic vertebrae in rotation can generate a corresponding oscillation in the metallic sphere introducing bias in the measure obtained in the evaluation.

The palpation and the demarcation of vertebrae with dermatographic pen was performed only by rater 2, since it was not aimed at the reliability analysis of the complete method of measurement with the scoliometer, but the reliability of the device. This may have contributed to better estimates of inter-rater reliability for the medium and lower thorax segments, when compared to those previously reported in the literature.

In the study by Côté et al.³ the authors obtained estimates of inter-rater reliability of 0.91 for the thoracic level and 0.74 for the lumbar level, and the examiners reproduced the entire evaluation, from the patient positioning, determination of vertebrae and record of the measure with the scoliometer. In the study by Amendt et al.², the authors reported that the scoliometer was a highly reliable device in both inter and intra-rater analysis ($r=0.86$ to 0.97). However, the authors did not stratify the results by levels of the spine. Furthermore, in a previous study², the statistical test used to analyze the reliability of the scoliometer was the Pearson Correlation Coefficient, which tends to overestimate the association of data and increase the reliability values. The most appropriate statistical test for the reliability analysis is the ICC, because it presents an analysis of data association in a given interval³.

Table 1. Measures of axial trunk rotation determined with the scoliometer by two different examiners in 24 participants with idiopathic scoliosis.

Vertebrae Segment	Rater 1/ First assessment mean (standard error) (95% CI)	Rater 2/ Single assessment mean (standard error) (95% CI)	Rater 1/ Second assessment mean (standard error) (95% CI)
Upper Thorax (T1-T4)	3.5 (\pm 0.2) (2.9 to 4.0)	4.2 (\pm 0.3) (3.5 to 4.9)	3.6 (\pm 0.3) (3.0 to 4.3)
Medium Thorax (T5-T8)	4.2 (\pm 0.3) (3.4 to 4.9)	4.8 (\pm 0.4) (3.9 to 5.7)	4.3 (\pm 0.3) (3.7 to 5.0)
Lower Thorax (T9-T12)	5.3 (\pm 0.4) (4.4 to 6.2)	5.9 (\pm 0.4) (4.9 to 6.8)	5.3 (\pm 0.4) (4.5 to 6.2)
Lumbar (L1-L5)	2.9 (\pm 0.2) (2.7 to 3.7)	2.5 (\pm 0.2) (2.3 to 3.2)	2.8 (\pm 0.2) (2.6 to 3.5)

Data corresponding to mean (standard error) and 95% CI. Both assessments of rater 1 occurred between 15 and 20 minutes.

Table 2. Intra and inter-rater values of reliability found for the thorax and lumbar spine after evaluation of the scoliometer of 24 subjects with idiopathic scoliosis.

Vertebrae Segment	Inter-Rater Reliability	Intra-Rater Reliability
Upper Thorax (T1-T4)	0.57	0.74
Medium Thorax (T5-T8)	0.89	0.92
Lower Thorax (T9-T12)	0.95	0.92
Lumbar (L1-L5)	0.84	0.87

When comparing the results obtained in this study with those of others in which the palpation and determination of the spinous processes were included as variables^{2,3}, one can observe that the results found in the present study were similar or even better than those found in the literature when analyzing the inter-rater reliability for medium and lower thorax and lumbar levels. From this perspective, it can be inferred that the major sources of variability of the measurement performed with the scoliometer comes from the process of positioning, palpation and determination of the spinous process and not just the record of the measures of axial rotation with the device.

The variability of the measurements with the scoliometer observed between measurements of two examiners justifies the differences between the values of inter-rater and intra-rater reliability. This greater variability of inter-rater than intra-rater was also demonstrated in the study by Murrell et al.⁹

The inter-rater error is a measure associated with the precision of the device or examiner's error. The variability of measurements can be related to differences between the readings of examiners at the time of their respective evaluations, because, as the scoliometer presents inside a metallic sphere whose size is almost equal to the space between the marks of

angular units, and vertebral rotation is recorded at each level with an entire number, if the ball is positioned between two marks of the units, an examiner could evaluate the position of the sphere as an angle above, while the other examiner could adopt the position of the sphere differently and classify the axial rotation of the same vertebral one level below, thus generating variability.

One can see that although most evaluated regions showed excellent reliability measures, and the effect of palpation and determination of the place of measurement regarding the vertebral level was excluded from this study, the inter-rater measures of upper, medium and lower thorax segments should be interpreted with caution if the value of 5° of the scoliometer is chosen as indicative of a Cobb angle of 10°, which is the cut-off angle for diagnosing scoliosis¹². This is because, in this sample, the absolute error in these measures may be sufficient to change the value obtained by the scoliometer to reach out to the value of 5° and erroneously diagnose a subject, altering the sensitivity-specificity of this test.

The training time with the scoliometer performed by the examiners, of approximately 10 hours, was effective for learning the registration method of the device and may have contributed to the acquisition of good values of reliability. Based on the findings of our study, we suggest that this same time should be applied in studies of similar methodology.

Studies aimed to establish better values of the scoliometer, as an indicative of scoliosis diagnosis will be useful to define whether the scoliometer measurement error is critical or not to support its clinical applicability.

Study limitations

One factor that may have contributed to the excellent results of intra-rater and inter-rater reliability found was the performance of evaluations of both examiners in a single day and in periods of 20 minutes of intervals between the first and

last evaluation performed, because, since all the procedure was performed on the same day, variables such as pain, muscle discomfort, fatigue and emotional stress that can provide changes of postural alignment^{19,20}, were minimized.

Data from the present study evaluated the inter-rater repeatability of measures without considering the error that palpation performed by different examiners could add to errors obtained in the study. In addition, the scoliometer is a device that has the maximum amplitude of record of 0-30°, and as yet there is not a certain correspondence in the literature between the value found by the evaluation with the scoliometer and the corresponding value in Cobb degrees, there is no way to determine if the measurement error is critical to invalidate its diagnostic applicability.

Conclusion

The scoliometer is a device that has reliability values ranging from very good to excellent for repeated measurements of a single examiner. The inter-rater reliability of the measures of axial trunk rotation was considered good to the upper thorax segment and excellent to the medium and lower thorax and lumbar segments.

Further studies are needed in the literature to determine the reliability of the evaluation method of the scoliometer from palpation to the record of values of axial trunk rotation and if the measurement error becomes critical its clinical application for diagnosis.

References

- Kim HJ, Blanco JS, Widmann RF. Update on the management of idiopathic scoliosis. *Curr Opin Pediatr.* 2009;21(1):55-64.
- Amendt LE, Ause-Ellias KL, Eybers JL, Wadsworth CT, Nielsen DH, Weinstein SL. Validity and reliability testing of the scoliometer. *Phys Ther.* 1990;70(2):108-17.
- Côté P, Kreitz BG, Cassidy JD, Dzus AK, Martel J. A study of the diagnostic accuracy and reliability of the scoliometer and Adam's forward bend test. *Spine (Phila Pa 1976).* 1998;23(7):796-802.
- Daruwalla JS, Balasubramaniam P. Moiré topography in scoliosis. Its accuracy in detecting the site and size of the curve. *J Bone Joint Surg Br.* 1985;67(2):211-3.
- Stokes IA, Moreland MS. Concordance of back surface asymmetry and spine shape in idiopathic scoliosis. *Spine (Phila Pa 1976).* 1989;14(1):73-8.
- Denton TE, Randall FM, Deinlein DA. The use of instant moiré photographs to reduce exposure from scoliosis radiographs. *Spine (Phila Pa 1976).* 1992;17(5):509-12.
- Goldberg CJ, Kaliszer M, Moore DP, Fogarty EE, Dowling FE. Surface topography, Cobb angles, and cosmetic changes in scoliosis. *Spine (Phila Pa 1976).* 2001;26(4):E55-63.
- Mior SA, Kopansky-Giles DR, Crowther ER, Wright JG. A comparison of radiographic and electrogoniometric angles in adolescent idiopathic scoliosis. *Spine (Phila Pa 1976).* 1996;21(13):1549-55.
- Murrell GA, Coonrad RW, Moorman CT, Fitch RD. An assessment of the reliability of the scoliometer. *Spine (Phila Pa 1976).* 1993;18(6):709-12.
- Korovessis PG, Stamatakis MV. Prediction of scoliotic Cobb angle with the use of the scoliometer. *Spine (Phila Pa 1976).* 1996;21(14):1661-6.
- Sapkas G, Papagelopoulos PJ, Kateros K, Koundis GL, Boscainos PJ, Koukou UI, et al. Prediction of Cobb angle in idiopathic adolescent scoliosis. *Clin Orthop Relat Res.* 2003;411:32-9.
- Bunnell WP. An objective criterion for scoliosis screening. *J Bone Joint Surg Am.* 1984;66(9):1381-7.
- Grivas TB, Vasilidiadis ES, Koufopoulos G, Segos D, Triantafyllopoulos G, Mouzakis V. Study of trunk asymmetry in normal children and adolescents. *Scoliosis.* 2006;30:1-19.
- Kuklo TR, Potter BK, Polly DW Jr, O'Brien MF, Schroeder TM, Lenke LG. Reliability analysis for manual adolescent idiopathic scoliosis measurements. *Spine (Phila Pa 1976).* 2005;30(4):444-54.
- Downey BJ, Taylor NF, Niere KR. Manipulative physiotherapists can reliably palpate nominated lumbar spinal levels. *Man Ther.* 1999;4(3):151-6.
- Christensen HW, Vach W, Vach K, Manniche C, Haghfelt T, Hartvigsen L, et al. Palpation of the upper thoracic spine: an observer reliability study. *J Manipulative Physiol Ther.* 2002;25(5):285-92.
- Billis EV, Foster NE, Wright CC. Reproducibility and repeatability: errors of three groups of physiotherapists in locating spinal levels by palpation. *Man Ther.* 2003;8(4):223-32.
- Weir JP. Quantifying test-retest reliability using the intraclass correlation coefficient and the SEM. *J Strength Cond Res.* 2005;19(1):231-40.
- Troyanovich SJ, Harrison DE, Harrison DD. Structural rehabilitation of the spine and posture: rationale for treatment beyond the resolution of symptoms. *J Manipulative Physiol Ther.* 1998;21(1):37-50.
- Smith A, O'Sullivan P, Straker L. Classification of sagittal thoraco-lumbo-pelvic alignment of the adolescent spine in standing and its relationship to low back pain. *Spine (Phila Pa 1976).* 2008;33(19):2101-7.