

Vulvar Hemangioma: Case Report

Hemangioma vulvar: Relato de caso

Janine Medeiros da Silva¹ Emily Ramos Calife¹ João Victor de Sousa Cabral¹
Hildemárzio Pinheiro Falcão de Andrade¹ Ana Katherine Gonçalves¹

¹Department of Gynecology and Obstetrics, Universidade Federal do Rio Grande do Norte, Natal, RN, Brazil

Rev Bras Ginecol Obstet 2018;40:369–371.

Address for correspondence Ana Katherine da Silveira Gonçalves, Universidade Federal do Rio Grande do Norte, Rua Major Laurentino de Moraes 1218-1301, 59020-390, Natal, RN, Brazil (e-mail: anakatherine_ufrnet@yahoo.com.br; anakatherine@ufrnet.br; ana.katherine@pq.cnpq.br).

Abstract

Hemangioma is a benign neoplasm that may affect the vulva, and it can cause functional or emotional disability. This article reports the case of a 52-year-old female patient with a history of a genital ulcer for the past 3 years and who had undergone various treatments with creams and ointments. The patient was biopsied and diagnosed with vulvar hemangioma and was subsequently submitted to surgical excision of the lesion. We emphasize the importance of following the steps of the differential diagnosis and proceeding with a surgical approach only if necessary.

Keywords

- ▶ ulcer
- ▶ vulvar neoplasms
- ▶ hemangioma
- ▶ biopsy

Resumo

O hemangioma é uma neoplasia benigna que pode afetar a vulva e pode causar incapacidade funcional ou emocional. Este artigo relata o caso de uma paciente de 52 anos com história de úlcera genital nos últimos 3 anos, submetida a diversos tratamentos com cremes e pomadas. A paciente foi biopsiada e diagnosticada com hemangioma vulvar e subsequentemente submetida a excisão cirúrgica da lesão. Ressaltamos a importância de seguir as etapas do diagnóstico diferencial e proceder a uma abordagem cirúrgica somente se necessário.

Palavras-chave

- ▶ úlcera
- ▶ neoplasias vulvares
- ▶ hemangioma
- ▶ biópsia

Introduction

Hemangiomas are proliferative soft-tumor lesions marked by increased cell turnover. They are the product of a derangement in angiogenesis that allows for the unsuppressed proliferation of vascular elements. These tumors usually appear after birth, grow rapidly and involute over the years.¹ A total of 60% of hemangiomas are situated in the cervicofacial region.² The remaining section can occur at various locations in the body, including the vulva. However, vascular tumors are rarely found in the female genital tract.³ In fact, the female genital tract is an unusual location for hemangiomas, they are seldom found in this site.^{3–5} Therefore, there are very few reports on the condition on the literature.⁴

Although rare, we must be aware of the diagnosis of hemangiomas in the inferior female genital tract, as they might be a reason for a gynecologic consultation³ and can cause functional or emotional disability.⁴ We report here a rare case of a vulvar hemangioma that presented as a genital ulcer causing functional impairment and bleeding.

Case Report

The patient is a 52-year-old female, married, self-employed, non-smoker, with prediabetes, dyslipidemia and premenopausal, with no use of hormonal contraception. The patient reported a genital lesion for the past 3 years and the use of various treatments involving creams and ointments, even though there was no diagnosis associated with dyspareunia

received
February 24, 2018
accepted
April 16, 2018

DOI <https://doi.org/10.1055/s-0038-1657786>.
ISSN 0100-7203.

Copyright © 2018 by Thieme Revinter
Publicações Ltda, Rio de Janeiro, Brazil

License terms



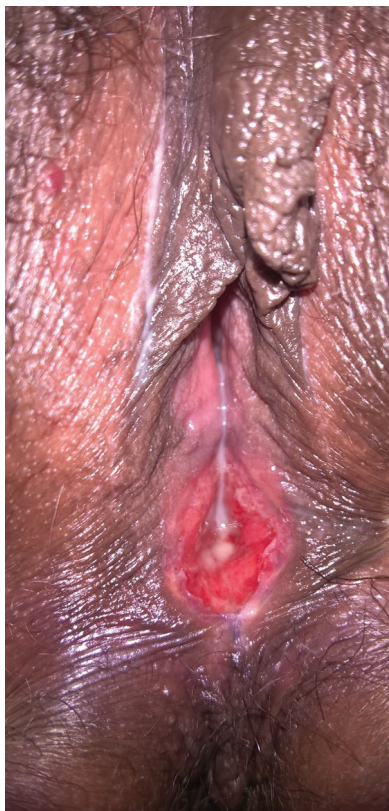

Fig. 1 Examination of the vulva with a lesion between the vaginal vestibule and the perineal region.

and intermittent bleeding. Physical examination revealed a solitary vulvar ulcer (►**Fig. 1**). The cervix had no abnormalities according to the colposcopy. No abnormalities were present in the routine blood tests and examinations of the patient. Initially, the investigation began by discarding all possible infectious causes of genital ulcers, such as syphilis, herpes and chancroid, which all proved to be negative.

There was suspicion of a manifestation of Behcet disease; therefore, we initiated the treatment with systemic corticosteroids. The first response was partial, the patient presented a decrease in the itching and burning sensations, but the bleeding did not cease. Furthermore, the pathology test result was negative. Due to the patient complaints of pain and sexual dysfunction, it was decided to conduct a surgical excision of the lesion. The biopsy examination showed a proliferation of tortuous vessels in the submucosa (►**Fig. 2**) and thus, the pathological diagnosis was reported as a hemangioma.

Discussion

The patient presented a hemangioma, which was clinically manifested as a bleeding ulcer. In fact, the hemangioma can manifest as an ulceration and bleed, both occurring most often in younger patients.⁵ Vulvar hemangiomas can cause functional and emotional disability,⁴ pain, cosmetic problems, and sexual dysfunction,⁵ the last three of which were complaints from our patient. For this reason, it is important to diagnose it correctly and to treat it adequately.

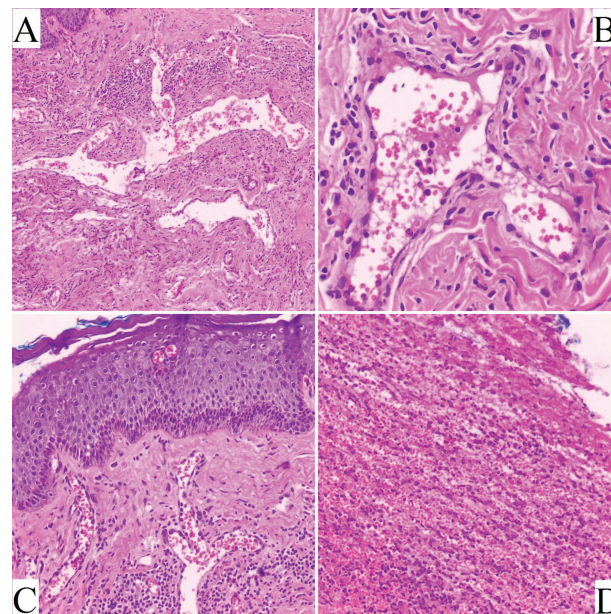


Fig. 2 This figure shows a proliferation of tortuous vessels in the submucosa, with variation in size. (A) Detail of a tortuous vessel and its endothelial lining formed by a single layer of some flattened cells. Some more swollen, without nuclear atypia. (400x magnification). (B) Some of them are larger and full of erythrocytes, while others are smaller and located in the periphery. (400x magnification). (C) Field of observation demonstrating the superficiality of these tortuous vessels and their close relation to the mucosa (stratified squamous epithelium). (200x magnification). (D) Nude area (without epithelial lining) composed of acute inflammatory cells (polymorphonucleated), chronic (lymphocytes and plasma cells) and erythrocytes, characterizing ulcerated lesion. (100x magnification). All using hematoxylin-eosin staining.

In this case, the first manifestation was a red, painful and persistent lesion followed by an ulcer complicated by life-threatening hemorrhage that was not responsive to conventional treatments and which showed no signs of involution for more than 3 years. Despite the negative evidence, over this time, an appropriated gynecological exam had been realized as well as the syndromic management, which is recommended by the Brazilian Ministry of Health. However, no final diagnostic was obtained, and no satisfactory results were observed.

The syndromic management of genital ulcers is recommended as an initial treatment, given the number of differential diagnoses and the practical difficulties in establishing a clear-cut etiologic diagnosis. It is prudent for healthcare providers to initially consider every female genital ulcer as a sexually transmitted disease (STD), which are: syphilis, chancroid, lymphogranuloma venereum, donovanosis and genital herpes.⁶

Therefore, our approach was to initially screen the patient for STDs; these all proved to be negative, which excluded these diseases from our differential diagnoses. Even with proper laboratory analysis, no pathogen is found in up to 25% of the patients with genital ulcers.⁷

Continuing the investigation of the etiology of the ulcer, we considered that it could be caused by a non-sexually transmitted disease,⁶ such as Behcet disease.⁸ Considering the possibility of this vasculitis, we performed a systemic

corticosteroid treatment. However, there was no complete regression of symptoms. Subsequently, the biopsy of an ulcer, which did not respond to initial therapy, was the recommended course of action.^{6,9} Therefore, with the biopsy of the patient's ulcer, it was possible to reach a definite diagnosis of vulvar hemangioma (–Fig. 2).

As most hemangiomas present spontaneous involution, treatment may be reserved for lesions that present complications, such as functional impairment, pain, ulceration, and bleeding, as the ones presented by our patient; however, there are others, like unusually rapid growth, infection, and cosmetic concerns.² In our case, the discomfort of our patient with her symptoms and her sexual dysfunction led to our decision to treat her.

The initial approach in our case was a conservative treatment with systemic corticosteroids to minimize the inflammatory process, as we assumed we were dealing with a manifestation of Behcet disease. Fortunately, these medications are effective in inducing rapid involution in massive hemangiomas. The success rate varies from 30 to 90%.² The therapy was based on daily doses of Prednisone 20 mg. The patient responded partially with a significant improvement in the itching and burning symptoms. However, the ulcer did not involute as expected, and she was still suffering from bleeding and dyspareunia.

It is important to highlight that during this period, the biopsy was suggested and refused by the patient, who accepted it only upon knowledge that it could be a malignant neoplasm.

The surgical excision of hemangiomas of the female genitalia is reserved for symptomatic lesions refractory to medical management.¹⁰ The procedure was performed for a curative purpose, to exclude malignancy and to obtain a definite diagnosis. A circular excision and purse-string closure are considered the best surgical approach for hemangiomas.¹¹ The resection of the lesion and reconstruction of the minor labia eliminated the symptoms and provided the cosmetic improvement required by the patient. A definite diagnosis of hemangioma was reached after pathological examination of the lesion. The proliferation of large vessels full of erythrocytes in the submucosa, involving the dermis are pathognomonic of hemangioma and excluded the possibility of being an ordinary inflammatory process (–Fig. 2-A). A second surgical approach was necessary in this case because of a residual vulvar lesion. The biopsy and histological examination of this tissue were compatible with a Bartholin cyst

Vulvar hemangioma is an extremely rare pathology in adults; however, infantile hemangioma is one of the most common benign soft-tissue tumors in infants. The treatment of infantile hemangiomas has been changing from surgical incision to the use of oral corticosteroids, cryosurgery, laser, radiation, propranolol, and anticancer drugs vincristine and bleomycin.^{12–14}

More recent reports also suggest alternative modalities for the treatment of this disease, such as the use of curcumin, indicating that the effectiveness of curcumin in hemangioma may be associated with its potent antiproliferative and apoptotic activities in hemangioma endothelial cells.¹⁵

Conclusion

To conclude, this case represents a rare situation of a vulvar hemangioma that presented as a genital ulcer, associated with psychological and physical dysfunction for the patient. The symptoms of itching, pain and sexual impairment were significant, and the delay in the diagnosis and resolution of the problem were a source of distress for the patient and her husband. We emphasize the importance of following the steps of the differential diagnosis and proceeding with a surgical approach only if necessary.

Conflicts of Interest

The authors have no conflicts of interest to declare.

References

- Gontijo B, Silva CMR, Pereira LB. Hemangioma da infância. *An Bras Dermatol* 2003;78:651–673. Doi: 10.1590/S0365-05962003000600002
- Gampper TJ, Morgan RF. Vascular anomalies: hemangiomas. *Plast Reconstr Surg* 2002;110(02):572–585, quiz 586, discussion 587–588
- Petite VV, Chitale SV, Godbole RN, Bidaye SV. Hemangioma of the ovary—a case report and review of literature. *Indian J Pathol Microbiol* 1991;34(04):290–292
- Bava GL, Dalmonte P, Oddone M, Rossi U. Life-threatening hemorrhage from a vulvar hemangioma. *J Pediatr Surg* 2002;37(04):E6. Doi: 10.1053/jpsu.2002.31645
- Cebesoy FB, Kutlar I, Aydin A. A rare mass formation of the vulva: giant cavernous hemangioma. *J Low Genit Tract Dis* 2008;12(01):35–37. Doi: 10.1097/LGT.0b013e3181255e85
- Workowski KA, Bolan GA; Centers for Disease Control and Prevention. Sexually transmitted diseases treatment guidelines, 2015. *MMWR Recomm Rep* 2015;64(RR-03):1–137
- Low N, Broutet N, Adu-Sarkodie Y, Barton P, Hossain M, Hawkes S. Global control of sexually transmitted infections. *Lancet* 2006;368(9551):2001–2016. Doi: 10.1016/S0140-6736(06)69482-8
- Alpsoy E, Er H, Durusoy C, Yilmaz E. The use of sucralfate suspension in the treatment of oral and genital ulceration of Behçet disease: a randomized, placebo-controlled, double-blind study. *Arch Dermatol* 1999;135(05):529–532. Doi: 10.1001/archderm.135.5.529
- Workowski KA. Centers for Disease Control and Prevention sexually transmitted diseases treatment guidelines. *Clin Infect Dis* 2015;61(Suppl 8):S759–S762. Doi: 10.1093/cid/civ771
- Vogel AM, Alesbury JM, Burrows PE, Fishman SJ. Vascular anomalies of the female external genitalia. *J Pediatr Surg* 2006;41(05):993–999. Doi: 10.1016/j.jpedsurg.2005.12.069
- Circular excision of hemangioma and purse-string closure: the smallest possible scar. *Arch Facial Plast Surg* 2003;5(01):117
- Gontijo B. Complications of infantile hemangiomas. *Clin Dermatol* 2014;32(04):471–476. Doi: 10.1016/j.clindermatol.2014.02.002
- Hartzell LD, Buckmiller LM. Current management of infantile hemangiomas and their common associated conditions. *Otolaryngol Clin North Am* 2012;45(03):545–556, vii
- Xiao Q, Li Q, Zhang B, Yu W. Propranolol therapy of infantile hemangiomas: efficacy, adverse effects, and recurrence. *Pediatr Surg Int* 2013;29(06):575–581. Doi: 10.1007/s00383-013-3283-y
- Lou S, Wang Y, Yu Z, Guan K, Kan Q. Curcumin induces apoptosis and inhibits proliferation in infantile hemangioma endothelial cells via downregulation of MCL-1 and HIF-1 α . *Medicine (Baltimore)* 2018;97(07):e9562. Doi: 10.1097/MD.0000000000009562