

Relato de Caso / Case Report

## Acute myeloid leukemia with t(8;21)(q22;q22) preceded by breast granulocytic sarcoma

*Leucemia mielóide aguda com t(8;21)(q22;q22) precedido de sarcoma granulocítico na mama*

Francisco D. Rocha Filho<sup>1</sup>

Gabrielle G. Lima<sup>2</sup>

Francisco V. Ferreira<sup>1</sup>

Nadjane B. A. Miranda<sup>3</sup>

Franklin J. C. Santos<sup>3</sup>

Andrea A. Vieira<sup>3</sup>

Nidia C. Messias<sup>1</sup>

*Granulocytic sarcoma (GS) is a rare extramedullary tumor mass composed of immature cells derived from the hematopoietic myeloid series. It is usually associated with leukemia and other myeloproliferative disorders but can also occur without overt hematologic diseases. The breast has been reported to be an uncommon site of presentation. We report a case of acute myeloid leukemia preceded by GS of the breast. The immunohistochemistry revealed myeloperoxidase, CD68 and CD43 positivity, thus indicating a diagnosis of GS. Conventional cytogenetic analysis of peripheral blood cells showed t(8;21)(q22;22). Complete remission was achieved with Daunorubicin and Cytarabine induction therapy followed by three courses of high-dose Cytarabine consolidation. The patient remains in continuous complete remission at 27 months. Rev. Bras. Hematol. Hemoter. 2008;30(5):423-425.*

**Key words:** Granulocytic sarcoma; breast; acute myeloid leukemia.

### Introduction

Acute myeloid leukemia (AML) with t(8;21)(q22;q22) creating the AML I/ETO fusion gene is a distinct type of AML generally associated with a favorable prognosis and, in particular, with good response to chemotherapy with cytosine arabinoside.<sup>1</sup> Tumor manifestations, such as granulocytic sarcoma, may be present at onset.<sup>2</sup> Granulocytic Sarcoma, as extramedullary immature myeloid cell proliferation, has been observed in patients with AML, chronic myelogenous leukemia, myelofibrosis with myeloid metaplasia, polycythemia vera, and in the absence of an antecedent myeloproliferative disorder. Isolated granulocytic sarcoma of the breast in the absence of a clinical history of hematological abnormalities is exceedingly rare.<sup>4,5</sup> We present a case of an isolated breast tumor with the subsequent development of AML with t(8;21)(q22;q22). Immuno-

histochemical studies are extremely helpful in recognizing myeloid sarcoma.

### Case report

A 22-year-old woman presented with a 2 cm firm to hard lump in the upper quadrant of her left breast, which grew to 12 cm in five months. Left lateral mammography disclosed hyperdense, spiculated mass 12 cm in diameter with irregular margins and without skin retraction. An ultrasound scan showed a non-homogenous hypoechoic mass with areas of increased echogenicity, irregular in shape with ill-defined margins and bone lytic involvement of the left humerus. Morphological examination of breast mass revealed undifferentiated neoplasm, probably sarcoma. In the first hematological examination the patient had a normal complete blood test. The patient was treated with

<sup>1</sup>Médico(a) patologista.

<sup>2</sup>Acadêmica de Medicina.

<sup>3</sup>Médica(o) hematologista.

Instituto do Câncer do Ceará – Fortaleza-CE

**Correspondência:** Gabrielle Gurgel Lima  
Instituto do Câncer do Ceará – Laboratório de Patologia  
Rua Papi Júnior, 1222 – Bairro Rodolfo Teófilo  
60430-230 – Fortaleza-CE – Brasil  
Tel.: 55 85 32884400; Fax: 55 85 32812865  
E-mail: gabi\_gurgel@yahoo.com.br

chemotherapy but without complete response. After one month the peripheral blood picture and bone marrow aspiration cytology showed 65% and 76% of blastic myeloid cells, respectively. By cytofluorimetric analysis the blasts cells expressed CD33, CD13 and CD19 antigens. An immunohistochemical study performed on paraffin-embedded sections showed that >90% of the neoplastic cells were positive for myeloperoxidase, CD68 and CD43 but were negative for CD20 (B-cells), CD45 (common leukocytic antigen) and cytokeratin. Conventional cytogenetic analysis of peripheral blood cells showed t(8;21)(q22;22) (Figure 1). Complete remission was achieved with Daunorubicin and Cytarabine induction therapy followed with three courses of high-dose Cytarabine consolidation. The patient remains in continuous complete remission at 27 months.

**Discussion**

Granulocytic sarcoma (GS) is a rare solid tumor composed of primitive precursors of the granulocytic series of white blood cells that include myeloblasts, promyelocytes, and myelocytes. GS can occur during either leukemia relapse or remission and may also, occasionally, be a complication in the course of chronic myeloid leukemia or other myeloproliferative disorders.<sup>2,3</sup> The breast has been reported to be an uncommon site for granulocytic sarcoma, principally without manifestation of acute leukemia, and may be misdiagnosed mainly as a lymphoma, carcinoma or undifferentiated mesenchymal tumor.<sup>5-9</sup> The diagnosis of GS requires the high index of suspicion of pathologists.<sup>5</sup> Primary breast GS is misdiagnosed most frequently as lymphoma or sarcoma.<sup>5,10</sup> In our case, the initial diagnosis


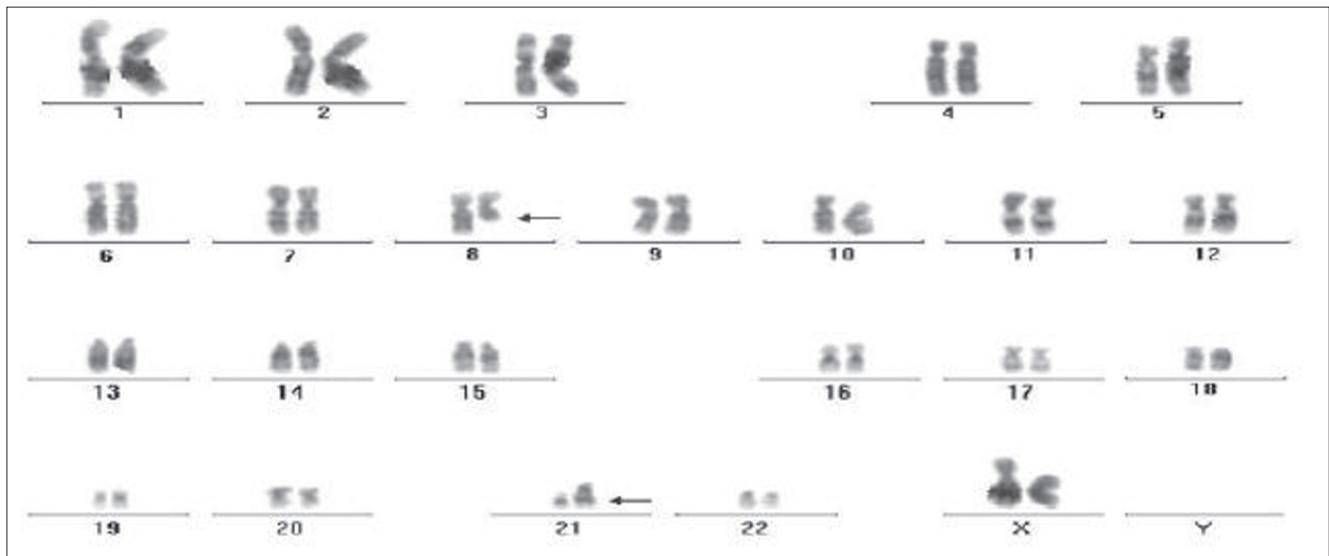


Figure1. A full karyotype 46,XX, t(8;21) (q22;q22) is shown. Arrows point to chromosomes involved in the translocation

was sarcoma. It was only after an immunohistochemistry test was performed, which revealed an expression of myeloperoxidase that a diagnosis of granulocytic sarcoma was reached. AML with the t(8;21)(q22;22) is usually preceded by GS and generally associated with a favorable prognosis.<sup>1</sup> This translocation occurs in 6 to 12 percent of patients with AML and usually predicts a good response to chemotherapy, with a high remission rate and a relative long median survival.<sup>2,11</sup> In the current case the patient showed complete remission after chemotherapy, with the breast tumor disappearing on mammography and ultrasound scan images. These data confirm the reports of other authors.<sup>12</sup>

## Conclusion

GS with isolated masses involving the breast is uncommon and may be misdiagnosed, mainly as a lymphoma or carcinoma, especially in the absence of bone marrow involvement. The association with t(8;21)(q22;22) is more common than generally recognized. Combined immunophenotypic and karyotypic approaches contribute to detect particular cases that have high chemotherapy rate sensitivity and a durable remission.

## Resumo

*Sarcoma granulocítico (GS) é um raro tumor extramedular composto de células imaturas derivadas das linhagens hematopoiéticas mielóides. É geralmente associada à leucemia ou outras desordens mieloproliferativas, mas também pode ocorrer sem manifestação de doenças hematológicas. A mama tem sido relatada como local incomum de apresentação. Relatamos um caso de leucemia mielóide aguda precedida por GS da mama. A imunohistoquímica revelou mieloperoxidase, CD68 e CD43 positivos, indicando um diagnóstico da GS. A análise citogenética convencional de células de sangue periférico mostrou t(8; 21)(q22; 22). Remissão completa foi atingida com indução terapêutica com daunorubicina e citarabina, seguida de três ciclos de alta dose de citarabina. O paciente permanece em completa remissão há 27 meses. Rev. Bras. Hematol. Hemoter. 2008;30(5):423-425.*

**Palavras-chave:** Sarcoma granulocítico; mama; leucemia mielóide aguda.

## References

- Huang L, Abruzzo LV, Valbuena JR, Medeiros LJ, Lin P. Acute myeloid leukemia associated with variant t(8;21) detected by conventional cytogenetic and molecular studies: a report of four cases and review of the literature. *Am J Clin Pathol.* 2006; 125(2):267-72.
- Jaffe ES, Harris NL, Stein H, Vardiman JW. World Health Organization Classification of Tumours of Hematopoietic and Lymphoid Tissues. IARC Press: Lyon, France, 2001, pp 77-107.
- Guermazi A, Feger C, Rousselot P, Merad M, Benchaib N, Bourrier P, et al. Granulocytic sarcoma (chloroma): imaging findings in adults and children. *AJR Am J Roentgenol.* 2002;178(2):319-25.

- Ngu IW, Sinclair EC, Greenaway S, Greenberg ML. Unusual presentation of granulocytic sarcoma in the breast: a case report and review of the literature. *Diagn Cytopathol.* 2001; 24(1):53-7.
- Dutta Roy S, Stafford JS, Scally J, Selvachandran SN. Granulocytic sarcoma of the breast antedating acute myelogenous leukemia. *Breast.* 2004;13(3):242-6.
- D'Costa GF, Hastak MS, Patil YV. Granulocytic sarcoma of breast: an aleukemic presentation. *Indian J Med Sci.* 2007;61(3):152-5.
- Joo M, Lee HK, Kang YK, Kim JH. Granulocytic sarcoma of the breast preceding acute myelogenous leukemia: a case report. *J Korean Med Sci.* 2000;15(4):457-9.
- Valbuena JR, Admirand JH, Gualco G, Medeiros LJ. Myeloid sarcoma involving the breast. *Arch Pathol Lab Med.* 2005;129(1):32-8.
- Quintas-Cardama A, Fraga M, Antunez J, Forteza J. Primary extramedullary myeloid tumor of the breast: a case report and review of the literature. *Ann Hematol.* 2003;82(7):431-4.
- Shea B, Reddy V, Abbitt P, Benda R, Douglas V, Wingard J. Granulocytic sarcoma (chloroma) of the breast: a diagnostic dilemma and review of the literature. *Breast J.* 2004;10(1):48-53.
- Sugimoto Y, Nishii K, Sakakura M, Araki H, Usui E, Lorenzo VF, et al. Acute myeloid leukemia with t(8;21)(q22;q22) manifesting as granulocytic sarcomas in the rhinopharynx and external acoustic meatus at relapse after high-dose cytarabine: case report and review of the literature. *Hematol J.* 2004;5(1):84-9.
- Nishida H, Kinoshita T, Yashiro N, Ikeda Y, O'Uchi T. MR findings of granulocytic sarcoma of the breasts. *Br J Radiol.* 2006;79(945):e112-5.

Avaliação: Editor e dois revisores externos

Conflito de interesse: não declarado

Recebido: 15/02/2008

Aceito após modificações: 14/03/2008