



Case report

Oral cancer after prolonged immunosuppression for multiorgan chronic graft-versus-host disease

Renata Lins Fuentes de Araújo, Karine de Fátima Lyko,
Vaneuza Araújo Moreira Funke, Cassius Carvalho Torres-Pereira*

Universidade Federal do Paraná (UFPR), Curitiba, PR, Brazil

ARTICLE INFO

Article history:

Received 10 June 2013

Accepted 2 August 2013

Keywords:

Mouth neoplasms

Bone marrow transplantation

Leukemia

Myeloid

Graft-versus-host disease

ABSTRACT

Long-term survivors of hematopoietic stem cell transplantation are recognized as a risk group for malignization. Malignant oral neoplasms are increasingly being reported in the literature as a consequence of lesions of chronic graft-versus-host disease, and prolonged multidrug treatment to control its manifestations. This report describes a 43-year-old patient who, after allogeneic bone marrow transplantation, developed an oral squamous cell carcinoma secondary to the use of azathioprine, cyclosporine, prednisone, and tacrolimus, associated with multiorgan chronic graft-versus-host disease involving the oral mucosa, skin, eyes, and liver. This report aims to discuss the possible role of immunosuppressant therapy for chronic graft-versus-host disease on the development of oral squamous cell carcinoma, and the relevance of a close oral follow-up of patients to detect dysplastic or malignant alterations at an early stage.

© 2014 Associação Brasileira de Hematologia, Hemoterapia e Terapia Celular. Published by Elsevier Editora Ltda. All rights reserved.

Introduction

Chronic myeloid leukemia (CML) is a clonal myeloproliferative disorder characterized by the presence of a reciprocal translocation between chromosomes 9 and 22 (Philadelphia chromosome), which leads to the appearance of a new hybrid gene (BCR-ABL) with tyrosine kinase activity. Current initial therapy is the administration of the tyrosine kinase

inhibitor, imatinib mesylate, but in some cases, particularly for refractory or advanced phase disease, hematopoietic stem cell transplantation (HSCT) can be indicated as a curative treatment. However, there is concern about late complications of this procedure, such as chronic graft-versus-host disease (cGVHD) and the development of malignancies secondary to radiotherapy, chemotherapy, and prolonged immunosuppressive treatment.^{1,2}

*Corresponding author at: Programa de Pós-Graduação em Odontologia e Departamento de Estomatologia, Universidade Federal do Paraná, Av. Lothário Meissner, 632, Jardim Botânico 80210-170, Curitiba, PR, Brazil.

E-mail address: cassius@ufpr.br (C.C.T. Pereira).

1516-8484/\$ - see front matter © 2014 Associação Brasileira de Hematologia, Hemoterapia e Terapia Celular. Published by Elsevier Editora Ltda. All rights reserved.

DOI: 10.5581/1516-8484.20140016

One of the most common late complications after HSCT is graft-versus-host disease (GVHD). Studies demonstrate that patients who develop cGVHD have higher risk of developing solid tumors such as oral squamous cell carcinoma (SCC), mainly because of the immunosuppressive treatment, which generally includes cyclosporine, tacrolimus, and corticosteroids.^{2,3}

The current report describes a patient with multiorgan cGVHD, who developed oral SCC after prolonged and combined immunosuppressant drug therapy.

Case report

In 2008, a 43-year-old Caucasian male patient was referred for an oral medical consultation from a bone marrow transplantation unit, with the chief complaint of widespread oral pain, mainly of the palate, and difficulty to open his mouth. In 1999, the patient had been diagnosed with CML and started treatment with hydroxyurea to control the leukocyte count. Three years later he started taking imatinib mesylate, which was maintained for 14 months. As there was no response to high doses of imatinib or its association with cytarabine, the patient was submitted to a HSCT in 2003. The cell donor was his sister and they were fully matched. The patient progressed with acute GVHD (aGVHD), followed by extensive multiorgan cGVHD. In 2004, the CML relapsed, despite severe cGVHD. At that time, there was no other available option and the patient returned to imatinib therapy (400 mg/day), which was maintained until 2009, with an unexpected complete molecular response.

An extra oral examination revealed diffuse hypochromic and hyperchromic skin lesions (Figure 1), and palpable submandibular and cervical lymph nodes. The oral examination revealed a very poor hygiene status, scleroderma with a severe limitation of mouth opening, severe mucosal atrophy and ulcerations, absence of tongue papillae, a pseudomembrane on the anterior third part of the left buccal mucosa, and an indurated retrocomissural ulcerated nodule of approximately 1 cm in diameter (Figure 2). The panoramic radiographic image showed residual root fragments and loose teeth (Figure 3).

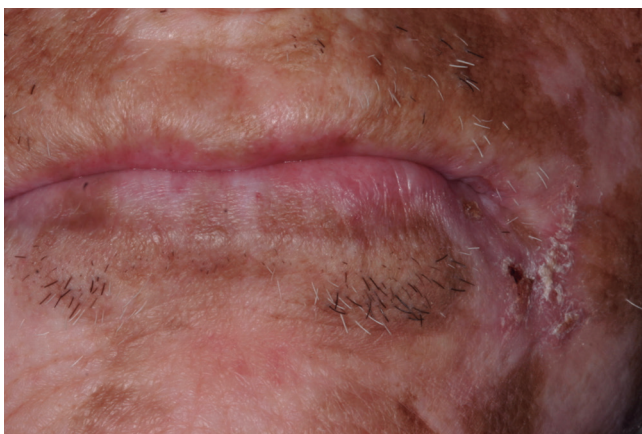

Figure 1 – Diffuse hypochromic and hyperchromic skin lesions characteristic of chronic cutaneous graft-versus-host disease.

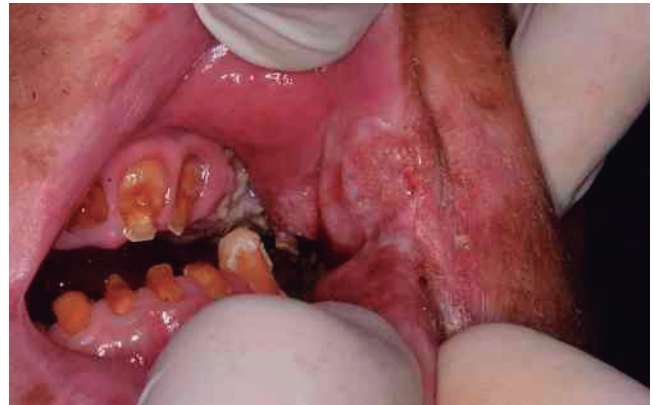

Figure 2 – Indurate and asymptomatic retrocomissural lesion. Poor oral hygiene was evident with multiple acute carious lesions, the accumulation of gross biofilm, gingivitis and restricted mouth opening.

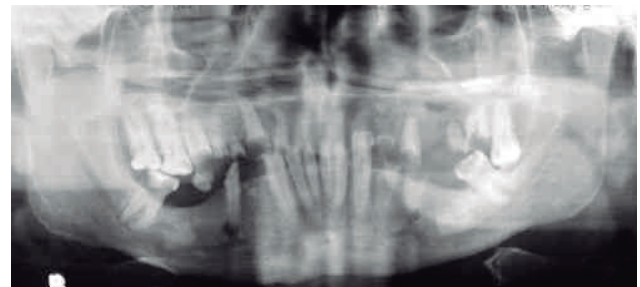


Figure 3 – Panoramic radiograph showing the poor dental status.

The patient was taking imatinib mesylate (400 mg/day), prednisone (20 mg) on alternate days, trimethoprim and sulfamethoxazole (TMP/SMX) (80/400 mg/day), tacrolimus (4 mg/day), azathioprine (100 mg/day), and morphine (240 mg/day). Information on drugs, dosage and time is summarized in Table 1.

Table 1 - Immunosuppressant treatment for acute and chronic graft-versus-host disease.

Year	Drug	Dosage	Prescription (days)
2003-2005	Cyclosporine ^a	200-800 mg	458
	Prednisone	> 5 mg/kg/day	708
2005	Mycophenolate mofetil	1 g	30
2006	Cyclosporine	300 mg	270
	Prednisone	> 5 mg/kg/day	240
	Azathioprine	100 mg	285
2007	Cyclosporine	300 mg	45
	Prednisone	> 5 mg/kg/day	345
	Azathioprine	100 mg	365
2008-2009	Tacrolimus	2-4 g	330
	Prednisone	> 5 mg/kg/day	395
	Azathioprine	100 g	395
	Tacrolimus	2-4 g	395

^a Dosage used to keep serum level between 200-400 mg/kg.

The patient was immediately prescribed non-alcohol chlorhexidine mouthwash to control oral biofilm, and an incisional biopsy was performed on the retrocomissural lesion under local anesthesia. The microscopic analysis revealed a well differentiated SCC, and the patient was promptly referred to a head and neck surgery referral center.

Discussion

GVHD is a common and important complication after HSCT; its prevalence is seen in between 25% and 80% in long-term survivors. The 5-year survival rate after HSCT is reported as being approximately 40% of patients with multisystem cGVHD.²⁻⁵ Cumulative evidence suggests that GVHD is an important risk factor for carcinogenesis, and this association has also been described for oral tissues.

In 1997, Curtis et al.,⁶ in a multi-institution database study of 19,229 patients, showed that cGVHD was associated to higher risk of SCC in the oral cavity after HSCT. All 16 cases of oral SCC registered were associated to GVHD, and 11 had received immunosuppressive drugs for two or more years. In that study, the most frequent site of SCC was the tongue, followed by the salivary glands, lips, and gingivae.

In a study with 2,129 patients who underwent HSCT, Bathia et al.⁷ found that the risk of solid cancers after transplant varies according to the primary diagnosis. Among hematologic malignancies, patients with a diagnosis of acute and chronic myeloid leukemia tended to have higher incidence of solid tumors than the general population, the risk being significantly higher for liver, oral cavity, and cervical cancers.

Other authors also stated that this high risk for oral SCC is a result of long-term immunologic injury to the oral mucosa by T-cells, and of immunodeficiency after prolonged drug use to control cGVHD. There is some speculation that oral tissue infections by viruses, particularly HPV, may also lead to the proliferation of cancer cells.^{2,4,8,9}

It is well accepted that tissue damage results from the reaction of donor T cells against host histocompatibility antigens (HLA); this is aggravated by other known risk factors for cGVHD, such as gender mismatch (female donor to a male recipient), severity of previous aGVHD, the donor age, and older recipient.^{2,9}

In the case described in this paper, the donor was female, and the host and donor were 35 and 38 years old, respectively at the time of HSCT. Moreover, the patient had an aggressive aGVHD 35 days after the HSCT, followed by multisystemic cGVHD, refractory to treatment.

Clinically, oral cGVHD resembles autoimmune disorders like *lichen planus*, *scleroderma*, and Sjögren's syndrome, and manifests in oral tissues as inflammation and erythema, hyperkeratotic lesions, atrophy, fibrosis with restricted mouth opening, depapillation of the tongue, hyposalivation, and pain.⁵

Although it is well recognized that patients have a higher risk of oral complications after HSCT, such as tooth decay, gingivitis, and periodontitis, the case presented herein showed a far more dramatic condition of poor oral health. The oral

mucosa had multiple ulcerations, lichenoid lesions, severe atrophy, and intense pain, which contributed to the lack of compliance to oral health hygiene measures.

As part of the immunosuppression treatment for his multiorgan cGVHD, the patient was initially prescribed cyclosporine and prednisone. The worsening of lesions led to the use of mycophenolate mofetil (MMF), also with poor response. Azathioprine and tacrolimus led to some improvements in the symptoms and manifestations (Table 1).

Some studies have shown that the combination of prolonged immunosuppressive treatment for cGVHD increases the risk for solid tumors, such as oral SCC. This finding is consistent with the case-control study (n = 24,000) by Curtis et al.,⁹ who identified increased risk for oral malignancy and other solid tumors in individuals who developed severe cGVHD, and were submitted to a long protocol of azathioprine (over 24 months). According to these authors, these are the main risk factors for the occurrence of skin and oral cavity SCC.³ These findings were also described in a large (n = 5,931) solid organ transplant study,¹⁰ reinforcing that treatment with azathioprine is strongly associated with the risk of cutaneous SCC after transplantation. The risk of malignancy increases with the dose and the duration of treatment. They also found that the triple treatment regimen of azathioprine + cyclosporine + corticosteroids increases the risk of cutaneous SCC in 5-fold, and a high accumulated dose of corticosteroids after prolonged treatment (three years) enhances the risk of cutaneous SCC in organ transplanted patients. This cumulative association, according to their findings, however, was not relevant for cyclosporine.

Immunosuppressive drugs are believed to cause SCC by a carcinogenic effect or by increasing the carcinogenic effect of other agents combined with its immunosuppressive effect.¹⁰ Azathioprine has been reported as a mutagenic agent, and associated to the promotion of secondary malignancies when used in cGVHD treatment. On the other hand, cyclosporine is not directly associated to an increased risk of SCC, but is believed to induce phenotypic changes, and promote tumor growth, including invasiveness.⁸

Due to the severity of his cGVHD and the limited availability of other therapeutic tools (extracorporeal photopheresis, sirolimus, etc.), our patient was on azathioprine for more than 34 months, cyclosporine for 26 months, and corticosteroids for 56 months, all of which are associated to an increased risk for SCC.

In this case, the presence of multiorgan cGVHD and prolonged immunosuppressive therapy are factors that could be related to the development of SCC. A periodic and thorough oral examination should be recommended for all long-term HSCT survivals, with special attention to individuals who manifest cGVHD, and those on long-term cumulative immunosuppressant therapy.

Conflicts of interest

The authors declare no conflicts of interest.

R E F E R E N C E S

1. Bacarani M, Dreyling M; ESMO Guidelines Working Group. Chronic myeloid leukaemia: ESMO clinical practice guidelines for diagnosis, treatment and follow-up. *Ann Oncol.* 2010;21(Suppl 5):165-67.
2. Kruse AL, Grätz KW. Oral carcinoma after hematopoietic stem cell transplantation – a new classification based on a literature review over 30 years. *Head Neck Oncol.* 2009;1-29.
3. Demarosi F, Lodi G, Carrassi A, Soligo D, Sardella A. Oral malignancies following HSCT: graft versus host disease and other risk factors. *Oral Oncol.* 2005;41(9):865-77.
4. Noguchi K, Nakase M, Inui M, Nakamura S, Okumura K, Tagawa T. A case of tongue carcinoma associated with chronic graft-versus-host disease after allogeneic haematopoietic stem cell transplantation. *Aust Dent J.* 2010;55(2):200-2.
5. Meier JK, Wolff D, Pavletic S, Greinix H, Gosau M, Bertz H, Lee SJ, Lawitschka A, Elad S; International Consensus Conference on Clinical Practice in cGVHD. Oral chronic graft-versus-host disease: report from the International Consensus Conference on clinical practice in cGVHD. *Clin Oral Investig.* 2011;15(2):127-39.
6. Curtis RE, Rowlings PA, Deeg HJ, Shriner DA, Socié G, Travis LB, et al. Solid cancers after bone marrow transplantation. *N Engl J Med.* 1997;336(13):897-904. Comment in: *N Engl J Med.* 1997;336(13):949-50; *N Engl J Med.* 1997;337(5):345-6.
7. Bhatia S, Louie AD, Bhatia R, O'Donnell MR, Fung H, Kashyap A, et al. Solid cancers after bone marrow transplantation. *J Clin Oncol.* 2001;19(2):464-71.
8. Arora M, Klein JP, Weisdorf DJ, Hassebroek A, Flowers ME, Cutler CS, et al. Chronic GVHD risk score: a Center for International Blood and Marrow Transplant Research analysis. *Blood.* 2011;117(24):6714-20. Comment in: *Blood.* 2011;117(24):6408-9.
9. Curtis RE, Metayer C, Rizzo JD, Socié G, Sobocinski KA, Flowers ME, et al. Impact of chronic GVHD therapy on the development of squamous-cell cancers after hematopoietic stem-cell transplantation: an international case-control study. *Blood.* 2005;105(10):3802-11.
10. Ingvar A, Smedby KE, Lindelöf B, Fernberg P, Bellocco R, Tufveson G, et al. Immunosuppressive treatment after solid organ transplantation and risk of post-transplant cutaneous squamous cell carcinoma. *Nephrol Dial Transplant.* 2010;25(8):2764-71.