

Images in Clinical Hematology

Chanarin-Dorfman Syndrome

Sheila de Oliveira Garcia¹

Aline de Lima Deolindo¹

Juliana Pereira²

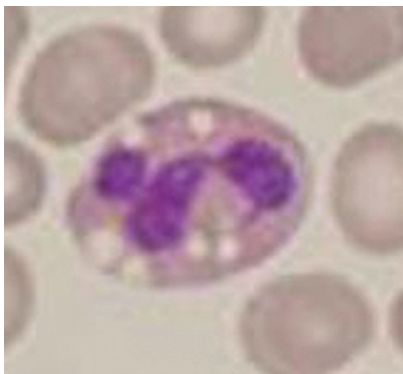

Figure 1. Large cytoplasmic lipid vacuoles in neutrophils suggesting Chanarin-Dorfman syndrome. Peripheral blood, stained with Leishman's stain: magnified 1000 x

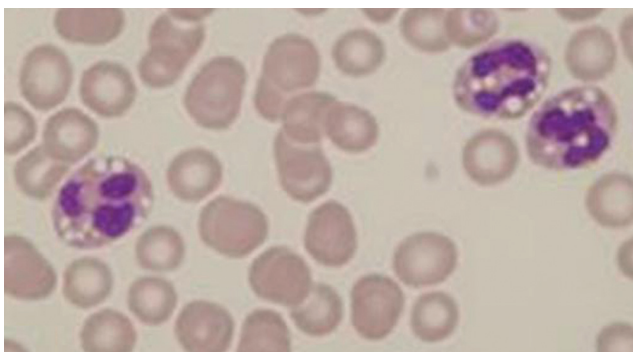


Figure 2. Prominent cytoplasmic vacuoles in neutrophils. Peripheral blood, stained with Leishman's stain: magnified 1000 x

Chanarin-Dorfman syndrome is a rare autosomal recessive disease characterized by the presence of intracellular lipid droplets in the cells of many different tissues, in particular in keratinocytes and granulocytes that may be associated with ichthyosis. Mutations in the gene that encodes the ABHD5 protein of the esterase/lipase/thioesterase subfamily have been identified as the main cause of the disorder. Extracutaneous manifestations are heterogeneous both in intensity and characteristics. Systemic involvement may include hepatosplenomegaly, double-sided cataracts, growth retardation, myopathy, ataxia and bilateral sensorineural hearing loss.⁽¹⁾ Since the first reports of the syndrome⁽¹⁾ only 30 patients have been described in the literature, mostly from Middle Eastern countries.⁽²⁾ The diagnosis is confirmed by the presence of lipid droplets in granulocytes of peripheral blood.⁽³⁾

Keywords: Ichthyosis; Lipid metabolism, inborn errors; Syndrome; Granulocytes

References

1. Dorfman ML, Hershko C, Eisenberg S, Sagher F. Ichthyosiform dermatosis with systemic lipidosis. *Arch Dermatol.* 1974;110(2): 261-4.
2. Peña-Penabad C, Almagro M, Martínez W, García-Silva J, Del Pozo J, Yebra MT, et al. Dorfman-Chanarin syndrome (neutral lipid storage disease): new clinical features. *Br J Dermatol.* 2001; 144(2):430-2. Review.
3. Lefèvre C, Jobard F, Caux F, Bouadjar B, Karaduman A, Heilig R, et al. Mutations in CGI-58, the gene encoding a new protein of esterase /lipase / thioesterase subfamily, in Chanarin-Dorfman syndrome. *Am J Hum Genet.* 2001;69(5):1002-12.

Submitted: 6/22/2010

Accepted: 7/16/2010

¹Faculdade de Medicina da Universidade de São Paulo – USP, São Paulo (SP), Brazil

²Hematology Service, Hospital das Clínicas da Faculdade de Medicina da Universidade de São Paulo – USP, São Paulo (SP), Brazil

Correspondence: Sheila de Oliveira Garcia

Faculdade de Medicina da Universidade de São Paulo

Av. Dr. Enéas Carvalho de Aguiar, 155 – 1º andar, bloco 4, sala 61, Laboratório de Imunopatologia – Cerqueira César

05403-000 – São Paulo (SP), Brasil

E-mail: sheilagarcia.hp@gmail.com