



## Letter to the Editor

# Histopathological evaluation of the bone marrow in refractory anemia with ring sideroblasts and thrombocytosis associated to the JAK2-V617F mutation

Dear Editor,

The myelodysplastic syndromes (MDS) are a group of clonal disorders of the hematopoietic stem cell, characterized by cytopenia(s), dysplasia of one or more of the myeloid lineages, ineffective hematopoiesis, and an increased risk of developing acute myeloid leukemia (AML).<sup>1</sup> Refractory anemia with ringed sideroblasts and thrombocytosis (RARS-T), is a provisional entity that, according to the World Health Organization (WHO), joined the group of myelodysplastic/myeloproliferative neoplasms (MDS/MPN).<sup>2</sup> The diagnostic criteria for RARS-T are the presence of persistent thrombocytosis (above  $600 \times 10^9/L$ ),  $\geq 15\%$  ringed sideroblasts, and  $< 5\%$  blasts in the bone marrow.<sup>3,4</sup> An acquired JAK2-V617F mutation, resulting in a substitution of valine for phenylalanine at codon 617 of the JAK2 gene, is reported in 90% of cases of Polycythemia vera (PV), and in about 50% of cases of myelofibrosis (MF), and essential thrombocythemia (ET).<sup>4</sup> The JAK2-V617F mutation is positive in about 60% of cases of RARS-T, and in a minority of cases in other subtypes of MDS/MPN.<sup>5</sup> Studies have evaluated the relationship between the state of the JAK2-V617F to morphological, clinical, and laboratory parameters, and survival in RARS-T,<sup>6</sup> suggesting that the mutation confers a favorable prognosis, and is associated with an increase in hemoglobin, decrease in mean corpuscular volume (MCV), and increases in leukocyte and platelet counts.

The figures below show the case of an 80-year-old JAK2-V617F-positive male patient with RARS-T and systemic hypertension, who was submitted to radiotherapy in 2007 for a prostate adenocarcinoma:

Myelogram: Dyserythropoiesis and dysmegakaryopoiesis above 10%; asynchrony of maturation and binucleation; presence of micromegakaryocytes and hypolobulated megakaryocytes; 1% of plasmocyte, and 81% ringed sideroblasts.

Bone marrow biopsy: hypercellular marrow disorder architecture, characterized by megaloblastoid erythroblasts, peripheral megakaryocytes, and a slight increase in the network of reticulin myelofibrosis (grade I). Cytogenetics revealed 46, XY karyotype. Immunohistochemical expression was p53 negative. Hematological parameters: hemoglobin: 7.8 g/dL; leukocyte count:  $7.740 \times 10^3/\mu L$  and platelet count: 949

$\times 10^3/\mu L$ . Figure 1 illustrates the presence of megakaryocytes with separate cores, along with a nuclear hyperchromasia and cane aspect in band, observed megaloblastoid erythroblasts distributed in a dispersed interstitial manner with hematopoietic marrow dysmegakaryopoiesis and dyserythropoiesis. Figure 2 illustrates a bone marrow biopsy with reticulin and interstitial condensation (grade I). The images show the relevance of the histopathological findings of the bone marrow biopsy in diagnosing this rare subtype of MDS.

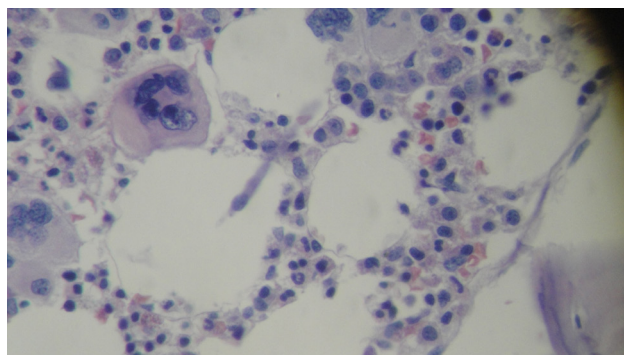


Figure 1 - Bone marrow with dysmegakaryopoiesis and dyserythropoiesis. Hematoxylin and eosin stain, original magnification 400 $\times$ .

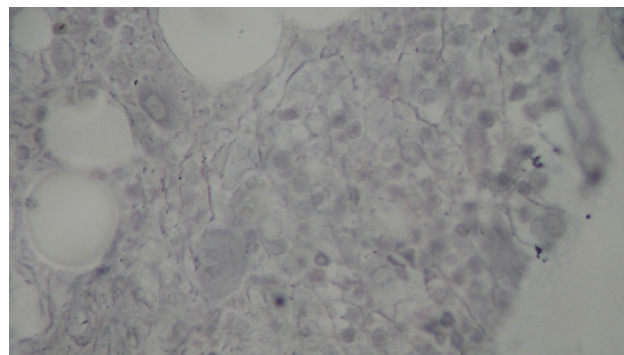


Figure 2 - Bone marrow biopsy with reticulin and interstitial condensation (grade I) Hematoxylin and eosin stain, original magnification 400 $\times$ .

---

## Conflicts of interest

The authors declare no conflicts of interest.

---

## REFERENCES

1. Corey SJ, Minden MD, Barber DL, Kantarjian H, Wang JC, Schimmer AD. Myelodysplastic syndromes: the complexity of stem-cell diseases. *Nat Rev Cancer*. 2007;7(2):118-29.
2. Steensma DP, Hanson CA, Tefferi A. Independent validation of the 2008 World Health Organization (WHO) reclassification of myelodysplastic syndromes (MDS) associated with ring sideroblasts, 50th ASH Annual Meeting and Exposition, 2008, San Francisco, Abstract 2686.
3. Gurevich I, Luthra R, Konoplev SN, Yin CC, Medeiros LJ, Lin P. Refractory anemia with ring sideroblasts associated with marked thrombocytosis: a mixed group exhibiting a spectrum of morphologic findings. *Am J Clin Pathol*. 2011;135(3):398-403.
4. Spivak JL, Silver RT. The revised World Health Organization diagnostic criteria for polycythemia vera, essential thrombocytosis, and primary myelofibrosis: an alternative proposal. *Blood*. 2008;112(2):231-9.
5. Ćaman M, Vláďareanu AM, Onisai M. Refractory anemia with ring sideroblasts associated with marked thrombocytosis: case report and literature review. *Rom J Morphol Embryol*. 2012;53(3):645-50.
6. Schmitt-Graeff AH, Teo SS, Olschewski M, Schaub F, Haxelmans S, Kirm A, et al. JAK2V617F mutation status identifies subtypes of refractory anemia with ringed sideroblasts associated with marked thrombocytosis. *Haematologica*. 2008;93(1):34-40.

Fernando Barroso Duarte<sup>a</sup>, Francisco Dário Rocha Filho<sup>b</sup>,  
Romélia Pinheiro Gonçalves<sup>a</sup>

<sup>a</sup> Universidade Federal do Ceará (UFC), Fortaleza, CE, Brazil

<sup>b</sup> Laboratório Central de Análises Clínicas (CAC),  
Fortaleza, CE, Brazil

\*Corresponding author at: Hemocentro do Estado do Ceará,  
Hospital Universitário Walter Cantídio (HUWC),  
Rua Capitão Francisco Pedro, 1210 - Rodolfo Teófilo, 60430-  
370 Fortaleza, CE, Brazil.

E-mail address: romelia.pinheiro@pg.cnpq.br (R.P. Goncalves).

Received 8 February 2013

Accepted 16 October 2013

1516-8484/\$ - see front matter

© 2014 Associação Brasileira de Hematologia, Hemoterapia e  
Terapia Celular.

Published by Elsevier Editora Ltda. All rights reserved.

DOI: 10.5581/1516-8484.20140017