



Revista Brasileira de Hematologia e Hemoterapia Brazilian Journal of Hematology and Hemotherapy

www.rbhh.org



Case Report

Central retinal vein occlusion as first manifestation of relapse in acute lymphoblastic leukemia



Flávia Kessler Borges, Júlia Biegelmeyer, Samantha Thifani Alruz Barcelos*, Raquel Cristine Breunig

Universidade Federal de Ciências da Saúde de Porto Alegre (UFCSA), Porto Alegre, RS, Brazil

ARTICLE INFO

Article history:

Received 6 November 2014

Accepted 31 December 2014

Available online 14 April 2015

Introduction

Retinal vein occlusion is the second most common cause of visual loss due to retinal vascular disease after diabetic retinopathy.¹ Among the risk factors described, it is well known that the hypercoagulable state present in neoplasias can culminate in vein occlusion. It is described that any ocular structure may be involved in acute leukemia²; involvement of the choroid and retina is the most common. However, leukemic cells can infiltrate the conjunctiva and lacrimal glands, producing obvious masses. Karesh et al. published a two year prospective study of newly diagnosed adults with acute myeloid leukemia; 64% of patients had retinal or optic nerve abnormalities where hemorrhages and cotton wool spots (a consequence of nerve fiber ischemia) were the most frequent findings.³ The association between central retinal vein occlusion and acute lymphoblastic leukemia (ALL) relapse has rarely been described though.^{4–6} We hereby report

a case of central retinal vein occlusion as the presenting manifestation of relapse in ALL.

Case report

A 59-year-old female was diagnosed with ALL in November 2013. At that time, she had the following laboratory results: hemoglobin: 8.7 g/dL; red blood cells: $2.95 \times 10^9/\mu\text{L}$; MCV: 89 fL; total leukocytes: $18.66 \times 10^9/\text{L}$; lymphocytes: $5.374 \times 10^9/\text{L}$; segmented neutrophils: $2.930 \times 10^9/\text{L}$; blasts: 9143cells/ μL ; uric acid: 5.2 mg/dL; lactic dehydrogenase: 1672 U/L; creatinine: 3.1 mg/dL; and urea: 83 mg/dL. She received volemic resuscitation for tumor lysis syndrome. Subsequently, she developed pneumonia caused by *Cryptococcus neoformans* and herpes zoster skin lesions. Treatment was made with meropenem, amphotericin and acyclovir. In January 2014, after completing treatment for the infections, she was submitted to chemotherapy induction using the hyperCVAD

* Corresponding author at: Rua Sarmiento Leite, 245, Centro, 90050-170 Porto Alegre, RS, Brazil.

E-mail address: samanthatifani@gmail.com (S.T.A. Barcelos).

<http://dx.doi.org/10.1016/j.bjhh.2015.03.008>

1516-8484/© 2015 Associação Brasileira de Hematologia, Hemoterapia e Terapia Celular. Published by Elsevier Editora Ltda. All rights reserved.

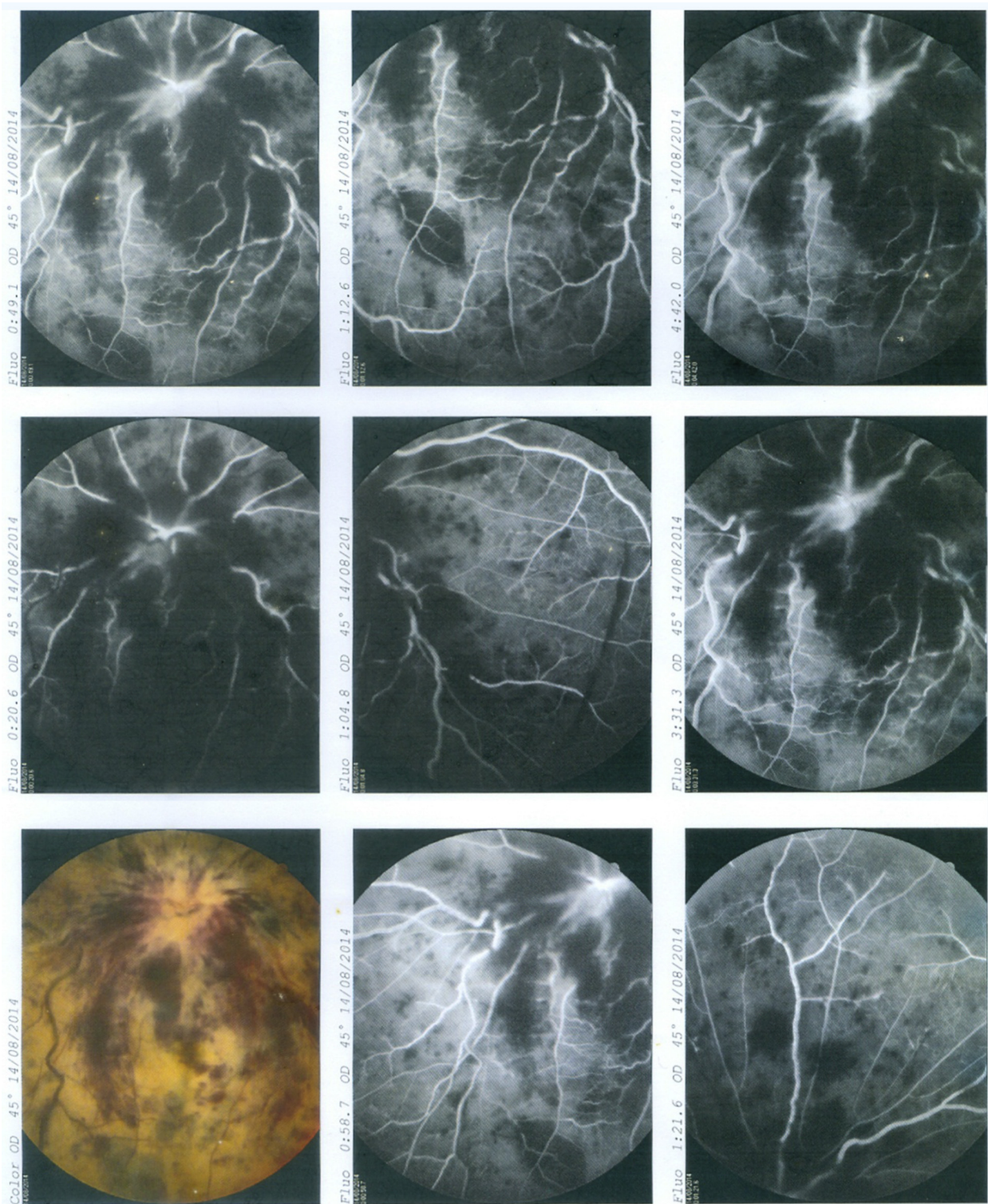


Figure 1 – Fluorescein angiography showing occlusion of central retinal vein.

regimen – course A (cyclophosphamide, vincristine, doxorubicin and dexamethasone). Immunophenotyping performed in February 2014 showed remission of the disease.

In March 2014 she presented febrile neutropenia and typhlitis. Empiric treatment with cefepime was started and the hyperCVAD regimen was interrupted. Blood cultures

identified *Escherichia coli* and *Klebsiella pneumoniae*. Treatment was completed on April 20th 2014.

After hospital discharge, she was submitted to outpatient re-induction therapy with the adapted Berlin-Frankfurt-Munster (BFM) protocol (dexamethasone, vincristine, doxorubicin and L-asparaginase) in June 2014. In July she was unable

to complete the fourth cycle of therapy due to hematological toxicity (hemoglobin: 9.0 g/dL; red blood cells: $2.71 \times 10^9/\mu\text{L}$; total leukocytes: $0.870 \times 10^9/\text{L}$; neutrophils: $0.628 \times 10^9/\text{L}$; and platelets: $13 \times 10^9/\text{L}$).

In August 2014 she came to our hospital emergency department complaining of a headache of the right side of her head, sensitivity to light, nausea, vomiting and visual loss in the right eye that had started four days previously. The neurological exam showed no abnormality, except for the eye fundus examination, which revealed papilledema, intraretinal peripapillary and inframacular hemorrhage in the right eye. The left eye presented a pre-retinal hemorrhage.

Laboratory exams did not reveal any abnormality. A coagulation panel showed platelets $154 \times 10^9/\text{L}$; prothrombin time activity: 100%; international normalization ratio (INR): 1.00; and activated partial thromboplastin time: 36.6 s.

A nuclear magnetic resonance image (MRI) was made, and the only abnormality was a hypointense lesion evidenced in the T2 sequence in the right temporal posterior region, which was probably a sequelae of a previous hemorrhagic infarct.

She was then submitted to a fluorescein angiography that revealed occlusion of the central retinal vein (Figure 1).

In order to exclude any infectious etiology, a lumbar puncture was made, with a normal opening pressure (150 cmH₂O). Cerebrospinal fluid analysis evidenced low glucose levels (28 mg/dL and 89 mg/dL in blood); high protein levels (89 mg/dL); cellularity 2520 cells/ μL ; 94% blasts; 5% monocytes; and red blood cells: 220 cells/ μL . Cultures for fungus, bacteria and cytomegalovirus antigenemia and herpes virus polymerase chain reaction (PCR) were all negative.

She was not taking any drug that would potentially be capable of inducing retinal vein occlusion.

In order to complete the evaluation of possible intracerebral vein thrombosis, the patient was submitted to a vascular MRI that revealed thickening of the right optic nerve and optic chiasm protuberance.

Immunophenotyping of the liquor had predominance of CD10, CD19, DC22, CD34, HLA DR cells, suggesting B lineage ALL. Lymphoblasts were identified in the cytopathological exam and bone marrow cytology confirmed medullar infiltration.

After confirming neurological relapse of ALL, intrathecal chemotherapy was given with dexamethasone, cytarabine and methotrexate. She had complete remission of headache, but had no improvement of her visual loss.

A magnetic resonance angiography of the central nervous system (CNS) was carried out to exclude other possible vascular thrombosis, but no alteration was found in the exam, except for infiltration of the right optic nerve.

She was discharged from hospital after two sessions of intrathecal chemotherapy, and continues outpatient treatment.

Discussion

There are few cases reported in the literature showing ocular nerve infiltration as an isolated manifestation of ALL relapse,

even though it is a consequence of CNS involvement with severe prognosis. In the case reported herein, the patient had a headache associated with visual loss, which strongly suggests CNS damage. Once her ophthalmologic exam showed only central retinal vein occlusion (CRVO), the clinical discussion focused on the etiology of the underlying process: whether it was a consequence of a hypercoagulable state or due to direct invasion of neoplastic cells since both conditions can culminate in CRVO.

In order to elucidate this question, a magnetic resonance angiography was performed to exclude other possible vein occlusions in the CNS, but the only finding was optic nerve infiltration, which had not been evident until this moment. It has already been described that MRI is useful in the early detection of ocular involvement.⁷

Even though CRVO is related with an hypercoagulable state, all the cases described in the literature that associate CRVO with ALL are secondary to an infiltration of leukemic cells.⁴⁻⁶ All cases show infiltration of the optic disk preceding vessel occlusion.

Treatment described in these cases consists in intrathecal chemotherapy and radiotherapy.^{8,9} There is no benefit in prescribing vascular endothelial growth factor (VEGF) inhibitors in these cases, as there is combined damage of the vein circulation and the optic nerve conduction; the latter can cause irreversible visual loss.¹⁰

Conclusion

CNS relapse can precede hematological signs and symptoms, and regular ophthalmologic exams should be instituted in patients with ALL. If ocular symptoms are present and the ophthalmologic exam is normal, a MRI should be considered. In cases of ALL and retinal vessel occlusion, always consider optic nerve infiltration and rapidly institute treatment with intrathecal chemotherapy and radiotherapy to avoid irreversible damage.

Conflicts of interest

The authors declare no conflicts of interest.

REFERENCES

1. Cugati S, Wang JJ, Rochtchina E, Mitchell P. Ten-year incidence of retinal vein occlusion in an older population: the Blue Mountains Eye Study. *Arch Ophthalmol.* 2006;124(5):726-32.
2. Rosenthal AR. Ocular manifestations of leukemia. A review. *Ophthalmology.* 1983;90(8):899.
3. Karesh JW, Goldman EJ, Reck K, Kelman SE, Lee EJ, Schiffer CA. A prospective ophthalmic evaluation of patients with acute myeloid leukemia: correlation of ocular and hematologic findings. *J Clin Oncol.* 1989;7(10):1528.
4. Salazar Mendez R, Fonolla Gil M. Unilateral optic disk edema with central retinal artery and vein occlusions as the presenting signs of relapse in acute lymphoblastic leukemia. *Arch Soc Esp Ophthalmol.* 2014;89(11):454-8.

5. Chan WM, Liu DT, Lam DS. Images in haematology. Combined central retinal artery and vein occlusions as the presenting signs of ocular relapse in acute lymphoblastic leukaemia. *Br J Haematol.* 2005;128(2):134.
6. Badelon I, Chaine G, Tolub O, Coscas G. Occlusion of the central vein and artery of the retina caused by infiltration of the optic nerve in lymphoblastic acute leukemia. *Bull Soc Ophtalmol Fr.* 1986;86(3):261-4.
7. De Fátima Soares M, Braga FT, da Rocha AJ, Lederman HM. Optic nerve infiltration by acute lymphoblastic leukaemia: MRI contribution. *Pediatr Radiol.* 2005;35(8):799-802.
8. Kaikov Y. Optic nerve head infiltration in acute leukemia in children: an indication for emergency optic nerve head radiation therapy. *Med Pediatr Oncol.* 1996;26(2):101-4.
9. Mayo GL, Carter JE, McKinnon SJ. Bilateral optic disk edema and blindness as initial presentation of acute lymphocytic leukemia. *Am J Ophthalmol.* 2002;134(1):141-2.
10. Braithwaite T, Nanji AA, Greenberg PB. Anti-vascular endothelial growth factor for macular edema secondary to central retinal vein occlusion. *Cochrane Database Syst Rev.* 2010;(10):CD007325.