



Revista Brasileira de Hematologia e Hemoterapia Brazilian Journal of Hematology and Hemotherapy

www.rbhh.org



Case report

Myelodysplastic syndrome with synchronous gastric cancer: when the symptoms suggest something else



Paula de Melo Campos^{a,*}, Fabiola Traina^{a,b}, Irene Lorand-Metze^a, Sara Teresinha Olalla Saad^a

^a Universidade Estadual de Campinas (UNICAMP), Campinas, SP, Brazil

^b Universidade de São Paulo (USP), Ribeirão Preto, SP, Brazil

ARTICLE INFO

Article history:

Received 17 December 2013

Accepted 4 June 2014

Available online 17 July 2014

Keywords:

Pancytopenia

Myelodysplastic syndromes

Hematologic neoplasms

Secondary neoplasms

Primary neoplasms

ABSTRACT

Although myelodysplastic syndromes have a clear definition in theory, the morphologic dysplasia associated with ineffective hematopoiesis may be subtle and difficult to recognize and can commonly be mimicked by systemic conditions, such as infections, autoimmune disorders, nutritional deficiencies, toxic factors and non-hematological malignancies. However, myelodysplastic syndromes may truly coexist with other systemic diseases, which can be masked when the patient's symptoms are attributed exclusively to myelodysplastic syndromes without further investigation. To better illustrate this, we herein describe two cases associated with synchronous gastric cancers.

© 2014 Associação Brasileira de Hematologia, Hemoterapia e Terapia Celular. Published by Elsevier Editora Ltda. All rights reserved.

Introduction

The myelodysplastic syndromes (MDS) are clonal hematopoietic stem cell disorders characterized by dysplasia of at least one of the myeloid cell lines, increased apoptosis and ineffective hematopoiesis. They comprise a heterogeneous group of diseases varying from indolent cases, characterized predominantly by cytopenias, to aggressive disease showing high blast counts and a significant propensity to evolve into acute

myeloid leukemia.¹ Thus, medical centers utilize the World Health Organization (WHO) 2008 criteria and the International Prognosis Scoring System (IPSS) to classify and predict prognosis in these patients.

Although MDS have a clear definition in theory, the morphologic dysplasia associated with ineffective hematopoiesis may be subtle and difficult to recognize,² and can commonly be mimicked by other systemic conditions, such as infections, autoimmune disorders, nutritional deficiencies, toxic factors and non-hematological malignancies.¹ However, MDS

* Corresponding author at: Hemocentro, Universidade Estadual de Campinas (UNICAMP), Rua Carlos Chagas, 480, 13083-878 Campinas, SP, Brazil.

E-mail address: pmcampos@gmail.com (P. de Melo Campos).

<http://dx.doi.org/10.1016/j.bjhh.2014.07.005>

1516-8484/© 2014 Associação Brasileira de Hematologia, Hemoterapia e Terapia Celular. Published by Elsevier Editora Ltda. All rights reserved.

may truly coexist with other systemic diseases, which can be masked if the patient's symptoms are attributed exclusively to MDS without further investigation. To better illustrate this, we report on two cases of MDS associated with synchronous gastric cancers. The first patient is a young lady who presented with moderate anemia and constitutional symptoms. The second case is a 67-year-old man with pancytopenia and fatigue.

Case 1

Our first patient, a 36-year-old woman with a previous history of diabetes mellitus and ischemic cardiomyopathy had complaints of persistent anemia, fatigue and weight loss (17 pounds in six months). She was 19 weeks pregnant and had no other significant past medical, family or exposure history. The results of her physical examination were unremarkable. She had never required red blood cell transfusions. Her complete blood counts showed the following: hemoglobin = 6.0 mg/dL, mean corpuscular volume (MCV) = 96.3 fL, platelet count = $158 \times 10^9/L$, and absolute neutrophil count = $2.9 \times 10^9/L$. Iron studies were normal and nutritional deficiencies were ruled out. She had no signs of infectious diseases and serology for hepatitis B and C, human immunodeficiency virus (HIV) and cytomegalovirus (CMV) were negative. A bone marrow (BM) biopsy was performed which showed hypercellularity (95–100%) with no atypias or reticulin fibrosis. BM cytology showed 4.4% of blasts with no significant dysplastic changes in any hematopoietic lineages, normal iron stores and no ring sideroblasts. Cytogenetic analysis was normal (46,XX). Flow cytometry detected three immunophenotypic abnormalities. At that time, the criteria was not yet sufficient to establish a definitive hematologic diagnosis. The patient received two units of packed red cells and her blood counts remained stable during the rest of the pregnancy.

After delivery, the patient evolved with a deterioration of blood counts (hemoglobin = 6.1 mg/dL, platelet count = $78 \times 10^9/L$, and absolute neutrophil count = $3.3 \times 10^9/L$) and began to require frequent red blood cell transfusions. Bone marrow cytology was again performed and showed 11% of blasts, with no significant dysplasia and a normal karyotype. A BM biopsy revealed hypolobulated megakaryocytes (Figure 1). The diagnosis of MDS (WHO 2008 refractory anemia with excess blasts-2 [RAEB-2] and IPSS Intermediate-2) was reached.

Subsequently, as the patient complained of further significant weight loss and constitutional symptoms, a screening for malignancies was performed: a chest X-ray was normal, but an abdominal computed tomography scan showed a homogeneous enlargement of the spleen (30 cm), and an upper gastrointestinal endoscopy showed an advanced elevated lesion in the stomach with a biopsy confirming a gastric tubular adenocarcinoma with areas showing a diffuse pattern of signet-ring cell carcinoma. She was submitted to total gastrectomy with lymphadenectomy and splenectomy. The stomach biopsy confirmed a diffuse signet-ring cell carcinoma with involved margins and signs of lymphatic and perineural invasion, whereas the spleen biopsy showed only hyperplasia.

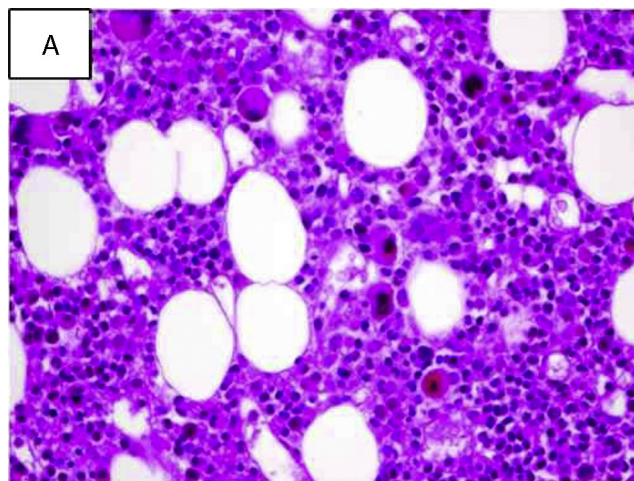


Figure 1 – Bone marrow histology. Moderate hypercellularity and mild maturation arrest of the granulocytic compartment, predominating in the erythroblast compartment. Megakaryocytes are increased in number and are hypolobulated (hematoxylin and eosin: 400×).

The patient started chemotherapy with the etoposide, l-leucovorin and fluorouracil (ELF) regimen for advanced gastric cancer, but died four months later due to a massive pulmonary thromboembolism.

Case 2

The second case is a 67-year-old gentleman who complained of weakness, fatigue and weight loss (31 pounds in four months). He had been diagnosed with systemic hypertension, diabetes mellitus and congestive heart failure, but no other significant past medical, family or exposure history. His physical examination was unremarkable. His complete blood count revealed: hemoglobin = 6.4 mg/dL, MCV = 112.0 fL, platelet count = $28 \times 10^9/L$, and absolute neutrophil count = $0.7 \times 10^9/L$. Screening for nutritional deficiencies showed a vitamin B12 level of 190 pg/mL (below reference range). A BM biopsy showed moderate hypercellularity with atypical megakaryocytes (Figure 2), no significant dysplastic changes and moderate diffuse reticulin fibrosis. A BM aspiration revealed dyserythropoiesis, cytoplasmic hypogranularity, no megaloblastic changes, no ring sideroblasts and 9% of blasts, with normal cytogenetics (46,XY). Flow cytometry detected five immunophenotypic abnormalities. Vitamin B12 was supplemented, but there was no increase in blood counts. Infectious diseases were ruled out. The diagnosis of MDS (WHO 2008 RAEB-1 and IPSS Intermediate-1) was reached and the patient was included in the regular transfusion program.

An abdominal and chest computed tomography scan was performed to investigate the constitutional symptoms of the patient and his significant weight loss, but no significant abnormalities were observed. An upper gastrointestinal endoscopy showed diffuse atrophic gastritis and a depressed gastric lesion, with a biopsy showing a gastric

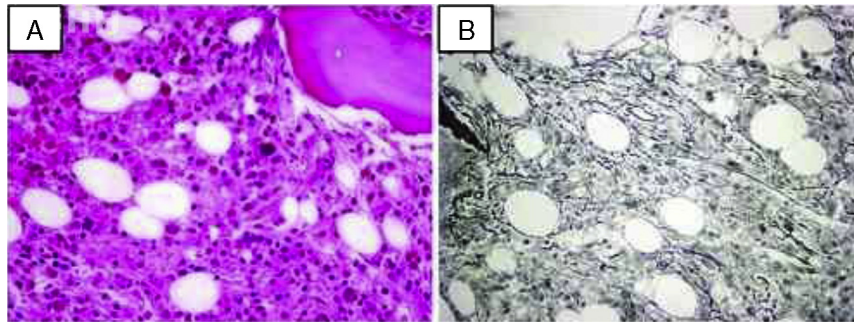


Figure 2 – Bone marrow histology. (A) Intense hypercellularity and maturation arrest of hematopoietic components. Megakaryocytes are atypical: dwarf and hypolobulated (hematoxylin and eosin: 400×). (B) Silver impregnation shows moderate increase in reticulin fibers (400×).

adenocarcinoma *in situ*. A therapeutic upper gastrointestinal endoscopy was subsequently carried out, but endoscopic resection of the lesion was not possible, since the gastric mucosa was friable and hemorrhagic. At that time, blood counts continued to drop (hemoglobin=transfusion dependent, platelet count= $6 \times 10^9/L$, absolute neutrophil count= $0.3 \times 10^9/L$). The patient was subsequently submitted to a partial laparoscopic gastric resection, but died eleven days later due to postoperative fever and severe sepsis.

Discussion and conclusions

As the diagnosis of MDS is based mainly on an assessment of the morphology, the diagnosis can be subjective, particularly in patients with early low risk disease presenting a normal karyotype. In general, diagnosis is easier in patients with excess blasts. Since there are many conditions that can mimic MDS, a clinical assessment with the exclusion of additional systemic conditions, such as nutritional deficiencies, autoimmune disorders and non-hematological malignancies is needed.³ There are no studies describing the incidence of synchronous non-hematological neoplasms occurring concurrently with MDS, and so this seems to be relatively uncommon. However, the presence of symptoms which are not frequently associated with MDS, such as significant constitutional symptoms, excessive weight loss and localized pain should raise clinical suspicion of associated malignancies, leading to an extensive investigation.

Herein we described two cases of synchronous gastric cancer and myelodysplasia in a young and an elderly patient. This is a rare condition, and there are very few reports describing this association.^{4,5} Similarly, in the clinical practice, drops in blood counts of patients with non-hematological malignancies are very frequently attributed to ‘secondary’ conditions, such as, for example, chronic disease anemia and immune thrombocytopenias. It is important to point out the possibility of coexistence of MDS with other neoplasms and so bone marrow studies should always be considered.

Regarding the simultaneous occurrence of MDS and non-hematological neoplasms, we hypothesize that an initial event selecting a stem cell clone, together with abnormalities in immunosurveillance, may manifest with a higher propensity to cancer. Alternatively, an increased chromosomal instability which seems to be associated with immunodeficiencies might be responsible for the development of cancer.⁵ Finally, a decreased function of tumor suppression genes could be an important final factor that would allow malignant cells to proliferate.

Conflicts of interest

The authors declare no conflicts of interest.

Acknowledgments

The authors would like to thank Raquel S. Foglio for reviewing the English, and Prof. Dr. José Vassalo for providing the figures.

REFERENCES

1. Brunnin RD, Orazi A, Germing U, Le Beau MM, Porwit A, Baumann I, et al. Myelodysplastic syndromes/neoplasms, overview. WHO classification of tumors of haematopoietic and lymphoid tissues; 2008. p. 88–93.
2. Odenike O, Anastasi J, Le Beau MM. Myelodysplastic syndromes. Clin Lab Med. 2011;31(4):763–84.
3. Garcia-Manero G. Myelodysplastic syndromes: 2011 update on diagnosis, risk-stratification, and management. Am J Hematol. 2011;86(6):490–8.
4. Takahashi T, Kazama Y, Shimizu H, Yoshimoto M, Tsujisaki M, Aoki S, et al. Myelodysplastic syndrome progresses rapidly into erythroleukemia associated with synchronous double cancers of the stomach and the papilla of Vater. Int J Hematol. 2001;74(1):64–9.
5. Kondo H, Shinbo I. Myelodysplastic syndrome associated with gastric cancer and colon polyp. Rinsho Ketsueki. 1997;38(11):1234–7.