



Images in Clinical Hematology

Mycobacterium leprae in bone marrow



Leonardo Rodrigues de Oliveira*, André Luiz Maltos

Universidade Federal do Triângulo Mineiro (UFTM), Uberaba, MG, Brazil

ARTICLE INFO

Article history:

Received 4 March 2014

Accepted 17 March 2014

Available online 29 May 2014

The case of a 54-year-old man, who was referred to evaluate a consumptive syndrome with anemia and fever of unknown origin, is reported. A physical examination revealed madarosis, nodular lesions on the ears, nasal soft tissue collapse, subcutaneous nodules on arms and generalized lymphadenopathy. Laboratory tests showed anemia (Hb 8.8 g/dL, mean corpuscular volume 82.4 fL, mean corpuscular hemoglobin 24.5 pg), normal reticulocyte count (0.5%), thrombocytosis ($482 \times 10^9/L$), normal serum ferritin (268 ng/mL) and elevated C-reactive protein (124 mg/L). Serologies (viral hepatitis and human immunodeficiency virus) were non-reagent. Lepromatous leprosy was confirmed by staining for acid-fast bacilli using samples from the ear and subcutaneous nodules and bone marrow smears. Bone marrow was hypercellular with myeloid hyperplasia (myeloid-erythroid ratio 7:1) but without dysplasia. *Mycobacterium leprae* was detected lying free and in foamy histiocytes named Virchow cells (Figures 1 and 2).^{1,2} A multidrug therapeutic regimen (clofazimine, dapsone, rifampicin) was established with progressive improvement.

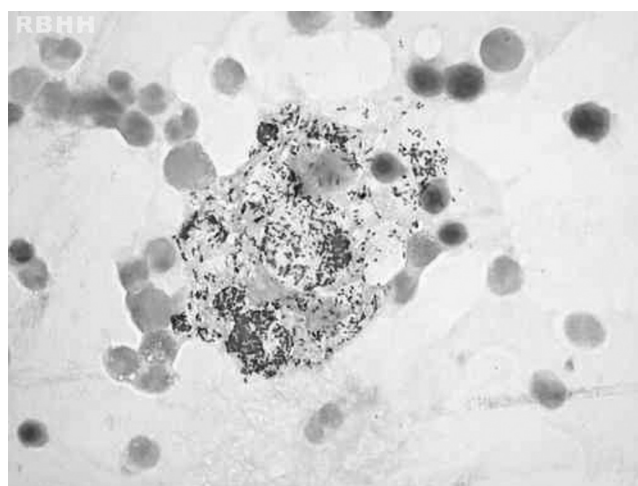


Figure 1 – Large cells (histiocytes) with their abundant cytoplasm filled with acid-fast bacilli (*Mycobacterium leprae*) in bone marrow (Ziehl-Neelsen stain) magnification 1000x.

* Corresponding author at: Universidade Federal do Triângulo Mineiro – UFTM, Central de Quimioterapia, Rua Getúlio Guarita, s/n, 38080-125 Uberaba, MG, Brazil.

E-mail address: leonardorodoli@hotmail.com (L.R. de Oliveira).

<http://dx.doi.org/10.1016/j.bjhh.2014.05.010>

1516-8484/© 2014 Associação Brasileira de Hematologia, Hemoterapia e Terapia Celular. Published by Elsevier Editora Ltda. All rights reserved.

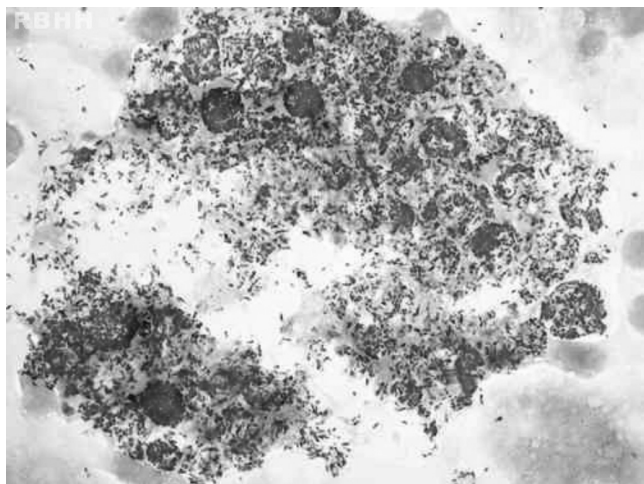


Figure 2 – Large cells (histiocytes) with their abundant cytoplasm filled with acid-fast bacilli (*Mycobacterium leprae*) in bone marrow (Fite-Faraco stain) magnification 1000x.

Conflicts of interest

The authors declare no conflicts of interest.

REFERENCES

1. Singh N, Bhatia A, Lakra A, Arora VK, Bhattacharya SN. Comparative cytomorphology of skin, lymph node, liver and bone marrow in patients with lepromatous leprosy. *Cytopathology*. 2006;17:257–61.
2. Suster S, Cabello-Inchausti B, Robinson MJ. Non-granulomatous involvement of the bone marrow in lepromatous leprosy. *Am J Clin Pathol*. 1989;92:797–801.