

# Efficacy of monocanalicular versus bicanalicular intubation in the treatment of congenital nasolacrimal duct obstruction

## *Comparação de eficácia entre as sondas monocanalicular e bicanalicular no tratamento da obstrução congênita das vias lacrimais*

Bruno Hirt<sup>1\*</sup> <https://orcid.org/0000-0002-1189-9782>  
Eduardo Euzieres Granzotto<sup>1</sup> <https://orcid.org/0000-0002-3921-0086>  
Filipe Lennert Silva<sup>1</sup> <https://orcid.org/0000-0002-2954-8825>  
Marcos Bortoluzzi Worma<sup>1</sup> <https://orcid.org/0000-0002-1722-6466>  
Nayra Funato Menezes<sup>2</sup> <https://orcid.org/0000-0002-1173-2915>  
Natasha Danilow Fachin<sup>2</sup> <https://orcid.org/0000-0002-0625-1842>  
Renato Mitsunori Nisihara<sup>3</sup> <http://orcid.org/0000-0002-1234-8093>  
Rodrigo Beraldi Kormann<sup>2</sup> <https://orcid.org/0000-0002-0838-4331>  
Luciane Bugmann Moreira<sup>2</sup> <https://orcid.org/0000-0002-9413-6851>

### ABSTRACT

**Objective:** to evaluate and to compare the success rate of monocanalicular or bicanalicular intubation in congenital nasolacrimal duct obstruction (CNDO) carriers in terms of success rate, difficulty of the procedure, and cost of the tubes. **Methods:** fifty-four CNDO carriers with 58 obstructed lacrimal vies (LV) who were submitted to lacrimal system intubation using mono or bicanalicular stent had their medical records analyzed. A clinical history, a general ophthalmologic examination, specific tests such as the fluorescein dye disappearance test (FDDT) and observation test of fluorescein in the oropharynx (OTFO) were used for diagnosis and inclusion in the study. Patients who continued exhibiting discharge and continuous epiphora after previous treatment, Crigler massage and probing, were treated surgically with intubation. **Results:** Monocanalicular intubation was performed on 27 LV and bicanalicular intubation was performed on 31 LV. High success rates were observed, with improvement in 26 (96.3%) with monocanalicular intubation and in 30 LV (96.8%) with bicanalicular intubation ( $p=0.718$ ). Furthermore, both techniques were 100% successful in patients up to 2 and over 4 years of age ( $p=1$ ). The success rates between 2-4 years of age were 91.6% in monocanalicular intubation and 87.5% in bicanalicular intubation ( $p=0.652$ ). **Conclusion:** The success rate using monocanalicular or bicanalicular intubation to treat CNDO had no significant difference in the studied children. Furthermore, the monocanalicular tube was easier to use, while the bicanalicular tube had a lower cost.

**Keywords:** Nasolacrimal duct obstruction/surgery; Nasolacrimal duct obstruction/ congenital; Congenital abnormalities; Diseases of the lacrimal drainage system; Nasolacrimal duct

<sup>1</sup> Medicine Course, Universidade Positivo – Curitiba (PR), Brazil

<sup>2</sup> Department of Ophthalmology, Hospital de Olhos do Paraná – Curitiba (PR), Brazil

<sup>3</sup> Department of Medicine, Universidade Positivo – Curitiba (PR), Brazil

Institution: Hospital de Olhos do Paraná, São Paulo, SP, Brazil.

The authors declare no conflicts of interests.

Received for publication 14/01/2019 - Accepted for publication 17/10/2019.

## RESUMO

**Objetivo:** Avaliar e comparar a taxa de sucesso da intubação monocanalicular ou bicanalicular em pacientes com obstrução congênita do ducto lacrimonasal (OCDLN), levando-se em consideração a taxa de sucesso, a dificuldade do procedimento e o custo dos tubos. **Métodos:** Foram analisados retrospectivamente 54 prontuários, totalizando 58 vias lacrimais com diagnóstico de OCDLN, que realizaram intubação das vias lacrimais monocanalicular ou bicanalicular com tubos de silicone. Anamnese, exame oftalmológico geral, testes específicos, como o Teste do Desaparecimento do Corante (TDC) e Teste de Observação de Fluoresceína na Orofaringe (TOFO), e, caso necessário, exames complementares como a dacriocistografia, foram utilizados para diagnóstico e inclusão na pesquisa. Foram tratados com intubação os pacientes sem resposta adequada ao tratamento prévio, ou seja, que permaneceram com sintomas de secreção e epífora contínua após a realização de massagem de Crigler e sondagem. **Resultados:** A intubação monocanalicular foi realizada em 27 vias lacrimais e a intubação bicanalicular, em 31 vias lacrimais. A taxa de sucesso foi alta em ambos os métodos, com melhora em 26 (96,3%) vias lacrimais com sonda monocanalicular e em 30 (96,8%), com sonda bicanalicular ( $p=0,718$ ). As duas técnicas apresentaram 100% de sucesso nos pacientes com até 2 anos e acima de 4 anos de idade ( $p=1$ ). A taxa de sucesso entre os 2 e 4 anos de idade foi de 91,5% para as monocanaliculares e 87,5% para as bicanaliculares, ( $p=0,652$ ). **Conclusão:** o presente estudo não mostrou diferença significativa no sucesso da intubação quando utilizando sondas mono ou bicanaliculares. A intubação monocanalicular mostrou-se de mais fácil execução, ao passo que o tubo bicanalicular possui menor custo.

**Descritores:** Obstrução dos Ductos Lacrimais/cirurgia; Obstrução dos Ductos Lacrimais/congênito; Anormalidades Congênicas; Doenças do Aparelho Lacrimal; Ducto Nasolacrimal

## INTRODUCTION

Congenital nasolacrimal duct obstruction (CNLDO) is a common condition in ophthalmology clinics and accounts for about 5% of appointments.<sup>(1)</sup> It affects 5 to 20% of newborns,<sup>(2,3)</sup> and about 90% of CNLDO occur by imperforating the Hasner valve. Continuous epiphora in one or both eyes associated with mild to intense mucoid secretion is the most common complaints.<sup>(4)</sup>

CNLDO is diagnosed by anamnesis and ophthalmic examination. The main tests used are the dye disappearance test (DDT) and the observation test of fluorescein in the oropharynx (OTFO). Complementary tests such as dacryocystography should be used in singular cases.<sup>(5-10)</sup>

Once diagnosed, the management of patients with CNLDO is usually conservative clinical treatment with hygiene of the eye affected with filtered water or 0.9% saline and Crigler massages<sup>(8)</sup> or deflator. About 90% of these children will have spontaneous resolution by the first year of life without the need for a surgical procedure.<sup>(10,11)</sup>

However, for those who do not show improvement until 12 months of age, nasolacrimal duct probing is indicated.<sup>(6,8)</sup> In case of probing failure, nasolacrimal duct intubation is indicated.

This sequence in treatment depends on factors such as the onset of signs, amount of secretion from the lacrimal sac, age of the child, and history of previous surgery or not.<sup>(2-4)</sup>

Various types of tubes can be used for intubation, with the biconalicular silicone tube (Crawford®- FCI, Paris, France) being the most widely used.<sup>(12)</sup> The monocanalicular silicone tube (Monoka®- FCI, Paris, France) is also employed for the treatment of CNLDO.<sup>(11,12)</sup> The technique consists of probing the tear pathway with the introduction of a silicone tube into the tear pathway.<sup>(13)</sup> The choice of tube depends on the routine of the service, the physician's experience and the cost of each tube.<sup>(4,12)</sup>

To date, there is no consensus as to which method of intubation - bicanalicular or monocanalicular - has the best results for the treatment of CNLDO. Thus, the present study aims to contribute to existing studies and improve the management of CNLDO.

The objective of the present study is to comparatively evaluate the monocanalicular and bicanalicular intubation for the treatment of CNLDO, considering the success rate, the difficulty of the procedure, and the cost of the tubes.

## METHODS

This is a retrospective study approved by the Research Ethics Committee of Centro de Estudos Superiores Positivo Ltda under No. CAAE 88080318.7.0000.0093 and Sociedade Evangélica Beneficente de Curitiba with CAAE No. 88080318.7.3001.0103.

We reviewed the medical records of patients diagnosed with CNLDO seen at the Oculoplastic Department of Hospital de Olhos do Paraná (HOP) from January 2013 to April 2018. The following data were collected: age, gender, onset of symptoms, presence of epiphora and/or secretion, affected eye, date and age at the beginning of treatment, type of tube used for intubation of the nasolacrimal duct, improvement or not of postoperative symptoms, need for new surgery, and comorbidities.

Patients with CNLDO who did not improve with conservative clinical treatment based on massages and with probing of the nasolacrimal duct were included, and after that underwent single or bi-canalicular intubation of the nasolacrimal duct, whose clinical follow-up and tube removal were performed in the same service. Patients who did not return for tube removal and those with incomplete data were excluded from the study.

Two intubation methods were used: the bicanalicular using the Crawford® probe (FCI, Paris, France), and the monocanalicular using the Monoka® tube (FCI, Paris, France), depending on the team protocol and service routine so one team received training for monocanalicular intubation with lacrimal tract permanence tube and post-withdrawal follow-up close to 90 days, and the other received training for bicanalicular intubation with lacrimal tract permanence and post-withdrawal follow-up close to 30 days. Both procedures were performed under general anesthesia.

For the diagnosis, data on the anamnesis, the general and the specific ophthalmological exam (DDT and OTFO) were recorded. DDT was performed by instilling a drop of fluorescein eye drops into the affected eye, and after a period of 3-5 minutes tests were accepted as obstruction in which the lacrimal meniscus exceeded 1-2 mm in thickness under cobalt light, meaning probable obstruction of the nasolacrimal duct. OTFO was performed by researching 1% sodium fluorescein eye drops (Ophthalmos, São Paulo, Brazil) instilled to the affected eye in the oropharynx using a cobalt light and a tongue depressor 30 minutes after eye drop

instillation, being considered the result of pervious nasolacrimal duct when fluorescein was visible in the oropharynx. In case of inconclusive results, dacryocystography was chosen as a diagnostic method. However, its use was not necessary in the patients studied.

Regarding the fixation of the tubes, the monocanalicular probe is in the nasal cavity without the need for suturing or other method of fixation, since the probe has a plug that fits in the lacrimal punctum preventing its progression. On the other hand, the bicanalicular probe is attached to the nasal cavity by knotting both ends of the probe and fixing it to the internal region of the nasal columella.

After intubation, the results were evaluated as to the improvement or not of the symptoms based on the data from the specific tests mentioned above evaluating the functionality of the nasolacrimal duct. The treatment was considered effective when there was persistent improvement of signs and symptoms in the follow-up appointments, with negative DDT (normal lacrimal meniscus) and positive OTFO (presence of fluorescein in the oropharynx with cobalt light).

Postoperative returns were every 7 days for the first two weeks, and then the term was extended according to each specific case.

The choice of the moment to remove the nasolacrimal tract for both teams in this study was based on clinical improvement of the signs and symptoms of CNLDO coupled with specific tests (DDT and OTFO) favorable to case resolution. In cases of doubt about the improvement with intubation, it was decided to postpone the removal of the tube, maintaining regular monitoring. After removal of the tube, patients were followed at the service according to the protocol of each team for regular reevaluations of permeability of the nasolacrimal duct.

Success rates were analyzed according to the type of intubation used, considering two categories: success or failure of intubation. Success was also assessed according to age, considering three groups: nasolacrimal duct intubation up to 24 months (Group 1), from 24 months to 48 months of age (Group 2), and finally intubation performed with patients older than 48 months (Group 3).

Data obtained was statistically analyzed using the Chi-square test with Yates correction, Fisher's exact test, t-test for independent samples. A significance level of 5% was adopted. Data was analyzed using the computer program BioEstat v.5.3.0. (Belem, Brazil).

## RESULTS

Of the medical records analyzed, 23 (42.6%) patients were female and 31 (57.4%) male ( $p = 0.116$ ). Monocanalicular intubation was performed in patients with a median age of 33 months (IIQ 15 - 45 months), with minimum and maximum ages of 4 months and 110 months, respectively. In bicanalicular intubation, patients with a median age of 25 months (IIQ 13 - 59 months) were observed, with minimum and maximum ages of 4 months and 133 months, respectively ( $p = 0.864$ ). Regarding nasolacrimal ducts, 34 (58.6%) patients presented symptoms on the left, and 24 (41.4%) on the right ( $p = 0.79$ ) (Table 1).

Overall, of the 58 nasolacrimal ducts analyzed, 56 (96.5%) showed improvement of symptoms after intubation, and two nasolacrimal ducts (3.5%) had no improvement ( $p = 0.718$ ). Regarding the length of stay of intubation, the time of monocanalicular intubation had a median of 90 days (IQR 80 - 123 days), and bicanalicular intubation had a median of 30

**Table 1**  
Clinical characteristics of the patients

	Monocanalicular Group	Bicanalicular Group	p-Value
Nº. of patients	25	29	0.781§
Nº. of nasolacrimal ducts	27	31	
<b>Gender (%)</b>			0.116§
Male	11 (44)	20 (68.9)	
Female	14 (56)	9 (31.1)	
<b>Side operated(%)</b>			0.79†
Right	12 (44.5)	12 (54.5)	
Left	15 (55.5)	19 (45.5)	
Median Age (in months)	33(IQR 15-45)	25(IQR 13-59)	0.432*

Age values are presented as median: interquartile range (IQR).

§Chi square with Yates correction; †Fisher's exact; \*Independent T test

days (IQR 30 - 46 days). Regarding the follow-up time after tube removal, the follow-up of monocanalicular intubation had a median of 90 days (IQR 57 - 158 days), and bicanalicular intubation had a median of 30 days (IQR 30 - 60 days) (Table 2).

In Group 1, 22 nasolacrimal ducts (9 with monocanalicular and 13 with bicanalicular) were observed with 100% improvement ( $p = 1$ ). In group 2, 20 nasolacrimal ducts (12 with monocanalicular and 8 with bicanalicular) were observed with 2 (10%) nasolacrimal ducts without improvement ( $p = 0.652$ ), being 1 of these with monocanalicular and 1 with bicanalicular. In group 3, 16 nasolacrimal ducts (6 with monocanalicular and 10 with bicanalicular) were observed with 100% improvement ( $p = 1$ ) - (Figure 1).

**Table 2**  
Postoperative improvement rate in both patient groups

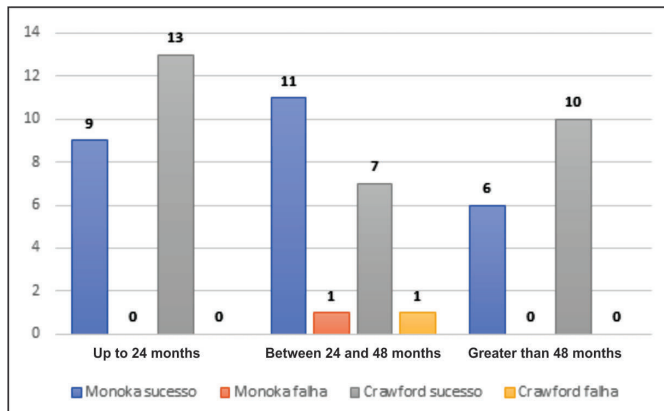
	Monocanalicular (27)	Bicanalicular (31)	p-Value
<b>Outcome</b>			0.718†
Improvement	26 (96.3%)	30 (96.8%)	
No improvement	1 (3.7%)	1 (3.2%)	
<b>Length of Stay</b>			
Median (days)	90 (IIQ 80-123)	30 (IIQ 30-46)	< 0.001*
<b>Follow up Time</b>			
Median (days)	90 (IIQ 57-158)	30 (IIQ 30-60)	0.03*

Values shown as number (%).

Length of stay and follow-up shown in median days: interquartile range (IQR).

†Fisher's Exact Test, \*Independent T-Test

In the present study, there were no perioperative complications. However, in the postoperative period, two cases of tube extrusion were observed: one bicanalicular tube 30 days after placement, and one monocanalicular tube 23 days later. In addition, five cases of lacrimal punctum stenosis were observed (three in patients in the bicanalicular group and two in the monocanalicular group). The failure occurred in the bicanalicular group whose patient had superior canaliculus stenosis was corrected with a monocanalicular tube. No cases of canaliculus rupture were observed as a result of the tubes.



P values calculated with Fisher's exact test.

**Figure 1:** Intubation success and failure by age group.

## DISCUSSION

O presente trabalho demonstrou que a intubação mono ou bicanalicular apresentaram 100% de sucesso no grupo até os 2 anos e no acima dos 4 anos de idade, sendo maiores que os divulgados pela literatura, que encontraram 86,1% de sucesso até 2 anos,<sup>(14)</sup> 91,3% até 2 anos e 79,6% acima de 4 anos,<sup>(11)</sup> e 81,8% até 2 anos e 81,2% acima dos 4 anos.<sup>(15)</sup> Entre os 2 e 4 anos de idade as taxas de sucesso corroboraram com a literatura, que encontraram 95,4% de sucesso entre 2 e 3 anos,<sup>(14)</sup> 85,5% entre 2 e 4 anos<sup>(11)</sup> e 92,3% entre 2 e 4 anos.<sup>(16)</sup> Neste trabalho, não se pode demonstrar a correlação entre a idade e o resultado do tratamento, como já observado em outro estudo brasileiro.<sup>(13)</sup>

Não houve diferença significativa em relação ao predomínio de gênero, concordando com estudos prévios, que encontraram 52,1% de pacientes femininos e 47,9% masculinos,<sup>(14)</sup> 42,4% femininos e 57,6% masculinos,<sup>(3)</sup> e 55,6% femininos e 44,4% masculinos.<sup>(11)</sup>

Em relação a facilidade do procedimento, a sonda monocanalicular é de mais fácil colocação pois, dentro da cavidade nasal, seu fio forma um enovelado que é de mais fácil visibilização e recuperação, não necessitando de sutura e facilitando sua retirada pelo médico. Por outro lado, a sonda bicanalicular apresenta ponteiros metálicas, em cada extremidade do fio de silicone, que devem ser capturadas e conectadas usando um gancho específico para essa técnica. O uso do endoscópio pode facilitar o procedimento. Sobre o conforto, a sonda monocanalicular é mais cômoda para o paciente, pois passa apenas por um canal lacrimal ficando livre dentro da cavidade nasal, não necessitando de nós ou sutura para ser fixada, como a bicanalicular.<sup>(2,16)</sup>

Observou-se 12% de complicações pós-operatórias (8,6% de estenose de ponto lacrimal e 3,4% de extrusão acidental da sonda) e nenhuma per-operatória em pacientes submetidos a intubação, corroborando com os achados de 25% de extrusão acidental da sonda,<sup>(16)</sup> 5% de estenose de ponto lacrimal<sup>(16)</sup> e 20% de sangramento de ponto lacrimal associado a estenose.<sup>(7)</sup>

No presente estudo, um grupo de médicos oftalmologistas realizou os procedimentos com a sonda monocanalicular enquanto outro grupo realizou os procedimentos com a sonda bicanalicular seguindo os mesmos métodos diagnósticos, contudo, utilizando protocolos próprios para a escolha do momento de retirada dos tubos. Porém, houve diferença estatística significativa entre os

tempos de permanência das intubações monocanaliculares em relação às bicanaliculares ( $p < 0,001$ ) e no tempo de seguimento pós-retirada dos tubos monocanaliculares e bicanaliculares das vias lacrimais dos pacientes ( $p = 0,03$ ).

No que tange a diferença de tempo de permanência dos tubos, ambas as equipes seguiram protocolos próprios sobre a permanência dos tubos na via lacrimal, visando a melhora clínica dos sinais e sintomas e dos testes específicos para então realizar a retirada dos tubos.

É importante comentar sobre o custo dos tubos para o paciente, sendo o tubo monocanalicular, em média, 1,6 vezes mais caro que o tubo bicanalicular, segundo dados informados pela FCI em setembro de 2019, não sendo levado em consideração custos hospitalares ou demais despesas. Ademais, no Brasil, o tubo bicanalicular tem seu valor coberto pelos planos de saúde e Sistema Único de Saúde (SUS), ao passo que o tubo monocanalicular não. Assim, é possível que o tubo monocanalicular tenha maior custo final quando se considera mais deslocamentos, assim como para os serviços de assistência, visto que houve maior número de consultas para os pacientes que tiveram o uso deste tubo.

Existem algumas limitações no presente estudo. Primeiramente relacionada com o desenho retrospectivo do estudo, com coleta de dados baseada na análise de prontuários, o fato de serem cirurgias diferentes para cada técnica e pela diferença observada entre os tempos de permanência e seguimento dos dois métodos de intubação. Contudo, nossos resultados basearam-se em uma amostra com grupos homogêneos e de tamanho razoável para o tema, obtendo-se assim dados mais fidedignos.

## CONCLUSION

Observou-se que a chance de sucesso no tratamento da OCVL com intubação da via lacrimal foi estatisticamente igual com a técnica monocanalicular ou bicanalicular.

Ambos métodos se mostraram seguros e sem graves complicações. A intubação bicanalicular é mais barata, porém, a monocanalicular oferece maior facilidade para a introdução e remoção do tubo, assim como maior conforto ao paciente.

## REFERENCES

- Lunardelli P, Aoki L, Jervasio AC, Zagui RM, Matayoshi S. Implante de ducto nasolacrimal de poliuretano: relato de caso. *Arq Bras Oftalmol.* 2008;71(1):110-4.
- Eustis HS, Nguyen AH. The Treatment of Congenital Nasolacrimal Duct Obstruction in Children: A Retrospective Review. *J Pediatr Ophthalmol Strabismus.* 2018;55(1):65-7.
- Eshraghi B, Jamshidian-Tehrani M, Mirmohammadsadeghi A. Comparison of the success rate between monocanalicular and bicanalicular intubations in incomplete complex congenital nasolacrimal duct obstruction. *Orbit.* 2017;36(4):215-7.
- Lin AE, Chang YC, Lin MY, Tam KW, Shen YD. Comparison of treatment for congenital nasolacrimal duct obstruction: a systematic review and meta-analysis. *Can J Ophthalmol.* 2016;51(1):34-40.
- MacEwen CJ, Young JD, Barras CW, Ram B, White PS. Value of nasal endoscopy and probing in the diagnosis and management of children with congenital epiphora. *Br J Ophthalmol.* 2001;85(3):314-8.
- Carvalho RM, Seronni LB, Avila M. Dilatação por cateter-balão (dacrioplastia) para tratamento das obstruções congênitas do ducto lacrimonasal. *Arq Bras Oftalmol.* 2009 Sep;72(5):669-72.
- Young JD, MacEwen CJ. Managing congenital lacrimal obstruction in general practice. *BMJ.* 1997;315(7103):293-6.



8. Schellini SA. Obstrução nasolacrimal congênita - diagnóstico e tratamento. *Rev Bras Oftalmol.* 2005;64(2):128–32.
9. Lorena SH, Silva JA. Estudo retrospectivo da obstrução congênita do ducto lácrimonasal. *Rev Bras Oftalmol.* 2011;70(2):104–8.
10. Dantas RR. Lacrimal drainage system obstruction. *Semin Ophthalmol.* 2010;25(3):98–103.
11. Lee H, Ahn J, Lee JM, Park M, Baek S. Clinical effectiveness of monocanalicular and bicanalicular silicone intubation for congenital nasolacrimal duct obstruction. *J Craniofac Surg.* 2012;23(4):1010–4.
12. Cervenka S, Matoušek P, Komínek P. [Comparing of Treatment Results of Monocanalicular and Bicanalicular Intubation in Inborn Lacrimal Duct Obstruction]. *Cesk Slov Oftalmol.* 2016;72(5):178–81.
13. Fernandes JB, Matayoshi S, Komatsu W, Kikuta HS, Moura EM. Circuito elétrico auxiliar para intubação das vias lacrimais. *Arq Bras Oftalmol.* 2000;63(5):375–7.
14. Smaniotto AP, Gazim CC, Moreira H, Kormann RB, Bezerra VL. Obstrução congênita de vias lacrimais: série de casos de sondagem e intubação. *Rev Bras Oftalmol.* 2016;75(1):30–3.
15. Lim CS, Martin F, Beckenham T, Cumming RG. Nasolacrimal duct obstruction in children: outcome of intubation. *J AAPOS.* 2004;8(5):466–72.
16. Zhang C, Yu G, Cui Y, Wu Q, Wei W. Anatomical Characterization of the Nasolacrimal Canal Based on Computed Tomography in Children With Complex Congenital Nasolacrimal Duct Obstruction. *J Pediatr Ophthalmol Strabismus.* 2017;54(4):238–43.

---

**Corresponding author:**

Bruno Hirt

Rua Buenos Aires, 492, Batel, Curitiba, PR, 80250-070, Brazil.

E-mail: brunohirt.med@gmail.com.