

Qualitative aspects of ruptures and thinnings of Descemet's membrane in histopathological examination

Aspectos qualitativos das rupturas e afinamentos da membrana de Descemet no exame histopatológico

Karine Feitosa Ximenes¹, Karla Feitosa Ximenes Vasconcelos², Fernando Queiroz Monte¹

ABSTRACT

Objective: To describe the different types of ruptures and thinning of Descemet's membrane found in the histopathological examination, questioning a possible relationship between them. **Methods:** Observational, transversal, retrospective and descriptive study of corneal buttons from penetrating keratoplasty during the randomly chosen period of four years: 2006, 2010, 2014 and 2015. The staining was performed with hematoxylin-eosin (HE). After preparation, the authors examined the tissues with an optical microscope. We selected only the cases of rupture or thinning of Descemet's membrane in histopathological examination and classified the different types of these findings. **Results:** The ruptures found were classified as total or common, partial, fracture and bevel. The thinnings were divided into generalized, localized and extensive. **Conclusion:** We presented several nuances of Descemet's membrane ruptures and thinning in histopathological examination. Considering only mechanical aspects, the findings suggest a possible relationship between thinning and rupture as cause and effect.

Keywords: Descemet's membrane/pathology; Ruptures; Cornea; keratoplasty

RESUMO

Objetivo: Descrever os diferentes tipos de rupturas e afinamentos da membrana de Descemet encontrados no exame histopatológico, questionando uma possível relação entre eles. **Métodos:** Estudo observacional, transversal, retrospectivo e descritivo de botões corneanos provenientes de ceratoplastia penetrante, durante o período escolhido de forma aleatória de quatro anos: 2006, 2010, 2014 e 2015. A coloração foi realizada com Hematoxilina-eosina (HE). Após o preparo, os tecidos foram examinados com microscópio óptico pelos autores. Selecionamos apenas os casos de rupturas ou afinamento da membrana de Descemet no exame histopatológico, e classificamos os diferentes tipos desses achados. **Resultados:** As rupturas encontradas foram classificadas em total ou comum, parcial, fratura e bisel. Os afinamentos foram divididos em generalizado, localizado e extensivo. **Conclusão:** Apresentamos várias nuances das rupturas e dos afinamentos da membrana de Descemet no exame histopatológico. Os achados sugerem, considerando apenas aspectos mecânicos, uma possível relação entre afinamento e ruptura como causa e efeito.

Descritores: Lâmina limitante posterior/patologia; Ruptura; Cornea; Ceratoplastia

¹ Department of Ocular Pathology, Banco de Olhos, Hospital Geral de Fortaleza, Fortaleza, CE, Brazil.

² Department of Medical Residency in Ophthalmology, Hospital Geral de Fortaleza, Fortaleza, CE, Brazil.

Institution where the study was carried out: Banco de Olhos do Hospital Geral de Fortaleza

The authors declare no conflict of interests.

Received for publication 24/05/2018 - Accepted for publication 29/07/2018.

INTRODUCTION

The Descemet's membrane is the basal membrane of the corneal endothelium,⁽¹⁾ being secreted by it from approximately 4 months of gestation.⁽²⁾ At ultrastructural level, two zones can be identified - an anterior banding formed in fetal life, and a posterior non-banding that increases in thickness during adult life.⁽³⁾

Defects in Descemet's membrane lead to the influx of aqueous humor in the cornea and stromal edema.⁽⁴⁾ Edema is usually associated with loss of transparency of the cornea in the portion in which it is present.⁽⁵⁾ In a previous study of our group, we called Descemet's integrity changes the ruptures and detachments in which we questioned a possible relation between them.⁽⁶⁾

Ruptures on Descemet's membrane are described associated with ceratoglobus,⁽⁷⁾ phacoemulsification,⁽⁸⁻¹⁰⁾ congenital glaucoma,⁽¹¹⁾ non-accidental presumed lesion,⁽¹²⁾ keratoconus,⁽¹³⁾ complicated labor with forceps,⁽¹⁴⁻¹⁶⁾ prolonged labor,⁽¹⁵⁾ Acanthamoeba keratitis,⁽¹⁷⁾ Terrien marginal degeneration.⁽¹⁸⁾ Reports of spontaneous ruptures are also present, although they are few.⁽¹⁹⁾ It is important to differentiate Descemet's rupture from other entities such as syphilitic interstitial keratitis, posterior polymorphous dystrophy, and hereditary congenital endothelial dystrophy that may have a similar clinical condition. Although treatment is rarely necessary, correct diagnosis is important to avoid unnecessary referrals and provide adequate counseling.⁽¹⁵⁾ Some studies mention histopathological examination in cases of Descemet's membrane ruptures, but most do not go into the morphological details of these findings.^(10,11,13,14,19-21)

Unlike the subject of ruptures in which we find abundant material, although less numerous when we refer to histopathological examination and approach different from the one we intended, when we think of thinning Descemet's membrane the subject becomes scarce.

Thus, we aim to describe the different types of ruptures and thinning of Descemet's membrane found in the histopathological examination, questioning a possible relation between them.

METHODS

We carried out an observational, transverse, retrospective and descriptive study of corneal buds from penetrating keratoplasty sent for histopathological examination at Banco de Olhos do Hospital Geral de Fortaleza during a period of four years: 2006, 2010, 2014 and 2015, which accounted for 300 cases. These years were chosen at random among those since the founding of Banco de Olhos: 2006 to 2016. The tissues were first sent to the and fixed in neutral formalin 10% and cut out. The inclusion was made in paraffin, with subsequent cuts of 2µm and staining with Hematoxylin-eosin (HE). After preparation, the tissues were examined under an optical microscope by the authors.

We selected only the cases in which ruptures or thinning of the Descemet's membrane could be identified by histopathological examination, and we classified the different types of these findings. We excluded the cases that had Descemet's membrane fully or totally detachable.

Since we carried out a retrospective and descriptive study, probability statistics was not used.

RESULTS

We classified the ruptures found in total or common, partial, fracture and bevel; and the thinning, in general, as localized and extensive (Table 1)..

Table 1
Types of thinning and ruptures found in histopathological examination of the sample studied

Ruptures	Thinning
- Total	- Generalized
- Partial	- Localized
- Fracture	- Extensive
- Bevel	

We call total or common rupture (Figures 1 and 2) that in which there was a complete loss of the continuity of Descemet's membrane; and partial (Figures 2, 3 and 4) that which led to the loss of incomplete continuity. Fractures (Figure 4) were those ruptures with closely adjacent edges, and on the bevels there was thinning in at least one end (Figures 5 and 6).

According to our classification, generalized thinning (Figure 7) was that involving the Descemet's membrane in all its extension, and the localized ones (Figure 2) covered only part of it. Extensive thinning (Figures 1 and 8) were larger than the localized ones, but also did not completely involve the Descemet's membrane as the generalized ones.

In order to confirm the presence of generalized thinning, we compared the thickness of the Descemet's membrane with that of the corneal endothelium. When the endothelium and Descemet had similar thicknesses, or when it was thinner than that, we had the generalized thinning. Localized thinning, in turn, was evident by a sudden or progressive change in a certain extent of said membrane.

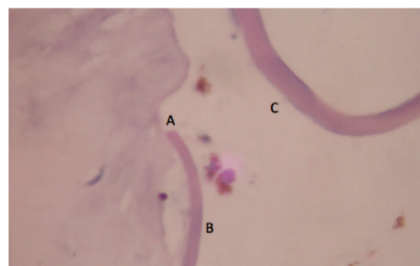


Figure 1: Total or common rupture (A) below on thinned Descemet's membrane (B) (extensive thinning). Above, we see a Descemet of normal thickness (C). (Ximenes, Vasconcelos e Monte – paraffin, H.E. – 400x)

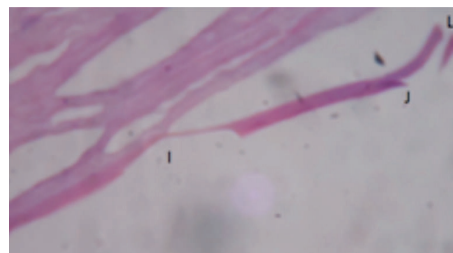


Figure 2: Further to the left, localized thinning of Descemet's membrane (I) which is followed by partial rupture (J) and then total rupture (L). (Ximenes, Vasconcelos e Monte – paraffin, H.E. – 400x).

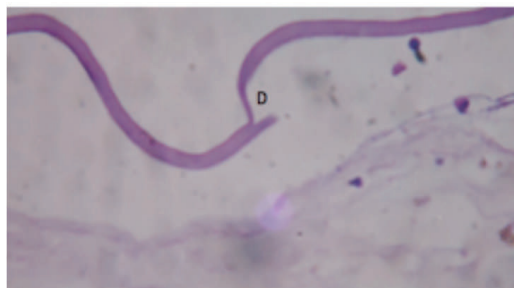


Figure 3: Partial rupture of Descemet's membrane (D). (Ximenes, Vasconcelos e Monte – paraffin, H.E. – 400x).

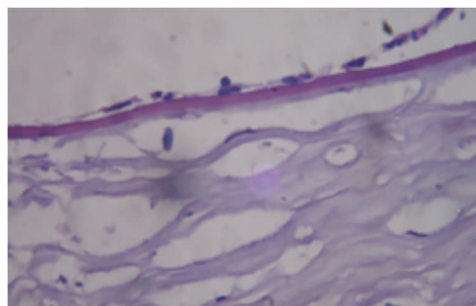


Figure 7: Generalized thinning of Descemet's membrane where we observed that this membrane is almost equal in thickness to that of the corneal endothelium. (Ximenes, Vasconcelos e Monte – paraffin, H.E. – 400x).

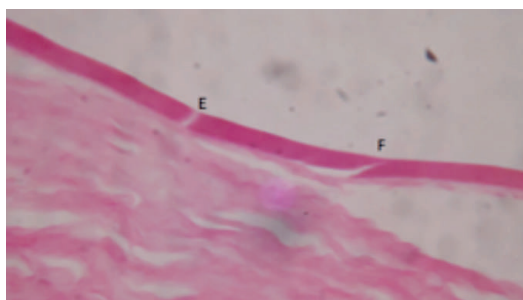


Figure 4: On the left, Descemet's membrane fracture (E). On the right, partial rupture (F). (Ximenes, Vasconcelos e Monte – paraffin, H.E. – 400x).

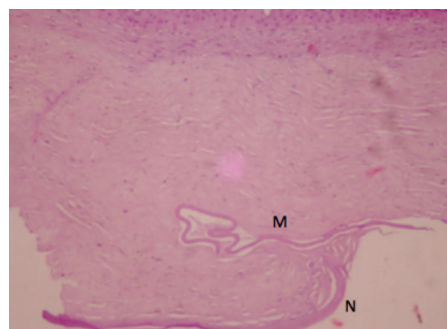


Figure 8: Extensive thinning of Descemet's membrane in the portion where it lies within the stroma (M). In the lower part of the picture we observed normal membrane thickness (N). (Ximenes, Vasconcelos e Monte – paraffin, H.E. – 100x).

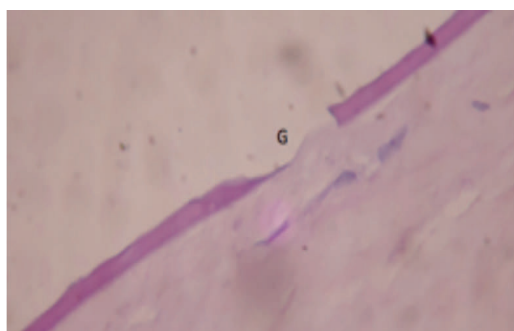


Figure 5: Bevel rupture where thinning is observed only at one end of the rupture (G). (Ximenes, Vasconcelos e Monte – paraffin, H.E. – 400x).

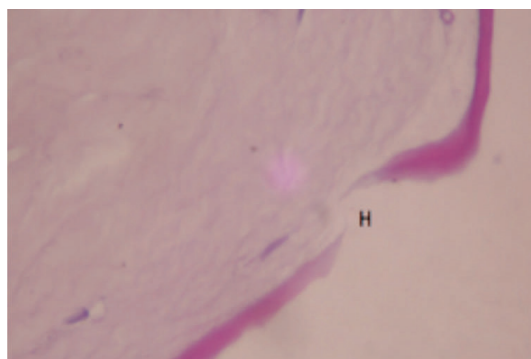


Figure 6: Rupture in bevel where we observed thinning at both ends of the rupture (H). (Ximenes, Vasconcelos e Monte – paraffin, H.E. – 400x).

DISCUSSION

We studied the different aspects of the ruptures and thinning of Descemet's membrane in the histopathological examination. As previously mentioned, histopathological examination in cases of ruptures is mentioned in some studies, but most do not describe many morphological details.^(10,11,13,14,19-21) Studies on ruptures in this membrane still have an approach different from ours and the one demonstrated in the results. It is mentioned in the literature that the histopathological examination is used to confirm the diagnosis of rupture and detachment^(10,19) and for differentiation between Haab striae and the bands found in cases of posterior polymorphic dystrophy.⁽¹¹⁾

Wolter et al. describe the entire histopathological examination of a cornea of a young man with precocious unilateral keratoconus who underwent transplant after repeated episodes of hydropsy, and mention the existence of three areas of old ruptures.⁽¹³⁾ Thickness of the rupture edges is also mentioned in the histopathological examination.^(14, 20) Honig et al. describe four main types of histopathological features in corneal lesions by forceps or vacuum extraction: type I included large Descemet's membrane ruptures extending into the anterior chamber at one end and coiled formation at the other, type II consisted of Descemet's membrane coils at each margin of the original rupture, type III included those with small ruptures in the Descemet of and fibrosis healing in and after the original rupture, and type IV contained a small rupture in Descemet's membrane with minimal fibrosis.⁽¹⁶⁾ Our classification of ruptures

differs, however, from that of Honig et al.⁽¹⁶⁾ We divided the ruptures into total or common, partial, fracture and bevel types (Table 1). Differently from type III and IV of Honig et al.⁽¹⁶⁾ e do caso de Wolter et al.,⁽¹³⁾ our cases were recent because they did not present fibrosis.

The subject alterations in the thickness of Descemet's membrane seems to us even less mentioned in the literature than ruptures, either in histopathological examination or its clinical appearance. As far as our knowledge goes, thinning mentioned in the literature is restricted to Descemet's embryological origin, which is thinner in children than in the elderly. At birth, it is approximately 3µm thick, but later in adult life it can measure up to 12µm. Its increase during life is comparable to the thickening of other basal membranes of the body, including that of the basal membrane of the corneal epithelium.⁽¹⁾ When referring to the increase in the thickness of Descemet's membrane, an irregular thickening or thickness with focal absences and multilayer Descemet is mentioned in the posterior polymorphous dystrophy.⁽²²⁾ Ni et al also describe an abnormal thickness of the Descemet's membrane with the multilayer structure in the peripheral part of the cornea as a new histopathological finding in a patient with Peters anomaly.⁽²³⁾ In our classification, we divided the thinning into generalized, localized and extensive (Table 1).

Our findings aim to emphasize a possible relation between thinning and ruptures. In our view, the finding of bevel-shaped ruptures especially at two of its ends (Figure 6) would suggest that localized thinning could be a strong component in the cause of ruptures. The finding of Figure 2 of a localized thinning demonstrating the presence of progressive decrease of the thickness on one side and abrupt on the other would also reinforce our hypothesis, which could mean the evolution of the thinning to a rupture, probably demonstrated in the future as in figure 5 (one straight edge and another bevel). Partial rupture (Figures 2, 3 and 4) is also questioned by us as being able to evolve to total rupture.

The hypotheses we have drawn up in the present study are based on the analysis of the alterations in the structure of the Descemet's membrane, more specifically thinning and ruptures, where we questioned if the former would be determining factors to the appearance of the latter. Not that we do not claim this to be the most important possibility, but it was the one that could be found in a retrospective sample like ours and with which we agree. We emphasize the importance of the subject, considering the possible clinical implication of Descemet's membrane defects through corneal edema, as we have already mentioned.⁽⁴⁻⁶⁾

CONCLUSION

We present several nuances of Descemet's membrane ruptures and thinning in histopathological examination. The findings suggest, considering only mechanical aspects, a possible relation between thinning and rupture as cause and effect.

REFERENCES

- Gipson IK, Joyce NC, Zieske JD. The anatomy and cell biology of the human cornea, limbus, conjunctiva and adnexa. In: Foster CS, Azar DT, Dohlman CH, Smolin and Thoft's The Cornea: Scientific Foundation and Clinical Practice. 4th ed. Philadelphia: Lippincott Williams and Wilkins; 2005. p. 1-37.
- Klyce SD, Beuerman RW. Structure and function of the cornea. In: Kaufman HE, Barron BA, McDonald MB. The cornea. 2nd ed. Oxford: Butterworth-Heinemann; 1998. p. 3-50.

- Sehu KW, Lee WR. Ophthalmic pathology: An illustrated guide for clinicians. Massachusetts: Blackwell Publishing; 2005.
- Naumann GO, Holbach L, Kruse FE. Applied pathology for ophthalmic microsurgeons. Berlin: Springer; 2008.
- Goldman JN, Kuwabara T. Histopathology of corneal edema. *Int Ophthalmol Clin.* 1968;8(3):561-79.
- Ximenes KF, Silva JV, Vasconcelos KF, Monte FQ. O papel da membrana de Descemet na patogenia do edema corneano após cirurgia de segmento anterior. *Rev Bras Oftalmol.* 2014;73(5):262-8.
- Palioura S, Chodosh J, Pineda R. A novel approach to the management of a progressive Descemet membrane tear in a patient with keratoglobus and acute hydrops. *Cornea.* 2013;32(3):355-8.
- Wang Y, Guan H. A case of Descemet's membrane detachments and tears during phacoemulsification. *Ther Clin Risk Manag.* 2015;11:1727-9.
- Orucoglu F, Aksu A. Complex Descemet's Membrane Tears and Detachment during Phacoemulsification. *J Ophthalmic Vis Res.* 2015;10(1): 81-3.
- Morkin MI, Hussain RM, Young RC, Ravin T, Dubovy SR, Alfonso EC. Unusually delayed presentation of persistent Descemet's membrane tear and detachment after cataract surgery. *Clin Ophthalmol.* 2014;8:1629-32.
- Cibis GW, Tripathi RC. The differential diagnosis of Descemet's tears (Haab's striae) and posterior polymorphous dystrophy bands. A clinicopathologic study. *Ophthalmology.* 1982;89(6):614-20.
- Bhagat S, Mikhail M, Boyle N. Rupture of Descemet's membrane secondary to presumed non-accidental injury. *Eye (Lond).* 2015;29(5):716-8.
- Wolter JR, Henderson JW, Clahasse EG. Ruptures of Descemet's Membrane in Keratoconus: Causing Acute Hydrops and Posterior Keratoconus. *Am J Ophthalmol.* 1967;63(6):1689-92.
- Haddock LJ, Dubovy SR, Perez VL. Histopathological findings after descemet's stripping automated endothelial keratoplasty for the management of descemet's membrane breaks secondary to obstetrical forceps injury. *Case Rep Ophthalmol Med.* 2012; 2012: 474795.
- Nelson MD. Rupture of Descemet's membrane secondary to presumed forceps trauma. *Clin Eye Vis Care.* 1995;7(4):195-201.
- Honig MA, Barraquer J, Perry HD, Riquelme JL, Green WR. Forceps and vacuum injuries to the cornea: histopathologic features of twelve cases and review of the literature. *Cornea.* 1996;15(5):463-72.
- Guerriero S, La Tegola MG, Monno R, Apruzzese M, Cantatore A. A case of Descemet's membrane rupture in a patient affected by Acanthamoeba Keratitis. *Eye Contact Lens.* 2009;35(6):338-40.
- Guyer DR, Barraquer J, McDonnell PJ, Green WR. Terrien's marginal degeneration: clinicopathologic case reports. *Graefes Arch Clin Exp Ophthalmol.* 1987;225(1):19-27.
- Ruiz RS, Saatici OA. Spontaneous Descemet's Membrane Tear and Detachment. *Arch Ophthalmol.* 1991;109(1):20-21.
- Hoang-Xuan T, Renard G, Pouliquen Y, Savoldelli M, Elalouf M. [Breaks in Descemet's membrane. Association with secondary warts. Histologic and ultrastructural study]. *J Fr Ophthalmol.* 1986;9(11):731-41. French.
- Cason JB, Yiu SC. Acute hydrops in the donor cornea graft in non-keratoconus patients. *Middle East Afr J Ophthalmol.* 2013;20(3):265-267.
- Weisenthal RW, Streeten BW. Descemet's membrane and endothelial dystrophies. In: Krachmer JH, Mannis MJ, Holland EJ. *Cornea: fundamentals, diagnosis and management.* 3rd ed. New York: Mosby Elsevier; 2011. p.845-64.
- Ni W, Wang W, Hong J, Zhang P, Liu C. A novel histopathologic finding in the Descemet's membrane of a patient with Peters Anomaly: a case-report and literature review. *BMC Ophthalmol.* 2015;15:139.

Corresponding author:

Karine Feitosa Ximenes
E-mail: karinefx@gmail.com