

Intraconal plasmocytoma and uveal infiltration in a patient with multiple myeloma

Plasmocitoma intraconal e infiltração uveal em paciente portadora de mieloma múltiplo

Ana Paula da Silva Maganhoto¹, Sara Correia¹, Roberto Ivo Pasquarelli Neto²

ABSTRACT

Multiple myeloma (MM) leads to disorderly proliferation of plasma cells clones, producing monoclonal immunoglobulin and commonly presents osteolytic lesions. In some cases, however, masses called plasmocytomas are found. Ocular and orbital involvement is unusual in this pathology. In this paper, we describe a case of a 63 year-old patient with previous diagnostic of MM that evolved an intraconal plasmocytoma in the right eye, as well as a vascularized mass in the anterior chamber from uveal infiltration. These lesions were correlated to MM e lead to visual loss in the affected eye. Reports of intraconal plasmocytoma have not been found in literature.

Keywords: Multiple myeloma; Plasmocytoma; Eyeneoplasms; Orbital neoplams; Case reports

RESUMO

Mieloma múltiplo (MM) é uma neoplasia que cursa com a proliferação desordenada de clones de plasmócitos, produzindo imunoglobulina monoclonal e normalmente se apresenta como lesões osteolíticas. Em alguns casos, porém, esta doença apresenta-se como massas, chamadas de plasmocitomas. O acometimento ocular e orbitário é incomum nesta patologia. Neste trabalho, descrevemos o caso de uma paciente de 63 anos com diagnóstico prévio de MM que evoluiu com um plasmocitoma intraconal em olho direito, bem como uma massa vascularizada câmara anterior proveniente de infiltração uveal. Essas lesões foram correlacionadas MM e culminaram com a perda visual no olho acometido. Não foi encontrado na literatura relatos de plasmocitoma intraconal.

Descritores: Mieloma múltiplo; Plasmocitoma; Neoplasias oculares; Neoplasias orbitárias; Relatos de casos

¹ Residency Program, Ophthalmology Serviceb, Irmandade Santa Casa de Misericórdia de Santos, Santos, SP, Brazil.

² Ophthalmology Service, Santa Casa de Misericórdia de Santos, Santos, SP, Brazil.

The authors declare no conflict of interests.

Received for publication 16/12/2016 - Accepted for publication 04/11/2017.

INTRODUCTION

Multiple myeloma (MM) is an hematologic neoplasia that courses with proliferation of plasma cells.(1-2) Its main manifestations occur in the bones, in the form of osteolytic lesions. However, it may also be in the form of isolated bone or extramedullary plasmacytomas.(1)

Ocular and orbital involvement in this pathology is rare. Published articles mention retinal changes due to the state of hypercoagulability, extraconal masses (plasmacytomas), and ciliary body and iris cysts.

The objective of the present study is to report the case of a patient with previous diagnosis of MM, whose development proceeded with intraconal plasmacytoma in the right eye, as well as mass in the anterior chamber suggestive of uveal infiltration secondary to the underlying disease. There are no reports in the literature of cases similar to those presented in the present study.

CASE REPORT

E.N.O., 63, female, white, was admitted to the emergency department of Ophthalmology at Irmandade Santa Casa de Misericórdia de Santos, Brazil, complaining of low visual acuity (LVA) in the right eye (RE) initiated one day before of the appointment, preceded by diplopia, unilateral headache and increased RE volume three days before.

She had a history of multiple myeloma (MM) diagnosed in December 2015, and underwent five chemotherapy sessions with velcade, cyclophosphamide and zometa in April 2016.

At the time of the appointment, she was taking acyclovir 200mg and antidepressant medications.

The patient had exams corroborating the diagnosis of MM: bone scintigraphy with ^{99m}Tc with heterogeneous uptake in the skullcap, thoracic and lumbar columns, basal bones and proximal thirds of the femurs; magnetic resonance imaging (MRI) of the pelvis with expansive lesion in the anterior region of the left iliac bone, with soft parts component, measuring 5.0x4.8cm and multiple scattered nodular lesions in the basin bones; myelogram with 35% of plasma cells with moderate degree of atypia (Table 1A); protein electrophoresis with a monoclonal component migrating in the gamma globulin region (Table 1 B).

Table 1
Lab exams

A - Myelogram

Puncture: sternal

Celularity: slightly increased

Leuco/erythroblasts: 4,0

Red series: moderate hypoplasia, predominance of orto and polychromatic erythroblasts, deviation to the right, discrete anisocytosis.

Granulocyte series: discrete neutropenia with mild deviation to the right; relative basophilia. No evidence of eosinophils or atypia.

Lymphocytes and plasma cells: about 35% nucleated elements are plasma cells with moderate atypia. Some cell nests and rare Mott cells.

Megalocytic series: normoplasia.

B - Protein electrophoresis

Total proteins: 10.6 g/dL

Albumin/globulin: 0,72

Albumin: 4.44 g/dL

Alpha 1 globulin: 0.29 g/dL

Alpha 2 globulin: 1.08 g/dL

Beta 1 globulin: 0.43 g/dL

Beta 2 globulin: 0.20 g/dL

Gamma globulin: 4.16 g/dL

The ophthalmologic exam showed uncorrected visual acuity (VA) in the RE with no light perception (NLP) and in the left eye (LE) of 20/200 in the Snellen table (the patient had cataract, without improvement with correction in the LE); intraocular pressure (IOP) of 10 mm Hg in both eyes.

Ectoscopy showed proptosis in the RE and change of ocular movement in several positions, mainly at abduction of the RE (Figure 1).

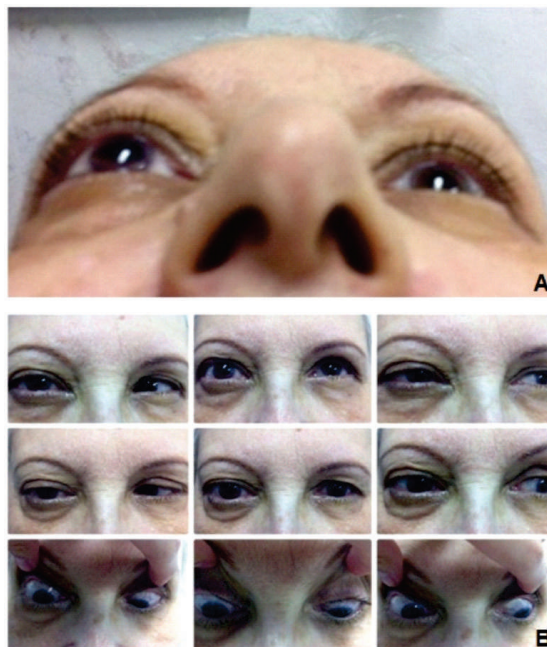

Figure 1: A) showing the right eye proptosis; B) with change of the ocular movement of right eye.

Biomicroscopy of the RE showed the presence of a vascularized mass in a lower iridocornean angle, causing corectopia. Fundoscopy was within the normal range in both eyes.

The patient was hospitalized at the ophthalmology care unit for sudden LVA investigation. Computed tomography (CT) of the skull and orbits was performed, presenting a soft tissue density mass with limits partially defined in the right intraconal projection without cleavage plane measuring 2.6x1.3cm (Figure 2A); and MRI of the skull and orbits showing a right retro-orbital expansive lesion measuring 3.6cm, which conditioned the optic nerve medial displacement and proptose of the ocular globe (Figure 2B).

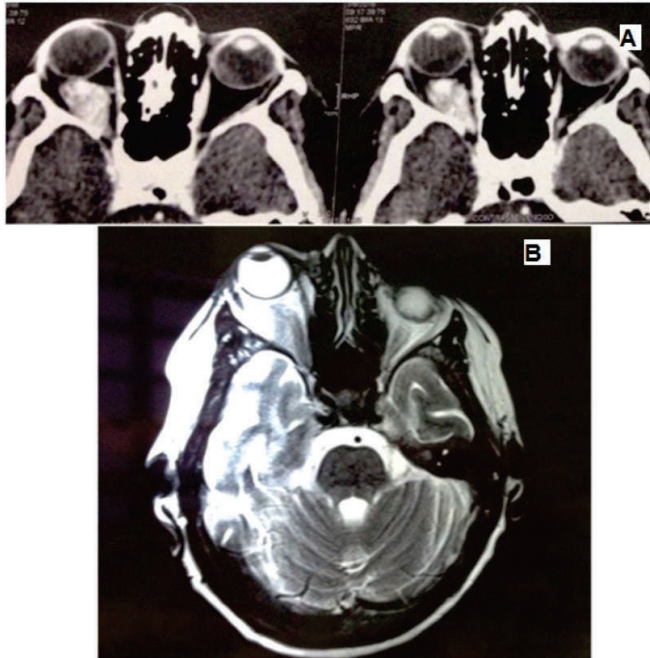


Figure 2: A) superior: tomography of orbits with intraconal mass on the right; B) inferior: magnetic nuclear resonance of orbits with right intraconal mass.

Ultrasonic biomicroscopy of the RE (figure 3) was performed, showing inferior hernoma, 360° narrow angle, anterior synechia, topical crystalline and uveal infiltrate invading the anterior chamber. Ultrasonography of the RE revealed a tumor in the region of intraconal orbital fat, with no evidence of direct intraocular invasion.

The head and neck surgery team performed endonasal biopsy of the intraconal lesion. Histopathology revealed small cell neoplasm with invasion of skeletal and muscular tissue, and immunohistochemistry was compatible with infiltration by multiple myeloma / plasmacytoma (CD138 and CD99 positive).

Patients and their families were advised for visual prognosis. The patient was referred to the hematology sector for treatment of the underlying disease, restarting chemotherapy with cyclophosphamide, bortezomid and dexamethasone. We chose not to surgically intervene in the ophthalmologic lesions due to the patient's clinical condition, absence of symptoms (such as pain) and lack of possibility of visual rehabilitation in the RE (vision with NLP). We did not biopsy the lesion in the anterior chamber for the same reasons.

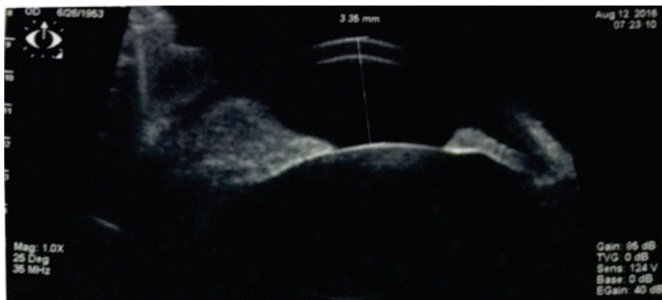


Figure 3: Ultrasonic right-sided biomicroscopy.

DISCUSSION

The irreversible proliferation of a clone of plasma cells producing monoclonal immunoglobulin in the bone marrow is characterized as a neoplasm of plasma cells. This can occur in two forms: an isolated lesion called plasmacytoma, or multiple lesions known as multiple myeloma (MM).⁽¹⁾

Plasmacytomas are histologically similar to MM, and may be bony (solitary bone plasmacytoma) or soft tissue (extramedullary plasmacytoma).⁽¹⁾

MM represents 1% of malignant neoplasms and 10% of hematological neoplasms in the United States. Its incidence is 4:100.000.⁽²⁾ Epidemiologically, it is discretely more frequent in men over 50 years and black. It presents as multiple osteolytic lesions, impairment of bone marrow function, and production and release of monoclonal protein into the bloodstream.⁽²⁻⁵⁾ These changes cause skeletal changes (bone pain, fractures, hypercalcemia), normocytic and normochromic anemia (fatigue, weakness), renal insufficiency, infections, thrombocytopenia, amyloidosis (in 10% of cases) and extramedullary plasmacytomas.^(2,5)

The diagnosis is made by bone marrow biopsy with more than 10% of plasma cells or presence of plasmacytoma and at least one of the following: M monoclonal protein in serum or urine; osteolytic lesions (by activation of osteoclasts).⁽³⁾ The presence of hypercalcemia, renal failure and lesions related to plasma cell proliferation corroborate the diagnosis.⁽⁶⁾ Anemia in this disease occurs due to decreased erythropoiesis.

The patient in the case discussed already had a previous diagnosis of MM, with a myelogram showing 35% of plasma cells with a moderate degree of atypia and imaging tests showing bone lesions.

Ocular and orbital involvement is uncommon in this type of neoplasm. The ocular findings described in the literature are iris and ciliary body cysts, plasmacytoma in the lacrimal gland and vascular alterations in the retina^(3,7) due to the state of hypercoagulability. Involvement of the orbit is rare, but may occur in three ways: isolated plasmacytoma, extramedullary plasmacytoma (usually from the paranasal sinuses) and orbital involvement, being the clinical manifestations most found in these cases the proptosis and alteration of the ocular movement.^(3,6) The onset of an orbital lesion in a patient with MM already treated suggests recurrence of the lesion and insufficient chemotherapy. The most common site of orbital mass is extraconal, superior temporal.⁽⁶⁾ Uveal infiltration by MM is very rare.

In the case reported, the patient presented two ophthalmological manifestations: intraconal plasmacytoma related to the underlying disease, and a mass of uveal infiltrate in the anterior chamber which we can infer to have direct relation with the same due to the history and progression of the MM. In the literature, we did not find other studies correlating two lesions from the MM in a single patient, nor did we find an intraconal mass description, as discussed in the present study.

The patient presented was followed by the hematology team without surgical treatment by the ophthalmology team, since the right eye had no visual prognosis or symptoms, and therefore did not require intervention at the time.

REFERENCES

1. Cardoso I, Secioso P, Moreira, M. Plasmocitoma solitário ósseo. Relato de caso. *Rev Bras Clin Med.* 2010;8(2):183-6.
2. Goldman L, Ausiello D. Cecil: Tratado de Medicina Interna. 23aed. Rio de Janeiro: Elsevier; 2010.
3. Pinho AR, Pinho EA, Alessandri EF, Pereira LS. Tumor orbitário como primeira manifestação clínica de mieloma múltiplo: relato de caso. *Arq Bras Oftalmol.* 2009;72(1):106-8.
4. Silva RO, Brandão KMA, Pinto PVM, Faria RMD, Clementino NCD, Silva CMF et al. Mieloma múltiplo: características clínicas e laboratoriais ao diagnóstico e estudo prognóstico. *Rev Bras Hematol Hemoter.* 2009; 31(2):63-8.
5. Klaus DG, Carvalho DC, Baldessar MZ. Caso clássico de mieloma múltiplo: uma revisão. *ACM Arq Catarin Med.* 2009; 38(4): 110-3.
6. Gentile MC, Vigo RR, Basso TO, Fantl D. Compromiso orbitario en mieloma múltiple. *Oftalmol Clin Exp.* 2010; 3(4):151-54
7. Romero IL, Campos FA, Damasceno RW, Vital Filho J, Bison SH. Plasmacytoma of the orbit involving lacrimal gland with secondary transformation into multiple myeloma: case report. *Arq Bras Oftalmol.* 2009;72 ;(2):236-8.

Corresponding author:

Ana Paula da Silva Maganhoto
Dr. Claudio Luis da Costa, 50, Jabaquara - Department of Ophthalmology – Irmandade de Santa Casa de Misericórdia de Santos - Santos (SP) – 11075-900
Phone N°.: +55 13 3202-0600
E-mail: anamaganhoto@hotmail.com