

# Ocular sporotrichosis: atypical manifestations

## *Esporotricose ocular: manifestações atípicas*

Letícia de Oliveira Furtado<sup>1</sup> <https://orcid.org/0000-0001-8201-1325>  
Ana Luiza Biancardi<sup>2</sup> <https://orcid.org/0000-0002-0169-7001>  
Leonardo Medling de Souza Cravo<sup>3</sup> <https://orcid.org/0000-0002-4520-2525>  
Raquel Perrota Pioli Anjo<sup>4</sup> <https://orcid.org/0000-0002-2257-5417>  
Haroldo Vieira de Moraes Junior<sup>5</sup> <https://orcid.org/0000-0003-2562-6942>

### ABSTRACT

*Human and animal sporotrichosis is an infection caused by the dimorphic fungus *Sporothrix schenckii*, which is classified from subacute to chronic. Ocular sporotrichosis has been highlighted due to the epidemic of urban sporotrichosis faced by the state of Rio de Janeiro in the last decade and presents classically as granulomatous conjunctivitis, but atypical forms may occur. This article aims to report two atypical cases of ocular sporotrichosis in immunocompetent patients, both presenting a clinical picture compatible with Parinaud oculoglandular syndrome associated with dacryocystitis in one case and presumably to choroiditis in the other case.*

**Keywords:** Sporotrichosis; Ocular motility disorders; Choroiditis; Dacryocystitis

### RESUMO

A esporotricose humana e animal é uma infecção subaguda a crônica causada pelo fungo dimórfico *Sporothrix schenckii*. A esporotricose ocular tem ganhado destaque em função da epidemia de esporotricose urbana enfrentada pelo estado do Rio de Janeiro na última década e se apresenta classicamente como conjuntivite granulomatosa, mas formas atípicas podem ocorrer. Este artigo tem por objetivo relatar 2 casos atípicos de esporotricose ocular em pacientes imunocompetentes, ambos apresentando quadro clínico compatível com a síndrome oculoglandular de Parinaud associada à dacriocistite em um caso e presumivelmente à coroidite no outro caso.

**Descritores:** Esporotricose; Transtornos da motilidade ocular; Coroidite; Dacriocistite

<sup>1</sup> Ophthalmology Service, Hospital Universitário Clementino Fraga Filho, Universidade Federal do Rio de Janeiro, Rio de Janeiro, RJ, Brazil.

<sup>2</sup> Postgraduate Program in Surgical Sciences / Ophthalmology, Universidade Federal Do Rio de Janeiro, Rio de Janeiro, RJ, Brazil.

<sup>3</sup> Postgraduate Program in Surgical Sciences / Ophthalmology, Universidade Federal Do Rio de Janeiro, Rio de Janeiro, RJ, Brazil

<sup>4</sup> Ophthalmology Service, Hospital Universitário Clementino Fraga Filho, Universidade Federal do Rio de Janeiro, Rio de Janeiro, RJ, Brazil.

<sup>5</sup> Ophthalmology Department, Universidade Federal do Rio de Janeiro, Rio de Janeiro, RJ, Brazil.

**The authors declare no conflicts of interests.**

Received for publication 16/03/2018 - Accepted for publication 21/05/2018.

## INTRODUCTION

The ocular infection by *Sporothrix schenckii* has been studied due to the epidemic of urban sporotrichosis in the state of Rio de Janeiro in the last decade.<sup>(1-5)</sup> Sporotrichosis is classified as subcutaneous or extracutaneous, with the first being the main manifestation of the disease.<sup>(3,6-8)</sup> The extracutaneous manifestation is uncommon, being more frequent in immunocompromised patients.<sup>(6,7,9)</sup>

The most frequent manifestation of ocular sporotrichosis is granulomatous conjunctivitis caused by the direct inoculation of the fungus. However, rare atypical manifestations such as multifocal choroiditis and dacryocystitis have already been described.<sup>(10,11)</sup>

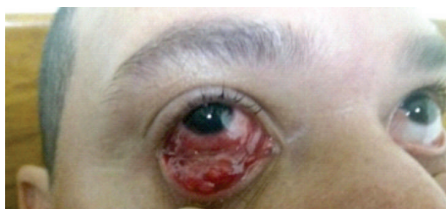We report 2 atypical cases of ocular sporotrichosis in immunocompetent patients, both presenting a clinical condition compatible with the Parinaud oculoglandular syndrome associated to contralateral choroiditis in one case, and to dacryocystitis in the other case.

## CASE REPORT

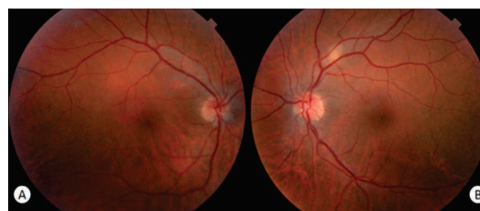
### Case 1

A.L.G.O., a 50-year-old male, bricklayer, resident of Santa Cruz - Rio de Janeiro - RJ, sought treatment with complaint of ocular hyperemia, pruritus, photophobia and secretion in the right eye (RE) associated to worsening of sight with onset 5 days before. He denied systemic signs and symptoms or comorbidities.

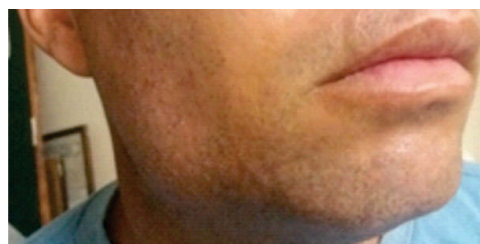
At the ophthalmologic exam, he presented visual acuity (VA) equal to the count of fingers at 5 meters in the right eye (RE), and 20/25 in the left eye (LE). Biomicroscopy revealed small, hyperemic nodules associated with the follicular reaction and mild mucoid secretion in the lower right tarsal conjunctiva (Figure 1). Biomicroscopic examination of the LE and tonometry showed no alterations. Fundoscopy revealed normal exam of the RE, and the LE demonstrated a rounded, yellowish choroidal lesion with regular contours measuring approximately one optic disc of diameter adjacent to the inferior temporal arch (Figure 2). In addition, the patient's ectoscopy showed hardened painful submandibular and pre-auricular ipsilateral lymphadenopathy enlargement (Figure 3). Thus, the following complementary tests were carried out: swab of the conjunctival secretion for culture in Sabourraud and Mycosel media, serology for syphilis (VDRL and FTA-Abs), HIV, PPD and chest X-ray. The swab was positive for *Sporothrix.sp*, the serologies were negative, the chest X-ray was normal, and the PPD was equal to 7mm. The patient was treated with itraconazole 200 mg/day for 3 months, and presented a considerable clinical improvement with VA equal to 20/30 in the RE and 20/25 in LE, resolution of lymphadenomegaly (Figure 4A), conjunctivitis (Figure 4B), and cicatrization of the choroiditis focus (Figure 4C).



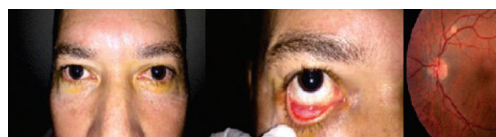**Figure 1:** Hyperemic nodules associated with the follicular reaction and mild mucoid secretion in the lower tarsal conjunctiva of the right eye.



**Figure 2:** Retinography A. Normal funduscopy in the right eye B. Fundoscopy showing coroid and rounded lesion of regular contours adjacent to the inferior temporal arch in the left eye.



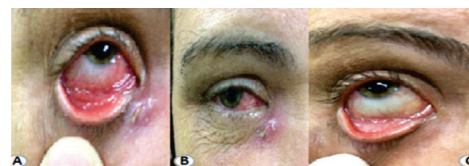
**Figure 3:** Submandibular and pre-auricular lymphadenopathy on the right.



**Figure 4:** A. A. Resolution of submandibular and preauricular lymphadenopathy enlargement B. Resolution of granulomatous conjunctivitis after treatment C. Resolution of choroiditis focus in the left eye after treatment

### Case 2

J.G.S., 46 years, female, house cleaner, resident in Belford Roxo - RJ, sought treatment for edema and hyperemia in the lower eyelid of the RE associated to mucoid secretion, pain, edema, and hyperemia on topography of the tear canal for one month. In addition, she reported contact with street cats and a history of sporotrichosis outbreak in the neighborhood. She denied systemic signs and symptoms or comorbidities. The ophthalmologic examination presented VA equal to 20/25 in BE. Biomicroscopy revealed small hyperemic nodules in the lower tarsal conjunctiva of the RE and dacryocystitis (Figure 5A and 5B). Ectoscopy showed hardened painful lymphadenopathy in the ipsilateral submandibular region. Therefore, considering the clinical condition of the patient, the Parinaud oculoglandular syndrome was diagnosed associated with dacryocystitis, and a swab of conjunctival secretion was performed for culture in the media Sabourraud and Mycosel, with positive result for *Sporothrix.sp*. Thus, treatment with itraconazole 200mg/day for 3 months was initiated, with resolution of the condition (Figure 5C).



**Figure 5:** A. A. Hyperemic nodules in the lower tarsal conjunctiva of the right eye B. Dacryocystitis in the right eye C. Resolution of granulomatous conjunctivitis and dacryocystitis.

## DISCUSSION

Human and animal sporotrichosis is a chronic subacute infection caused by the dimorphic fungus *Sporothrix schenckii*. (2,4,6,7,12-14) The species comprises at least six phylogenetically different species that are grouped in different geographic regions, mainly in temperate and tropical zones. (6,8,12,14)

The fungus is widely spread in the nature, and can be found associated with planted or decaying organic matter and water. (4,6,8,12) *Sporothrix schenckii* can affect humans of both genders of any age group and race. (6) The infection usually occurs through the traumatic implantation of the fungus on the skin. Ocular manifestations of sporotrichosis usually result from trauma and affect the conjunctiva. (10)

The occurrence of the disease is predominantly associated to the occupation of land cultivation, livestock and mining, particularly in rural areas. (6,12) However, the state of Rio de Janeiro, Brazil, is facing an epidemic of urban sporotrichosis, with an epidemiological profile that is different from the one classically presented. (1-5)

Zoonotic transmission in the home environment occurs through biting, scratching or contact with secretion of infected animals, especially cats. (3,12,13,15) In the present study, both patients have a different occupational profile from that characteristically described as associated to the disease, but they live in urban areas where there is a sporotrichosis epidemic.

The infection is classified as cutaneous and extracutaneous. Cutaneous involvement is the main manifestation of the disease. This manifestation starts with a nodular or ulcerated lesion at the site of fungal inoculation, and follows a regional lymphatic pathway characterized by nodular lesions that ulcerate, cool down, and heal. (2,6,12) Mucosal involvement is uncommon, and mainly affects the ocular mucosa. (16) Parinaud's oculoglandular syndrome is characterized by unilateral granulomatous conjunctivitis associated to painful or non-painful ipsilateral regional lymphadenopathy, and may have signs and symptoms such as low fever, follicular reaction, foreign body sensation, hyperemia and eyelid edema, and may be caused by *Sporothrix* sp, although it is classically associated to the infection with *Bartonella henselae*. (16-18) Atypical manifestations such as dacryocystitis, multifocal choroiditis in severely immunocompromised patients, and endophthalmitis have already been described. (10,11,19)

In the present study, 2 atypical cases of ocular sporotrichosis were described. A similar report of the association between choroiditis or Parinaud's oculoglandular syndrome and sporotrichosis in an immunocompetent patient was not found in the literature. Although the patient had PPD reactor, which could be a confounding factor in the differential diagnosis of choroiditis, there was scarring of the lesion after the use of itraconazole, which is favorable to the presumed diagnosis of choroiditis due to sporotrichosis. Similarly, although dacryocystitis has already been described, (11) the association with Parinaud's oculoglandular syndrome in the present study is uncommon.

Occasionally, sporotrichosis may occur elsewhere, especially in the pulmonary and osteoarticular systems. (7,9,12) The disseminated forms are mainly observed in immunocompromised patients. (6,7,9)

The culture (media Sabouraud and Mycosel) is the gold standard to establish the diagnosis of sporotrichosis. (6,7) Sporotrichosis treatment varies according to the type of disease. As most manifestations are subacute to chronic and localized, oral antifungal agents are generally preferred, with itraconazole being the drug of choice. (6,7,20) Treatment should be continued for two to four weeks after all lesions have been treated, usually lasting three to six months. Amphotericin B should be preferred in severe cases of fatal, visceral or disseminated infection. (6,20)

In conclusion, in face of the epidemic of sporotrichosis in the state of Rio de Janeiro, unusual manifestations of ocular disease were identified; infection with *Sporothrix* sp. should be remembered in the differential diagnosis of Parinaud's oculoglandular syndrome.

## REFERENCES

- Barros MB, Schubach AO, do Valle AC, Gutierrez Galhardo MC, Conceição-Silva F, Schubach TM et al. Cat-transmitted sporotrichosis epidemic in Rio de Janeiro, Brazil: description of a series of cases. *Clin Infect Dis*. 2004;38(4):529-35.
- Barros MB, Schubach TP, Coll JO, Gremião ID, Wanke B, Schubach A. Esporotricose: a evolução e os desafios de uma epidemia. *Rev Panam Salud Publica*. 2010;27(6):455-60.
- Freitas DF, do Valle AC, de Almeida Paes R, Bastos FI, Galhardo MC. Zoonotic Sporotrichosis in Rio de Janeiro, Brazil: a protracted epidemic yet to be curbed. *Clin Infect Dis*. 2010;50(3):453.
- Reis RS, Almeida-Paes R, Muniz MM, Tavares PM, Monteiro PC, Schubach TM, et al. Molecular characterisation of *Sporothrix schenckii* isolates from humans and cats involved in the sporotrichosis epidemic in Rio de Janeiro, Brazil. *Mem Inst Oswaldo Cruz*. 2009;104(5):769-74.
- Silva MB, Costa MM, Torres CC, Galhardo MC, Valle AC, Magalhães MA, et al. Esporotricose urbana: epidemia negligenciada no Rio de Janeiro, Brasil. *Cad Saude Publica*. 2012;28(10):1867-80.
- Mahajan VK. Sporotrichosis: an overview and therapeutic options. *Dermatol Res Pract*. 2014;2014:272376.
- Kauffman CA, Bustamante B, Chapman SW, Pappas PG; Infectious Diseases Society of America. Clinical practice guidelines for the management of sporotrichosis: 2007 update by the Infectious Diseases Society of America. *Clin Infect Dis*. 2007;45(10):1255-65.
- Marimon R, Cano J, Gené J, Sutton DA, Kawasaki M, Guarro J. *Sporothrix brasiliensis*, *S. globosa*, and *S. mexicana*, three new *Sporothrix* species of clinical interest. *J Clin Microbiol*. 2007;45(10):3198-206.
- Janes PC, Mann RJ. Extracutaneous sporotrichosis. *J Hand Surg Am*. 1987;12(3):441-5.
- Biancardi AL, Freitas DF, Valvieste VR, Andrade HB, de Oliveira MM, do Valle AC, et al. Multifocal choroiditis in disseminated sporotrichosis in patients with hiv/aids. *Retin Cases Brief Rep*. 2017;11(1):67-70.
- Freitas DF, Lima IA, Curi CL, Jordão L, Zancopé-Oliveira RM, Valle AC et al. Acute dacryocystitis: another clinical manifestation of sporotrichosis. *Mem Inst Oswaldo Cruz*. 2014;109(2):262-4.
- Lopes-Bezerra LM, Schubach A, Cost RO. Sporothrix schenckii and Sporotrichosis. *An Acad Bras Cienc* 2006; 78 (2): 293-308.
- Kauffman CA. Sporotrichosis. *Clin Infect Dis*. 1999 ;29(2):231-6.
- Ramos-e-Silva M, Vasconcelos C, Carneiro S, Cestari T. Sporotrichosis. *Clin Dermatol*. 2007;25(2):181-7.
- Reed KD, Moore FM, Geiger GE, Stemper ME. Zoonotic transmission of sporotrichosis: case report and review. *Clin Infect Dis*. 1993 Mar;16(3):384-7.
- Ribeiro AS, Bisol T, Menezes MS. Parinaud's oculoglandular syndrome caused by Sporotrichosis. *Rev Bras Oftalmol*. 2010;69(5):317-22.
- Huang MC, Dreyer E. Parinaud's oculoglandular conjunctivitis and cat-scratch disease. *Int Ophthalmol Clin*. 1996;36(3):29-36.
- Oliveira AH, Pereira CA, Sousa LB, Freitas D. Conjuntivite granulomatosa atípica causada pela doença da arranhadura do gato-Relato de caso. *Arq Bras Oftalmol*. 2004;67(3):541-3.
- Cartwright MJ, Promersberger M, Stevens GA. Sporothrix schenckii endophthalmitis presenting as granulomatous uveitis. *Br J Ophthalmol*. 1993;77(1):61-2.
- Kauffman CA. Old and new therapies for sporotrichosis. *Clin Infect Dis*. 1995;21(4):981-5.

### Corresponding author:

Leticia de Oliveira Furtado

E-mail: leticiafurtado09@gmail.com