

Intravenous sodium fluorescein enhances the visibility of vitreous during vitrectomy surgery for diabetic retinopathy

Fluoresceína sódica intravenosa aumenta a visibilidade do vítreo durante a cirurgia de vitrectomia para retinopatia diabética

Rubens Camargo Siqueira¹, Rodrigo Jorge², Fabio Canamary³

ABSTRACT

Objective: To observe the effectiveness of intravenous sodium fluorescein visibility in the vitreous during vitrectomy surgery in patients with diabetic retinopathy. **Methods:** Fourteen consecutive cases of vitreoretinal surgery for vitreous hemorrhage and tractional retinal detachment secondary to diabetic retinopathy underwent intravenous injection of sodium fluorescein to 20% 1 hour before the surgery. The images of the steps of the surgeries were recorded. **Results:** The sodium fluorescein stained green from the vitreous peripheral, vitreous base, posterior hyaloid, further improving visibility to a complete and more secure vitrectomy. The sodium fluorescein also stained fibrous points (sites of neovascularization) with high intensity making it easier its visibility. No complications associated with the dye injection were observed in all cases. **Conclusion:** Intravenous sodium fluorescein can be used safely for facilitating the observation of the vitreous, vitreous base, posterior hyaloid and sites of neovascularization. This technique can facilitate the process of vitrectomy in patients with diabetic retinopathy

Keywords: Fluorescein; Diabetic retinopathy; Vitrectomy

¹Doutor, responsável pelo Centro de Pesquisa Rubens Siqueira - CPRS – São José do Rio Preto (SP), Brasil; Responsável pelo Departamento de Oftalmologia da Faculdade de Medicina de Catanduva – FAMECA – Catanduva (SP), Brasil;

²Colaborador em pesquisa do departamento de Retina da USP - Ribeirão Preto-SP

³Doutor, responsável pelo Departamento de Retina da Faculdade de Medicina de Ribeirão Preto da Universidade de São Paulo - USP - Ribeirão Preto (SP), Brasil;

³Estagiário em Retina e Vítreo no Centro Especializado Retina e Vítreo - CERV - São José do Rio Preto (SP), Brasil.

Trabalho realizado no Centro de Pesquisa Rubens Siqueira – CPRS - São José do Rio Preto (SP), Brasil.

Recebido para publicação em: 17/1/2008 - Aceito para publicação em 21/7/2008

INTRODUCTION

Vitreotomy is the treatment of choice for proliferative diabetic retinopathy with traction or persistent vitreous hemorrhage⁽¹⁾. It can frequently restore useful vision in diabetic patients and reduce the risk of visual loss from traction retinal detachment⁽²⁾.

The use of dilute sterile sodium fluorescein (NaFl) has previously been suggested as an aid in vitrectomy⁽³⁻⁴⁾. Except for two published letters⁽³⁻⁴⁾, there are no large studies describing the safety and efficacy of intravitreal NaFl in vitreous surgery. However, there is a study that described the safety and efficacy to use Intravitreal sodium fluorescein to enhance the visibility of clear vitreous during vitreous surgery for macular hole⁽⁵⁾.

We will describe in this paper the efficacy of Intravenous NaFl for enhances of visibility of vitreous during vitrectomy surgery for diabetic retinopathy.

METHODS

Fourteen consecutive vitreoretinal surgery cases for vitreous hemorrhage and tractional retinal detachment, secondary to diabetic retinopathy, were submitted to intravenous sodium fluorescein 20% injection 1 hour previously the surgery (Table 1).

Surgery was performed under peribulbar anesthesia by a single surgeon (R.C.S). Standard Three-port Pars Plana Vitrectomy was performed using Accurus vitrectomy machine (Alcon, Fort Worth, Texas, USA) with the sclerotomies placed 4 mm (phakic eyes) or 3.5 mm (aphakic and pseudophakic eyes) posterior to the limbus. We do not use special filter to observe the contrast.

Limited core vitrectomy and removal of the vitreous close to the sclerotomy used for the insertion of the vitreous cutter were initially performed. In phakic eyes, in order to avoid direct trauma to the lens caused by the vitrectomy instruments, vitrectomy at the vitreous base from the 6 to 12 O'clock position was performed with the vitreous cutter held by the right hand, and from the 12 to 6 O'clock position was performed with the left hand.

Initially, the central vitreous was removed (core vitrectomy), followed by peeling of dense epiretinal membranes. Vitreous shaving was performed with scleral indentation by an assistant using a muscle hook. The images of all surgery steps were recorded. Finally, the retina was inspected by indirect ophthalmoscope and fluid-gas exchange completed the procedure.

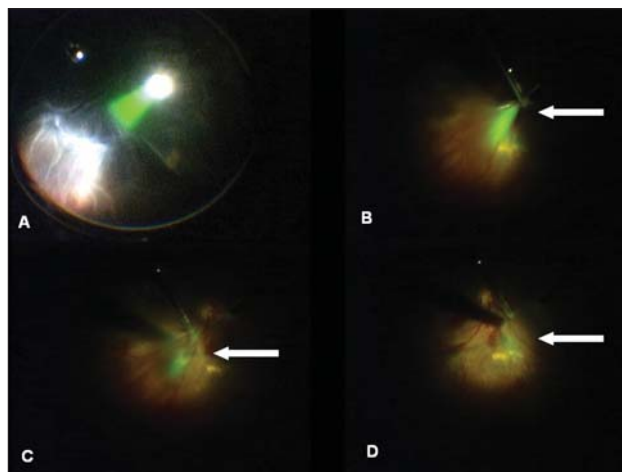


Figure 1: A - View of the mid periphery showing uncut green coloured vitreous gel stained with sodium fluorescein during vitreous surgery; B,C - Posterior hyaloid detachment procedure, it was possible to see the hyaloid and the adherent's areas; D - Fluorescein stained fibrous points (neovascularization sites) with highly intensity making it easier these areas observation

RESULTS

The study group consisted of 14 diabetic retinopathy patients. Fluorescein stained the peripheral uncut clear vitreous green, vitreous base, posterior hyaloid and improved the visibility in all instances.

At surgery time fluorescein stained the whole vitreous (Figure 1A), especially the vitreous base and the posterior hyaloid in the posterior pole. Fluorescein also stained fibrous points (neovascularization sites) with stronger intensity making it easier these areas observation (Figure 1D).

At vitreous base shaving, fluorescein helped in the visualization even of the retina vitreous junction, following the traction movements of the vitreous when the vitrectomy probe gets closer from the retina, and evidencing the limits of vitreous base with the periphery retina, reducing the incidence of iatrogenic periphery tears. During posterior hyaloid detachment procedure, it was possible to see the hyaloid and the adherent's areas (Figure 1B,C).

There was no stain of the lens or capsule (pseudophakic) during surgery, and it was possible to notice that fluorescein stained the anterior chamber, especially at pseudophakic patients, but did not affected the vitreous observation, not interfering at vitrectomy. No complications associated with the dye injection were observed in all cases.

Table 1

Results of the vitreoretinal surgery for vitreous hemorrhage and tractional retinal detachment secondary to diabetic retinopathy underwent intravenous injection of fluorescein to 20% 1 hour before the surgery
Visual acuity is best-corrected Snellen acuity

Patient	Age	Sex	Retinal status	Vitreous status	Visual acuity preop	Visual acuity postop	IOP preop	IOP postop	Complication related to fluorescein	Lens status	Follow up (months)
1	54	M	TRD	VH	CF	LP	12	62	No	Phakic	7
2	36	M	ERM	VH	HM	20/400	10	14	No	Phakic	7
3	75	F	Without TRD	VH	20/60	20/30	14	11	No	Phakic	8
4	36	M	TRD	clear	CF	CF	13	32	No	Phakic	4
5	29	F	TRD	clear	20/30	20/80	14	44	No	Pseudophakic	9
6	32	M	Without TRD	VH	HM	20/80	15	13	No	pseudophakic	6
7	38	F	Without TRD	VH	CF	20/60	15	16	No	phakic	2
8	43	M	ERM without TRD	Clear	CF	20/150	16	50	No	phakic	6
9	83	F	TRD	VH	20/100	20/80	12	18	No	Pseudophakic	6
10	27	F	TRD	clear	20/60	20/100	14	54	No	Phakic	4
11	69	M	Without TRD	VH	20/200	CF	12	10	No	Aphacik	4
12	67	F	TRD	VH	HM	CF	14	16	No	Phacik	7
13	51	M	Without TRD	VH	20/100	20/30	15	19	No	Pseudophakic	5
14	15	F	TRD	clear	20/25	20/200	13	16	No	Phakic	5

Legend: LP - light perception; CF - finger counting; HM - hand movements; TRD - Tractional retinal detachment; VH - vitreous hemorrhage; ERM - epiretinal membrane

DISCUSSION

The vitrectomy has shown an increase in its statement due to technical improvement mainly through better performance of equipment, speed cutting and increased less invasive systems (small gauge). One of the new tools of vitrectomy are substances capable of dyeing the structures intraocular facilitating visibility. Some dyes have been well studied as indocyanine green (ICG), trypan blue and more recently the sodium fluorescein⁽⁶⁻¹⁰⁾.

In order to avoid the eye toxicity and also greater manipulation during surgery (injection and aspiration of the dye), we evaluated in this study the possibility of the use of intravenous sodium fluorescein to as a dye for use in vitrectomy.

In this study we used the intravenous sodium fluorescein one hour before surgery in order to improve the visibility of areas of interest during surgery for vitrectomy in patients with diabetic retinopathy. We chose this group of patients because they show a drop of blood-retinal barrier thus facilitating the leak of f sodium

fluorescein for vitreous cavity. The patients who were included in this study had diabetic retinopathy with vitreous hemorrhage (9 patients) and tractional retinal detachment (7 patients).

We observed that the sodium fluorescein stained the vitreous body, vitreous base, posterior hyaloid and sites of neovascularization.

There was no need to use any special filter for viewing the contrast. In all patients, the color green was the sodium fluorescein observed with ease and especially when put the light pipe near the area to be examined.

To remove the posterior hyaloid with active aspiration, we observe that the sodium fluorescein provided a clear vision of the posterior hyaloid moved. We also observed that the sites of neovascularization became impregnated by sodium fluorescein. This facilitated the prevention of bleeding during the removal of posterior hyaloid.

Another feature of intravenous sodium fluorescein is that there was no impregnation of the lens or the posterior capsule in pseudophakic eyes. This fact is one more advantage compared to other dye such as trypan

blue that can lead to impregnation of the posterior capsule and subsequent worsening of visibility.

There was greater impregnating the vitreous base compared with the central vitreous, facilitating the vitreous shaving.

The intravenous sodium fluorescein may be a good tool to get vitreoretinal surgery in patients with diabetic retinopathy. Meanwhile a greater number of cases will need to assess the real benefit of this technique

RESUMO

Objetivo: Observar a eficácia da fluoresceína sódica intravenosa, na visibilidade do vítreo, durante a cirurgia de vitrectomia nos pacientes com retinopatia diabética.

Métodos: Quatorze casos consecutivos de cirurgia vitreoretiniana para hemorragia vítrea e descolamento tracional da retina secundário à retinopatia diabética, foram submetidos à injeção de fluoresceína intravenosa a 20%, 1 hora antes da cirurgia. As imagens de todos os passos das cirurgias foram gravadas. **Resultados:** A fluoresceína corou de verde o vítreo periférico, base vítrea, hialóide posterior melhorando a visibilidade para uma vitrectomia completa e mais segura. A fluoresceína também corou pontos fibrosos (sítios de neovascularização) com alta intensidade tornando mais fácil sua observação. Nenhuma complicação associada com a injeção do contraste foi observada. **Conclusão:** Fluoresceína sódica intravenosa pode ser usada de forma segura para facilitar a observação do vítreo, base vítrea, hialóide posterior e sítios de neovascularização. Esta técnica pode facilitar o procedimento de vitrectomia em pacientes com retinopatia diabética.

Descritores: Fluoresceína; Retinopatia diabética; Vitrectomia

REFERENCES

1. Hoerle S, Poestgens H, Schmidt J, Kroll P. Effect of pars plana vitrectomy for proliferative diabetic vitreoretinopathy on preexisting diabetic maculopathy. *Graefes Arch Clin Exp Ophthalmol.* 2002; 240(3):197-201.
2. Arrigg PG, Cavallerano J. The role of vitrectomy for diabetic retinopathy. *J Am Optom Assoc.* 1998; 69(11):733-40. Review.
3. Girard LJ. Fluorescein staining of formed vitreous to aid in vitrectomy. *Ophthalmic Surg.* 1984; 15(10): 874.
4. Griffiths MF. The use of fluorescein in vitrectomy. *Arch Ophthalmol.* 1987; 105(7): 889.
5. Das T, Vedantham V. Intravitreal sodium fluorescein enhances visualization of clear vitreous during vitreous surgery for macular hole: a safety and efficacy study. *Clin Experiment Ophthalmol.* 2004, 32(1): 55-7.
6. DiLoreto DA Jr, Das T, del Cerro C, Cox C, del Cerro M. Fluorescein as a marker for subretinal transplantation of human fetal neural retina. *Curr Eye Res.* 1997; 16(11): 1159-65.
7. Melo MCSC, Carneiro AF, Diniz JRP, Holanda AGS, Lima RC. Hemorragia vítrea: avaliação de 81 pacientes submetidos à vitrectomia na Fundação Altino Ventura, Recife-PE. *Rev Bras Oftalmol.* 2004; 63(9/10):451-5.
8. Mattos AB, Bonomo PPO, Freitas LL, Farah ME, Flynn Júnior H, Pereira MB. Facoemulsificação, vitrectomia via *pars plana* e implante de lente intra-ocular em olhos com retinopatia diabética proliferativa. *Arq Bras Oftalmol.* 2004; 67(3):441-9.
9. Penha FM, Maia M, Farah ME, Dib E, Príncipe AH, Devin F, et al. Morphologic and clinical effects of subretinal injection of indocyanine green and infracyanine green in rabbits. *J Ocul Pharmacol Ther.* 2008; 24(1): 52-61.
10. Rodrigues EB, Maia M, Meyer CH, Penha FM, Dib E, Farah ME. Vital dyes for chromovitrectomy. *Curr Opin Ophthalmol.* 2007; 18(3):179-87. Review.

ENDEREÇO PARA CORRESPONDÊNCIA:

Dr. Rubens Camargo Siqueira

Rua Saldanha Marinho, 2815 – Conj.42

São José do Rio Preto

CEP 15.010-100 – SP – Brasil

Tel: (17)32345858

e-mail: rubenssiqueira@terra.com.br.