

# Methodology of teaching anatomy of the ocular globe

## *Metodologia de ensino de anatomia do globo ocular*

Ana Paula Amador Pinheiro Cardoso<sup>1</sup> <https://orcid.org/0000-0002-5840-314X>

Hicaro Donato Granhen<sup>1</sup> <https://orcid.org/0000-0002-5412-1129>

Gabriel Felipe Lyra Silva<sup>1</sup> <https://orcid.org/0000-0001-5964-524X>

Rafael de Azevedo Silva<sup>1</sup> <https://orcid.org/0000-0002-1691-8778>

Franklin Coelho Nascimento<sup>2</sup> <https://orcid.org/0000-0003-4005-8250>

### ABSTRACT

**Objective:** The objective of the present study was to develop a methodology that approximates the student of the content addressed in the classes of anatomy of the eyeball. **Methods:** A circular incision was made in the orbital blade of the frontal bone of a human cadaver of a health institution and, to access the orbital structures, the area structures were dissected creating a pathway for the injection of a solution of white silicone rubber between the lens and the retina with subsequent enucleation and final dissection. **Results:** The use of the technique allowed the students of the course to construct the tactile knowledge of the organ in question and transform the theoretical knowledge into practice, recognizing muscles, functionality, blood vessels and ocular structures during the dissection procedure. **Conclusion:** The methodology used in the present study is a viable option for teaching the anatomy of the eye.

**Keywords:** Ophthalmology; Health, education; Medicine; Dissection; Cadaver; Eye; Vision, ocular; Motor Skills; Teaching; Methodology.

### RESUMO

**Objetivo:** O objetivo do presente estudo foi desenvolver uma metodologia que aproxime o discente do conteúdo abordado nas aulas de anatomia do globo ocular. **Métodos:** Foi realizada uma incisão circular na lâmina orbital do osso frontal de um cadáver humano de uma instituição em saúde e, para acessar as estruturas orbitárias, foram dissecadas as estruturas da área criando uma via para a injeção de uma solução de borracha de silicone branca entre o cristalino e a retina com posterior enucleação e dissecação final. **Resultados:** O emprego da técnica permitiu que os discentes do curso construíssem o conhecimento tátil do órgão em questão e transformando o saber teórico em prático, reconhecendo músculos, funcionalidade, vasos sanguíneos e estruturas oculares durante o procedimento de dissecação. **Conclusão:** A metodologia empregada no presente estudo é uma opção viável para o ensino da anatomia do olho.

**Descritores:** Oftalmologia; Educação Médica; Medicina; Dissecação; Cadáver; Olho; Visão Ocular; Destreza motora; Ensino; Metodologia

<sup>1</sup> Academic Course in Medicine, Centro Universitário Metropolitano da Amazônia, Belém, PA, Brazil

<sup>2</sup> Centro Universitário Metropolitano da Amazônia, Belém, PA, Brazil.

Study carried out at Centro Universitário Metropolitano da Amazônia, Belém, PA, Brazil

**The authors declare no conflicts of interests.**

Received for publication 30/01/2019 - Accepted for publication 08/05/2019.

## INTRODUCTION

The act of observing, the discovery of variations, the manual training of surgical instruments, and the comparison between normal and abnormal give anatomical dissection a teaching of unique potentialities with learning benefits (tactile sensation of the organs and real topographic anatomy as it is a human body) when compared to any other teaching methodology, be it artificial industrial models, slides in the classroom, or study in bibliographical literature.<sup>(1-3)</sup>

The visual apparatus has part of its structures contained in cavities difficult to access for study during an anatomical dissection.<sup>(4)</sup> The eye bulb is within a bone cavity - the orbit - comprising parts of the maxillary, sphenoid, ethmoid, frontal, zygomatic, lacrimal and palatine bones. It is associated with certain accessory structures, that is, muscles, fascia, eyebrow, eyelids, conjunctiva and lacrimal apparatus.<sup>(4)</sup>

In a possible corpse study, the orbital cavity can be achieved through the neurocranium, viscerocranium, or by combined accesses, which require specific devices and have risks of injuring an area at the time of the procedure, making it improper for the study.<sup>(4)</sup>

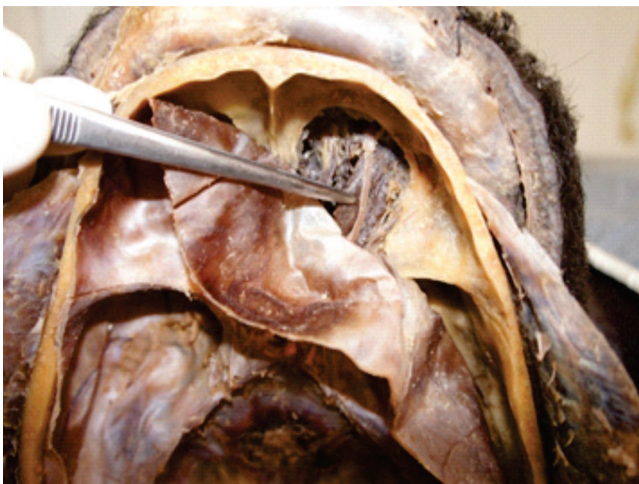
It is common for many researchers and educational institutions to neglect the dissection of the ocular globe and its structures in human cadavers or animal parts caused by the dehydration that formaldehyde (the substance used to preserve these parts) generates in the vitreous humor and aqueous humor, and therefore dehydration of the ocular globe itself, becoming extremely friable for thorough dissection.<sup>(5)</sup>

Therefore, the objective of the present study is to report the development of a technique that proposes the filling of the ocular globe, facilitating the visualization of adjacent structures and the study of Anatomy.

## METHODS

Access to the orbital structures was initiated with a circular incision with an oscillating electric saw with semicircular blade in the orbital blade of the frontal bone in a cadaver that has already undergone the craniotomy process to study encephalic structures (Figure 1).

With the aid of a magnifying glass, luminous focus and

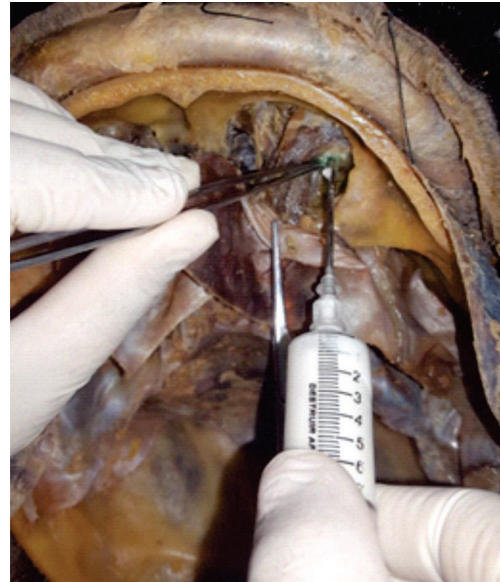

**Figure 1:** Exposure of the orbital structures after the circular incision procedure in the frontal bone.

surgical instruments such as scissors and anatomical tweezers, the area was dissected in order to expose the structures of the ocular globe and extrinsic muscles, and create access for the injection of silicone rubber.

After this step, a cut was performed between the crystalline and the retina, giving access to the area where the vitreous humor would be, cannulating it with a scalpel 20, and finally injecting a solution of white silicone rubber (Figure 2).

Six hours after injecting the content, the enucleation of the ocular globe and adjacent structures was performed for the final dissection and teaching of the anatomy in classes during the course (Figure 3 and 4).



**Figure 2:** Injection of liquid silicone rubber between the crystalline and the retina.

## RESULTS AND DISCUSSION

During the Medicine graduation, the course proposes several methodologies for teaching the anatomy, physiology and content of various specialties required for the training of efficient general practitioners in their clinical or surgical routine.

One of these areas is Ophthalmology, which studies anatomy, pathologies, and other contexts that can affect the human sight. However, this specialty is often neglected by students during graduation for reasons such as difficulty in learning anatomy, deficit of practical study, and the lack of a methodology that can bring the student closer to the subject addressed.<sup>(6)</sup>

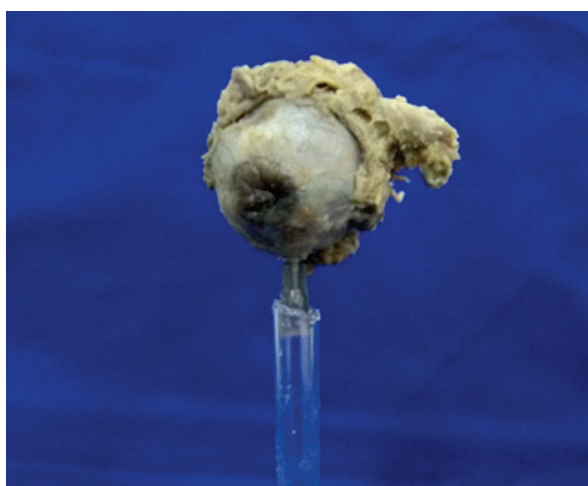
In this sense, dissection becomes an option to soften this problem. During the procedures carried out in the ocular globe, students need to diligently study the anatomy of the eye and its muscle groups in order to reduce the risk of injuring an area during dissection, learning and understanding the need of this content for medical training, and exposing the extrinsic musculature of the eye, the frontal nerve, the optic nerve, and the ophthalmic artery.

Several studies point to the need to narrow visual knowledge (lessons and readings) with the practical tactile activity of touching and feeling the texture of the organ studied, and to achieve this goal, synthetic industrial plastic simulators are built with maximum reliability. However, these devices can not generate that

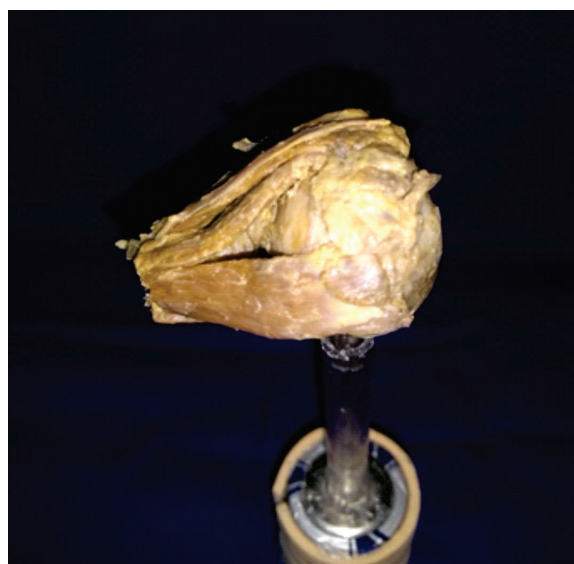
real tactile sensation of a real human organ, bringing the need of practical dissection classes with the human corpse.<sup>(4,7)</sup>

Upon understanding the importance of these practical classes, some studies show that medical schools neglect the ocular area during the preparation of a human corpse for study material of students and professors, preferring to expose areas such as mediastinum, abdominal cavity, limb muscle groups, and encephalic region.<sup>(6-10)</sup> The eyes, if not properly prepared concomitantly with these other areas, end up losing its vitreous humor content, disturbing the later study of this organ.<sup>(10)</sup>

Thus, the procedure performed by the present study is beneficial according to the authors when demonstrating the anatomy of the eye from a preparation and injection of a solution of white silicone rubber, expanding the ocular globe in place of the vitreous humor, besides contributing to the study of the students about the anatomy of the area, and being a methodology with low cost when compared to the purchase of industrial parts of a human body (Figure 3 and 4).



**Figure 3:** Frontal view of the enucleated and dissected ocular globe.



**Figure 4:** Lateral view of the enucleated and dissected ocular globe evidencing the muscles.

## CONCLUSION

The methodology employed for the dissection of the cadaver's ocular globe is, in the view of the authors who performed the procedure, an efficient alternative for teaching the anatomy of the eye, being a low cost option making it possible to study Anatomy with the participation of the students. In order to do so, other educational institutions having a human cadaver for studies should be encouraged to use techniques to prepare the ocular globe for more practical eye anatomy classes during medical graduation.

## REFERENCES

1. Marques P, Cristina S. A dissecação como ferramenta pedagógica no ensino da Anatomia em Portugal. *Interface (Botucatu)*. 2014;18(48):165-76.
2. Lobo L. Educação médica nos tempos modernos. *Rev Bras Educ Med*. 2015;39(2):328-32.
3. Belarmino L, Martins F, Franco M. Aspirações Médicas: Análise dos Alunos do Internato das Instituições de Ensino Superior do Estado do Pará. *Rev Bras Educ Méd*. 2016;40(4):685-93.
4. Sampedro A, Barbón J. El globo ocular y anexos en la "Anatomía completa del hombre" de Martín Martínez (s. XVIII). *Arch Soc Esp Oftalmol*. 2010; 85(8):282-4.
5. Castro M. El aula de Anatomía y el laboratorio de disección: Una aproximación etnográfica al estudio de la anatomía humana. *Cuad Antropol Soc*. 2016;43:129-42.
6. Sousa I, Silva C, Caldas C. Especialidade médica: escolhas e influências. *Rev Bras Educ Med*. 2014;38(1):79-86.
7. Silva R, Luz M, Granhen H, Mendonça E, Luz M, Nascimento F. Modelo experimental para estudo de anatomia humana em cadáveres. *PRMJ*. 2018;1(2): e13
8. Damasceno E, Damasceno P, Costa A. Ensino de oftalmologia na graduação médica: Estudo comparativo de aprendizado na oftalmoscopia direta com oftalmoscópio convencional e de campo amplo (Panoptíc). *Rev Bras Oftalmol*. 2009; 68(4):231-6.
9. Kara A, Passos L, Kara F, Kara N. Ensino extracurricular em Oftalmologia: grupos de estudos / ligas de alunos de graduação. *Rev Bras Educ Med*. 2007 ;31(2):166-72.
10. Androwiki J, Scravoni I, Ricci L, Fagundes D, Ferraz C. Evaluation of a simulation tool in ophthalmology: application in teaching funduscopy. *Arq Bras Oftalmol*. 2015; 78(1):36-9.

### **Corresponding author:**

Rafael de Azevedo Silva  
Av. Visconde de Souza Franco, 72 - Reduto - Belém - Brazil  
E-mail: azevedorafaelsilva@gmail.com