

Clinical profile and ophthalmologic manifestations of Herpes Zoster Ophthalmicus

Perfil clínico e achados oftalmológicos no Herpes Zoster Oftálmico

Fabio Mendonca Xavier Andrade¹ <https://orcid.org/0000-0002-5184-3388>

Fernanda Machado Bezerra¹ <https://orcid.org/0000-0002-4655-2594>

Myrna Serapiao Dos Santos¹ <https://orcid.org/0000-0002-7733-694X>

Maria Emilia Xavier dos Santos Araujo¹ <https://orcid.org/0000-0003-1775-2893>

ABSTRACT

Objective: *Herpes Zoster Ophthalmicus (HZO) is caused by varicella-zoster virus (VZV) and commonly affects elderly or immunocompromised patients. It has the potential to generate severe complications such as corneal ulcers, uveitis, retinal necrosis and post herpetic neuralgia. This study aimed to evaluate patients at the acute onset of the disease and describe their clinical profile and ophthalmologic findings. Methods:* A cross-sectional study was performed from March 2014 to October 2015. All consecutive patients with the diagnosis of acute HZO (at a vesicle, pustule or crust stage) were enrolled and submitted to an ophthalmologic exam that included ectoscopy, best corrected visual acuity, corneal sensitivity test, slit-lamp examination, Goldmann applanation tonometry and funduscopic examination. **Results:** Nineteen patients were included. The mean age was 71 years old, ranging from 52 to 88. Ten patients had high blood pressure (52.6%) and nine (47.3%) had diabetes. Visual acuity lowered in comparison to the fellow eye in eleven patients (57%), ranging from one to six lines of vision, due mostly to epithelial keratitis and ocular discharge. Intraocular pressure (IOP) did not varied in most cases compared to the fellow eye. Hutchinson's sign (HS) was present in seven (36%) patients. The correlation between HS and anterior chamber reaction as well as decreased corneal sensitivity was statistically significant with Fisher's test of 0.009 and 0.029 respectively ($p < 0.05$). **Conclusion:** The clinical profile of our patients was elderly patients with a higher rate of diabetes. Correlation between Hutchinson's sign and anterior chamber reaction as well as decrease in corneal sensitivity was significant. High intraocular pressure or posterior segment complications were not found in any cases.

Keywords: *Herpes Zoster Ophthalmicus; Clinical profile; Keratitis; Uveitis*

RESUMO

Objetivos: Herpes Zoster Oftálmico (HZO) é uma doença causada pelo vírus varicella-zoster que comumente afeta idosos ou doentes imunossuprimidos, com potencial para gerar graves comorbidades oculares, incluindo úlceras corneanas, uveíte, necrose retiniana e neuralgia pós-herpética. O objetivo deste estudo foi avaliar estes pacientes na forma aguda da doença e descrever seu perfil clínico e achados oftalmológicos. **Métodos:** Um estudo transversal foi realizado entre março de 2014 e outubro de 2015. Todos os pacientes consecutivos com o diagnóstico de HZO (na forma vesicular, pustulosa ou crostosa) foram incluídos e submetidos ao exame oftalmológico que incluiu ectoscopia, melhor acuidade visual corrigida, teste de sensibilidade corneana, biomicroscopia, tonometria de aplanção de Goldmann e fundoscopia. **Resultados:** Dezenove pacientes foram incluídos. A idade média foi de 71 anos. Dez (52,6%) pacientes relataram hipertensão arterial sistêmica e nove (47,3%) diabetes mellitus. A acuidade visual do olho acometido se encontrou abaixo do olho contra lateral em 57% dos casos, variando entre uma a seis linhas de visão. A pressão intraocular não variou na maioria dos casos em comparação com o olho contralateral. O sinal de Hutchinson estava presente em sete (36%) pacientes. A correlação entre este sinal e a presença tanto de reação de câmara anterior quanto de hipoestesia corneana foi positiva estatisticamente, com teste exato de Fisher de 0,009 e 0,029 respectivamente ($p < 0,05$). **Conclusão:** Idosos com uma prevalência elevada de diabetes mellitus representaram o perfil clínico dos pacientes deste estudo. A correlação entre o sinal de Hutchinson e reação de câmara anterior, bem como daquele com hipoestesia corneana foi estatisticamente significativa. Não foi identificado nenhum caso de hipertensão ocular ou complicações de segmento posterior.

Descritores: Herpes Zoster Oftálmico; Perfil clínico; Ceratite; Uveíte

¹ Hospital do Servidor Público Estadual "Francisco Morato de Oliveira", São Paulo, SP, Brasil.

Research performed at: Hospital do Servidor Público Estadual "Francisco Morato de Oliveira", São Paulo, SP, Brasil.

The authors declare no conflicts of interests.

Received for publication 23/10/2018 - Accepted for publication 08/03/2019.

INTRODUCTION

Herpes Zoster Ophthalmicus (HZO) is the clinical manifestation of varicella-zoster virus (VZV) reactivation in the ophthalmic nerve, the first branch of the trigeminal cranial nerve. It typically begins with flu-like symptoms such as fever, headaches and malaise and progresses to a skin rash and vesicular eruption in the area corresponding to the ophthalmic nerve dermatome. It accounts for 10 to 20% of all Herpes Zoster's (HZ) cases and can lead to important eye related morbidity, especially in the case of post-herpetic neuralgia (PHN).⁽¹⁻⁷⁾

The ocular manifestations of HZO are diverse and practically every portion of the globe can be affected. The eyelids present the same stages as the skin in other dermatomes (erythema, macules, papules, vesicles and crust phase). Ocular surface possible findings include conjunctivitis, episcleritis and scleritis. Corneal manifestations can be at epithelium, stroma or endothelium level, possibly leading to neovascularization and severe scarring. Anterior chamber reaction can be seen in the acute form and can lead to iris atrophy at a late phase. Retinal necrosis and optic neuritis are more rare but possible complications of the posterior segment.^(2,4)

The aim of this study was to evaluate the clinical profile and ophthalmologic manifestations of Herpes Zoster Ophthalmicus at the acute onset of the disease.

METHODS

A cross-sectional study was performed from March 2014 to October 2015 at the Hospital do Servidor Público Estadual "Francisco Morato de Oliveira", in São Paulo. All consecutive patients with the diagnosis of acute HZO (recent skin rash at a vesicle, pustule or crust stage) examined at the Ophthalmology Emergency Room or referred to the Ophthalmology department from other specialities were enrolled.

The presence of systemic comorbidities, the time to seek medical assistance after the rash outbreak, ocular symptoms, previous ocular medical history and the drug in use for the treatment of HZO were investigated.

The ophthalmological exam included: ectoscopy, best corrected visual acuity measured with a Snellen chart, corneal sensitivity test, slit-lamp examination, Goldmann applanation tonometry and funduscopic examination. Hutchinson's sign (HS), HZ lesions at the tip, side or root of the nose, was searched in all subjects.

All patients signed a written informed consent and this protocol was approved by the Ethics Committee of Hospital do Servidor Público Estadual "Francisco Morato de Oliveira, in São Paulo (approval number: 43189714.8.0000.5463).

Statistical analyses were performed using SPSS Statistics (IBM Corp. Version 20.0. Armonk, NY)

RESULTS

Nineteen patients were included, five males (26.3%) and thirteen females (73.7%). Mean age was 71 years, ranging from 52 to 88. Ten cases (52.6%) had high blood pressure and nine (47.3%) had diabetes. The right side of the face was affected in eight patients (42.1%) and the left in eleven (57.9%). Patients demographics and symptoms history are demonstrated in table 1.

Table 1
Patients demographics and symptoms history of patients with acute HZO

Case	Age (years)	Gender	Affected side	Cutaneous symptoms (days)	Ocular symptoms
1	75	Female	Right	4	-
2	61	Female	Left	7	+
3	65	Female	Left	5	+
4	62	Male	Right	6	+
5	72	Female	Left	6	-
6	61	Female	Right	4	-
7	52	Male	Left	15	-
8	78	Male	Right	3	+
9	74	Female	Right	10	+
10	84	Female	Left	4	+
11	84	Female	Right	19	-
12	88	Female	Left	6	+
13	84	Female	Left	7	+
14	61	Female	Right	3	+
15	75	Female	Left	4	+
16	83	Male	Right	7	-
17	62	Male	Left	6	-
18	70	Female	Left	8	+
19	71	Female	Left	8	+

The mean time between skin rash manifestation and the search for medical assistance was seven days, ranging from three to nineteen days.

Twelve patients (63.2%) had ocular symptoms and six (50%) of them reported the beginning of these symptoms at the same time of the skin rash outbreak. Three patients (25%) reported that their ocular symptoms had begun before the skin rash and three (25%) after.

The most often described ocular symptom was pain (8 patients – 42.1%), followed by tearing (7 patients – 36.8%), foreign body sensation (4 patients – 21.1%), photophobia (2 patients – 10.5%), itching (2 patients – 10.5%) and visual blurring (2 patients – 10.5%), as seen in figure 1.

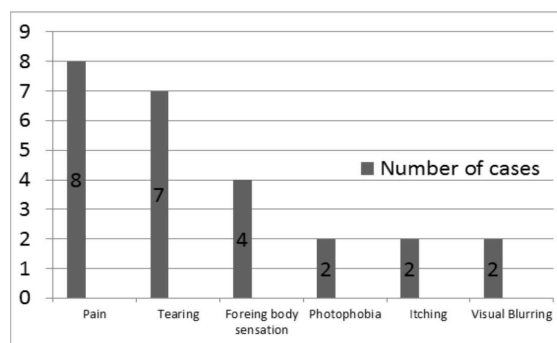


Figure 1: Ocular symptoms referred by patients with acute HZO. Ocular pain and tearing were the most frequent.

Past ocular history showed that four patients (21.1%) had previous cataract surgery, two (10.5%) high myopia, one (5.3%) age-related macular degeneration and one (5.3%) use of contact lenses.

Seventeen patients (89.4%) were being treated with acyclovir and two (10.6%) with valacyclovir.

The majority of the individuals had eyelid skin lesions (16 patients – 84.2%). Seven (36.8%) presented swelling, five (26.3%) showed skin hyperemia, five (26.3%) had active vesicles and nine (47.4%) exhibited crusts. Most of the presentations coexisted among patients as shown in figure 2. An early stage with erythema, macules, papules and vesicles can be seen in figure 3.

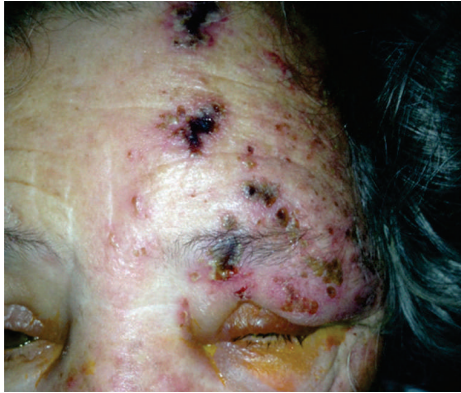

Figure 2: Acute onset of HZO in the left eye. Erythema, macules, papules, vesicles and crusts are shown. Eyelid swelling is pronounced.

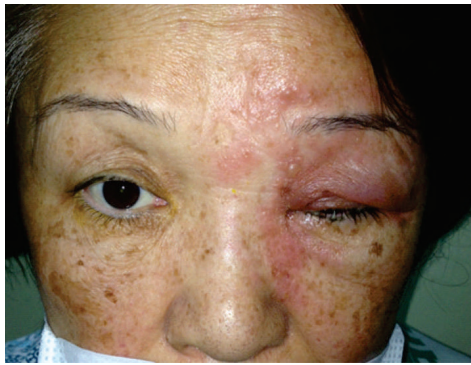


Figure 3: Acute onset of HZO in the left eye at an earlier stage, without crust formation. Eyelid swelling and ocular discharge can be seen.

Hutchinson's sign was present in seven patients (36.8%) and only one of them did not report ocular symptoms.

Best corrected visual acuity (BCVA) in the affected eye was lower than the fellow eye in eleven (57%) patients, ranging from one to six lines of vision. Two cases had lower vision in the fellow eye due to macular degeneration as seen in table 2. Maximum difference between intra ocular pressure (IOP) of both eyes was 4 mmHg (higher or lower) with most cases varying only 2 mmHg (15 patients – 78%), even in the presence of anterior chamber reaction.

Seven patients (36.8%) had decreased corneal sensitivity. Five of them showed Hutchinson's sign. The Fisher's exact test for this correlation was 0.029 ($p < 0.05$).

Slit-lamp examination revealed conjunctival hyperemia in six (31.6%) cases, epithelial keratitis in nine (47.4%) and anterior chamber reaction in four (21.1%). All patients with anterior chamber reaction had Hutchinson's sign present. The Fisher's exact test for this correlation was 0.009 ($p < 0.05$). Clinical examination findings are demonstrated in table 2.

None of the patients had posterior segment findings compatible with acute HZO.

Table 2
Clinical examination findings of patients with acute HZO

Case	Hutchinson's sign	Corneal sensitivity	Vision loss*	Epithelial Keratitis	Anterior chamber reaction	Ocular discharge
1	-	Normal	3	-	-	-
2	+	Decreased	5	+	+	+
3	-	Normal	0	+	-	+
4	+	Decreased	6	-	+	-
5	-	Normal	3	+	-	+
6	+	Normal	-	-	-	-
7	-	Normal	0	-	-	-
8	+	Decreased	0	+	+	+
9	+	Normal	1	-	-	-
10	-	Normal	1	-	-	-
11	-	Normal	0	-	-	-
12	-	Decreased	-	+	-	+
13	+	Decreased	6	+	-	+
14	-	Decreased	0	+	-	+
15	-	Normal	1	-	-	-
16	-	Normal	0	-	-	-
17	-	Normal	1	+	-	+
18	-	Normal	0	-	-	-
19	+	Decreased	4	-	+	-

*Number of lines below the fellow eye measured in the visual acuity chart. Number 6 and 12 presented macular degeneration on the fellow eye that made comparison impossible.

DISCUSSION

Few studies investigated the epidemiology or clinical manifestations of Herpes Zoster Ophthalmicus. Szeto et al.⁽⁸⁾ and Borkar et al.⁽⁹⁾ found no differences between gender in their sample. Gupta et al.⁽¹⁰⁾ found a higher incidence in male subjects. However, their sample was formed only from young adults (21 – 39 years), divided from HIV status (positive or negative). One study found 96% of male predominance among elderly immune competent HZO patients.⁽¹¹⁾ In our study we found a 73.7% incidence of female patients.

The Hospital do Servidor Público Estadual “Francisco Morato de Oliveira”, in São Paulo, is a hospital that receives only public employers of the State of São Paulo. Internal data shows that 72% of our patients (most of them active or retired teachers from public State schools) are female. Which indicates that HZO followed a normal distribution between male and female subjects in our sample.

High blood pressure was found in 52.6% of patients. This prevalence is shown in other studies of general comorbidities among the elderly. Diabetes in the other hand has shown to be two to three times more prevalent among our sample than in the general elderly population. This may indicate that diabetes could play a role in the reactivation of varicella zoster virus as the disease is known to generate immune dysfunction.⁽¹²⁻¹⁵⁾

Most patients had taken more than 3 days to search for medical assistance after the beginning of symptoms. This impacts directly in the efficacy of treatment in preventing post-herpetic neuralgia, as shown in previous studies. Given the serious reduction that PHN causes on a patient's quality of life, this data

shows that HZO should be more discussed and the population should be able to recognize the disease and seek medical assistance in between the first 72h of skin rash outbreak.⁽¹⁶⁻¹⁸⁾

The visual impairment found in eleven patients ranged from one to six lines of vision compared to the fellow eye and could be explained from the alterations in the ocular surface such as keratitis, tearing or ocular discharge and also anterior chamber reaction.

Epithelial keratitis was the most frequent ocular manifestation detected in our study, followed by conjunctival hyperemia. Other authors have found conjunctivitis as the most frequent form of ocular involvement.^{(8, 11, 19).}

In our study, the intraocular pressure in the affected eye did not raise more than 4mmHg compared with the fellow eye, even in those cases with anterior chamber reaction. Takase et al.⁽²⁰⁾ examined 20 patients with anterior chamber reaction due to VZV and found an average IOP of 35 mmHg, although most of them were cases without dermal signs (aqueous PCR analysis) and did not specify the number of hypertensive cases, only de mean IOP among all the sample.

Hutchinson's sign represents the involvement of the nasociliary nerve (a branch of the ophthalmic nerve) with HZO. Besides the nasal skin area, it also innervates the ocular surface, sclera and uvea. Previous studies showed a 71% to 86% rate of ocular complications (mainly intraocular inflammation and decreased corneal sensitivity) in patients with HS.^(21, 22) In our study, 71.4% of patients with HS had ocular complications, including all patients with anterior chamber reaction. However, not all cases with decreased corneal sensitivity or keratitis showed HS, which reinforces that all individuals with HZO must be examined by an ophthalmologist to search for these complications.

Antiviral treatment in the first 72 hours of symptoms is proven to reduce pain, corneal involvement, PHN incidence and shorten the time of resolution of skin lesions.^(18, 19, 23-25) However, most medical professionals initiate treatment up until 10 days of symptoms based on the drug's low toxicity profile and the severity of possible complications such as PNH and visual impairment.⁽²⁶⁾

Only two patients were treated with valacyclovir. Previous studies compared acyclovir and valacyclovir for HZ treatment and concluded that both drugs have the same efficacy and tolerability.⁽²⁷⁻²⁹⁾ The advantage of valacyclovir is the easiest dosage and the drawback, the elevated cost.⁽³⁰⁾

Examples of posterior segment involvement of HZO are acute retinal necrosis (ARN), progressive outer retinal necrosis (PORN) and optic neuritis. These conditions are more commonly seen in immunocompromised patients but can also occur in immunocompetent individuals.^(5, 31) In our sample, none of the patients presented posterior segment alterations compatible with acute HZO.

CONCLUSION

The profile of our patients with HZO was elderly patients over 65 years of age with a higher rate of diabetes. Ocular symptoms were frequent in these patients and usually emerged at the onset of the skin rash. Ocular hypertension was not present even in the cases with anterior uveitis. The Hutchinson sign was related statistically to active anterior chamber reaction and decreased corneal sensitivity but should not be used as the only

reason to refer these patients to an ophthalmologic examination as ocular complications were also found on cases where this sign was not present.

REFERENCES

1. Catron T, Hern HG. Herpes zoster ophthalmicus. *West J Emerg Med.* 2008;9(3):174-6.
2. Liesegang TJ. Herpes zoster ophthalmicus natural history, risk factors, clinical presentation, and morbidity. *Ophthalmology.* 2008;115(2 Suppl):S3-12.
3. Marsh RJ. Herpes zoster ophthalmicus. *J R Soc Med.* 1997 Dec;90(12):670-4.
4. Opstelten W, Zaai MJ. Managing ophthalmic herpes zoster in primary care. *BMJ.* 2005;331(7509):147-51.
5. Shaikh S, Ta CN. Evaluation and management of herpes zoster ophthalmicus. *Am Fam Physician.* 2002;66(9):1723-30.
6. Gnann JW Jr, Whitley RJ. Clinical practice. Herpes zoster. *N Engl J Med.* 2002;347(5):340-6.
7. Hope-Simpson RE. Postherpetic neuralgia. *J R Coll Gen Pract.* 1975;25(157):571-5.
8. Szeto SK, Chan TC, Wong RL, Ng AL, Li EY, Jhanji V. Prevalence of Ocular Manifestations and Visual Outcomes in Patients With Herpes Zoster Ophthalmicus. *Cornea.* 2017;36(3):338-42.
9. Borkar DS, Tham VM, Esterberg E, Ray KJ, Vinoya AC, Parker JV, et al. Incidence of herpes zoster ophthalmicus: results from the Pacific Ocular Inflammation Study. *Ophthalmology.* 2013;120(3):451-6.
10. Gupta N, Sachdev R, Sinha R, Titiyal JS, Tandon R. Herpes zoster ophthalmicus: disease spectrum in young adults. *Middle East Afr J Ophthalmol.* 2011;18(2):178-82.
11. Tran KD, Falcone MM, Choi DS, Goldhardt R, Karp CL, Davis JL, et al. Epidemiology of Herpes Zoster Ophthalmicus: recurrence and Chronicity. *Ophthalmology.* 2016;123(7):1469-75.
12. Lionakis N, Mendrinou D, Sanidas E, Favatas G, Georgopoulou M. Hypertension in the elderly. *World J Cardiol.* 2012;4(5):135-47.
13. Iser BS, SR. Schmidt, MI. Prevalência de diabetes autorreferido no Brasil: resultados da Pesquisa Nacional de Saúde 2013. *Rev Epidemiol Serv Saúde.* 2015;24(2):305-14.
14. Mendes Tde A, Goldbaum M, Segri NJ, Barros MB, Cesar CL, Carandina L, et al. *Cad Saude Publica.* 2011;27(6):1233-43.
15. Geerlings SE, Hoepelman AI. Immune dysfunction in patients with diabetes mellitus (DM). *FEMS Immunol Med Microbiol.* 1999;26(3-4):259-65.
16. Fashner J, Bell AL. Herpes zoster and postherpetic neuralgia: prevention and management. *Am Fam Physician.* 2011;83(12):1432-7.
17. Tyring SK, Beutner KR, Tucker BA, Anderson WC, Crooks RJ. Antiviral therapy for herpes zoster: randomized, controlled clinical trial of valacyclovir and famciclovir therapy in immunocompetent patients 50 years and older. *Arch Fam Med.* 2000;9(9):863-9.
18. Wood MJ, Kay R, Dworkin RH, Soong SJ, Whitley RJ. Oral acyclovir therapy accelerates pain resolution in patients with herpes zoster: a meta-analysis of placebo-controlled trials. *Clin Infect Dis.* 1996;22(2):341-7.
19. Severson EA, Baratz KH, Hodge DO, Burke JP. Herpes zoster ophthalmicus in olmsted county, Minnesota: have systemic antivirals made a difference? *Arch Ophthalmol.* 2003;121(3):386-90.
20. Takase H, Kubono R, Terada Y, Imai A, Fukuda S, Tomita M, et al. Comparison of the ocular characteristics of anterior uveitis caused by herpes simplex virus, varicella-zoster virus, and cytomegalovirus. *Jpn J Ophthalmol.* 2014;58(6):473-82.
21. Butsch F, Greger D, Butsch C, von Stebut E. Prognostic value of Hutchinson's sign for ocular involvement in herpes zoster ophthalmicus. *J Dtsch Dermatol Ges.* 2017;15(5):563-564.
22. Zaai MJ, Volker-Dieben HJ, D'Amato J. Prognostic value of Hutchinson's sign in acute herpes zoster ophthalmicus. Graefe's archive for clinical and experimental ophthalmology = Albrecht Von Graefes Arch Klin Exp Ophthalmol. 2003;241(3):187-91.

23. Harding SP, Porter SM. Oral acyclovir in herpes zoster ophthalmicus. *Curr Eye Res.* 1991;10(Suppl):177-82.
24. Hoang-Xuan T, Büchi ER, Herbort CP, Denis J, Frot P, Thénault S, et al. Oral acyclovir for herpes zoster ophthalmicus. *Ophthalmology.* 1992;99(7):1062-70.
25. Herbort CP, Buechi ER, Piguet B, Zografos L, Fitting P. High-dose oral acyclovir in acute herpes zoster ophthalmicus: the end of the corticosteroid era. *Curr Eye Res.* 1991;10(Suppl):171-5.
26. Johnson JL, Amzat R, Martin N. Herpes Zoster Ophthalmicus. *Prim Care.* 2015;42(3):285-303.
27. Beutner KR, Friedman DJ, Forszpaniak C, Andersen PL, Wood MJ. Valaciclovir compared with acyclovir for improved therapy for herpes zoster in immunocompetent adults. *Antimicrob Agents Chemother.* 1995;39(7):1546-53.
28. Ormrod D, Goa K. Valaciclovir: a review of its use in the management of herpes zoster. *Drugs.* 2000;59(6):1317-40.
29. Colin J, Prisant O, Cochener B, Lescale O, Rolland B, Hoang-Xuan T. Comparison of the efficacy and safety of valaciclovir and acyclovir for the treatment of herpes zoster ophthalmicus. *Ophthalmology.* 2000;107(8):1507-11.
30. Grant DM, Mauskopf JA, Bell L, Austin R. Comparison of valaciclovir and acyclovir for the treatment of herpes zoster in immunocompetent patients over 50 years of age: a cost-consequence model. *Pharmacotherapy.* 1997;17(2):333-41.
31. Zajdenweber ME, Muccioli C. [Treatment of acute retinal necrosis: systematic review]. *Arq Bras Oftalmol.* 2005;68(4):463-9

Corresponding Author:

Fábio Mendonça Xavier Andrade
Borges Lagoa St, 1755
Phone: +55 (11) 45738000
E-mail: fabio16.xavier@gmail.com