

The periosteal graft and flap use in Ophthalmology

O uso de enxerto e retalho de periósteo em Oftalmologia

Felipe Baccega¹ <https://orcid.org/0000-0003-2532-9921>

Suzana Matayoshi² <https://orcid.org/0000-0003-0630-4091>

Maria Antonieta da Anunciação Ginguerra Nascimento³ <https://orcid.org/0000-0001-5886-0212>

ABSTRACT

Purpose: The authors reviewed the periosteum use in ophthalmic surgery and its results. **Methods:** A comprehensive review of the literature using Google Scholar, PubMed and SciELO databases with all articles about the periosteum use in Ophthalmology published from 1977 to 2018. **Results:** A total of 21 studies followed the review's purpose: 9 case reports, 9 case series, 1 retrospective cohort and 2 prospective cohorts. 206 patients were submitted to the procedures with the periosteum use in the two main forms: graft and flap. The principal reasons for periosteal use were: orbital implant covering and eyelid reconstruction. Surgical outcomes were very satisfactory with low complication rates of 10.67% and minimal necessity of new surgical intervention of 2.42%. **Conclusion:** The periosteum use in Ophthalmology is a promising technique with good results so far and should always be a therapeutic option for the ophthalmologist. However, based on available data in the literature, more studies with statistical power for knowledge sedimentation in this subject are recommended.

Keywords: Free tissue flaps; Periosteum; Ophthalmologic surgical procedures

RESUMO

Objetivo: Os autores revisaram o uso de periósteo em cirurgias oftalmológicas e seus resultados. **Métodos:** Uma revisão de literatura usando os bancos de dados do Google Scholar, PubMed e SciELO com todos os artigos sobre o uso de periósteo em Oftalmologia publicados de 1977 até 2018. **Resultados:** Um total de 21 estudos cumpriram o objetivo do estudo: 9 relatos de caso, 9 séries de casos, 1 coorte retrospectiva e 2 coortes prospectivas. 206 pacientes foram submetidos aos procedimentos cirúrgicos com uso de periósteo nas duas formas principais: enxerto e retalho. Os principais motivos para uso do periósteo foram: recobrimento de implante orbitário e reconstrução palpebral. Resultados cirúrgicos foram satisfatórios com baixas taxas de complicação de 10.67% e mínima necessidade de nova intervenção cirúrgica de 2.42%. **Conclusão:** O uso de periósteo em Oftalmologia é uma técnica promissora com bons resultados até o momento e deve sempre ser uma opção terapêutica para o Oftalmologista. Todavia, mais estudos com poder estatístico para sedimentação do conhecimento sobre o tema são recomendados.

Descritores: Retalhos de tecido biológico; Periósteo; Procedimentos cirúrgicos oftalmológicos

1. School of Medicine, Universidade de São Paulo, São Paulo, SP, Brazil.

2. Ophthalmology Discipline, School of Medicine, Universidade de São Paulo, São Paulo, SP, Brazil.

3. Service of Ocular Plastic Surgery, School of Medicine, Universidade de São Paulo, São Paulo, SP, Brazil.

The authors declare no conflicts of interests.

Received for publication 21/08/2018 - Accepted for publication 28/11/2018.

INTRODUCTION

The use of periosteum for craniofacial reconstruction is a technique already sedimented.⁽¹⁾ Its use in Ophthalmology appears in reports of 1977 when Rao et al. used periosteal graft for scleral reinforcement in scleromalacia.⁽²⁾ In addition, the periosteum has been currently used in the art for other functions as: reconstruction of the orbital cavity, palpebral reconstruction, covering of orbital implants, of scleral buckle, and even of corneal ulcers.

Literature describes its use in in two main ways: it can be used as a graft when removed from its donor site without a vascular pedicle, or as a flap when it maintains its vascularization. In the first case we make use of its capacity to support, structure and cover the surface, and in the second case there is also the advantage of providing blood supply to stimulate the integration of tissues and fight infections.^(1,3) In addition, it may be used alone or in combination with other tissues such as myoperiosteal and mucoperiosteal grafts.^(3,4)

The periosteum donor area varies depending on criteria such as the experience of the surgical team, the location of the surgical site, the amount of periosteum required, and the availability of adequate surgical material. The main donor areas for the ophthalmologic procedures published are anterior tibial, palate, mastoid, eye socket, pericranium, and nasal bone.

In all descriptions published, autologous periosteum is used with the inherent benefits such as less time for vascularization and integration, and less inflammatory response when compared to heterologous tissues, besides not causing sensitization of the host.^(3,5)

ANATOMY

The periosteum is a fibrovascular tissue covering the outer bone surface of most human bones, except for joint surfaces, tendon insertions, and sesamoid bones.

It is attached to the bone tissue by collagen fibers, and can reach 2-3mm thick in the diaphyses of long bones where it is more easily detachable. In the bone metaphysis and epiphysis the periosteum is thinner and more adhered to the underlying bone tissue.

From the mechanical point of view, the periosteum in children is stronger and thicker, and with age it becomes thinner and less resistant or elastic.⁽⁶⁾

HISTOLOGY

From the histological point of view, it is a subaponeurotic loose connective tissue well vascularized, in close contact with the bone cortex, and comprises multipotent cells of the mesoderm with the capacity of differentiation in several types of connective tissue depending on its microenvironment, such as bone and cartilage tissue.^(1,7)

It can be divided into 2 layers:

- Cambium: thin inner cell layer with the presence of osteoblasts and osteoprogenitor cells with cellular proliferation and differentiation capacity.
- External layer with abundant presence of collagen fibers and reticular fibers to bring elasticity and resistance to the tissue.⁽⁶⁾

SURGICAL TECHNIQUE

The surgical technique for collecting periosteum generally comprises the following steps: dissection by planes until periosteal surface exposure, delimitation of periosteal extraction area with scalpel or with thin tip monopolar electrocautery to the bone plane, periosteal detachment of the bone surface with a periosteal elevator, mobilization and collection of the periosteum isolated, local hemostasis, closure of the surgical site by planes.^(3,5,8-10)

During the periosteum delimitation and detachment step, the reduced thickness and friability of the tissue requires the step to be carried out carefully, and the use of a magnifying glass is recommended.^(8,9)

The periosteal tissue collected must be maintained in saline solution to avoid drying until its use, and its fixation is done with sutures.

For the preparation of periosteal flaps, it is necessary to know the vascularization of the specific region of the surgical site approached in order to preserve the vascular pedicle.

For access to the frontal periosteum, the main access routes used are the upper eyelid via the palpebral sulcus and coronal incision. The dissection plane should be subgaleal, and the smallest area of galeal dissection should be performed in order to preserve the perforating vessels.⁽¹⁾ Other access routes to the frontal region are through a medial and paramedial vertical incision behind the capillary implantation line when the endoscopic technique is used.⁽¹⁰⁾

The parietal periosteum can be accessed through a median incision in the 4-cm parietal region. Access is safer than the other typical access routes as it approaches terminal irrigation and vascularization routes with fewer collaterals, besides providing a broad area for collection of periosteum.⁽⁵⁾ (Figures 1 and 2)

The main complications presented by the donor region are local pain, swelling, scarring that are sometimes visible, chance of local sensitivity alteration by nerve injury, and potential risk of local infection.⁽⁵⁾

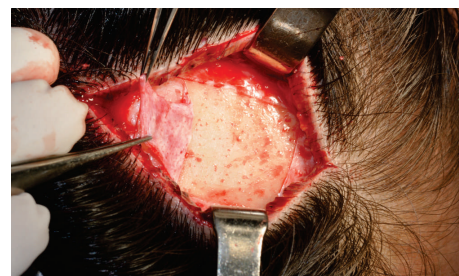

Figure 1: Incision in the midline of the parietal region

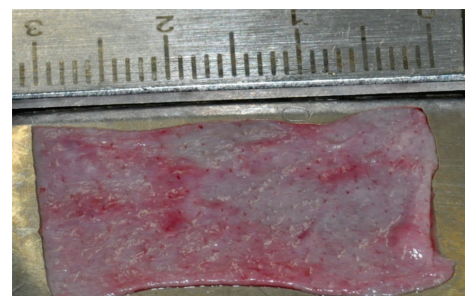


Figure 2: Periosteum graft

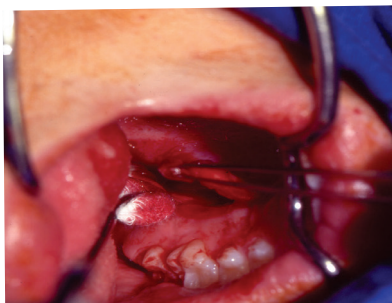

Figure 3: Collection of mucoperiosteal graft of hard palate

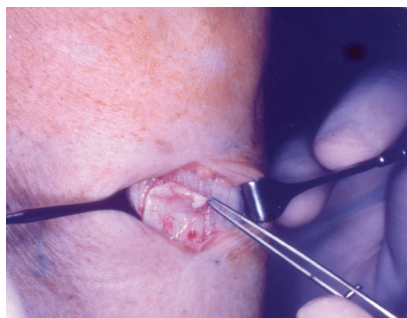


Figure 4: Pretribal periosteum

METHODS

A research on the use of periosteum in Ophthalmology was carried out using the Google Scholar, PubMed and SciELO databases, with articles published from 1977 to 2018. The keywords used for the research were periosteum, pericranium, periosteal graft, periosteal flap, eye, ophthalmology, orbit, socket.

Selection of studies

The review included case reports, case series with up to 21 individuals, retrospective cohorts with up to 5 individuals, and prospective cohorts with 58 individuals.

Data extraction

Data collected included the use of periosteum alone, use of composite periosteum, use of graft, use of flap, periosteal removal site, periosteal destination, success in the technique described, complications presented.

RESULTS

We found 21 studies following the selection criteria: 9 studies were case reports, 9 case series, 1 retrospective cohort, 2 prospective cohort (Table 1).

The studies available evaluated the total of 206 patients submitted to the ophthalmologic use of periosteum.

Table 1
Studies available in the literature

Author	Year	Paper
Rao et al.	1977	Periosteal graft in scleromalacia
Caroll et al.	1979	Bone formation in a periosteal graft
Wolfe SA	1979	Correction of a persistent lower eyelid deformity caused by a displaced orbital floor implant
Koenig et al .	1983	The treatment of Necrotizing Scleritis with an autogenous periosteal Graft
Horowitz et al.	1984	Galeal-Pericranial flaps in head and neck reconstruction: anatomy and application
Hurwitz et al.	1989	The use of free periosteal grafts in extensive lower lid reconstruction
Portnoy et al.	1989	Surgical Management of Corneal Ulceration and Perforation
Dingeldein et al.	1990	Mooren's ulcer treated with periosteal graft
Yoshimura et al.	1995	Use of palatal mucosal graft for reconstruction of the eye socket
Beaver et al.	1996	Periocular Autografts in Socket Reconstruction
Glatt HJ	1997	Tarsoconjunctival flap supplementation: an approach to the reconstruction of large lower eyelid defects
Tse et al.	1997	Use of galeal or pericranial flaps for reconstruction pf orbital and eyelid defects
Massry et al .	1999	Frontal periosteum as an exposed orbital implant cover
Liao et al.	2005	Surgical Coverage of exposed hydroxyapatite implant with retroauricular myoperiosteal graft
Leatherbarrow et al.	2006	Use of the Pericranial flap in Medial Canthal Reconstruction: another application for this versatile flap
Rajabi et al.	2012	Total lower lid reconstruction: clinical outcomes of utilizing three-layer flap and graft in one session
Okumoto et al.	2013	Secondary reconstruction of a mobile eye socket 30 years after enucleation of the eyeball for retinoblastoma: a case report
Cardim et al .	2013	Canthopexy and tarsal reinforcement using a periosteal flap
Gupta et al.	2014	Salvaging recurrent scleral buckle exposure with autologous periosteal patch graft
Ibáñez-Flores et al.	2015	Pericranium grafts for exposed orbital implants: An observational case-series study
Rajabi et al.	2016	A novel technique for full thickness medial canthal reconstruction; playing with broken lines
Samira et al.	2016	Rare case of bilateral perforated corneal ulcer due to gonococcal infection, managed with temporary periostealgraft

Periosteal graft

A total of 47 patients (Table 2) were treated using periosteal graft. Of these, 3 patients underwent scleral covering, 1 patient underwent an keratoprosthesis covering, 1 patient underwent a scleral buckle covering, 2 patients underwent corneal ulcer

covering, 1 patient underwent posterior lamella reconstruction, 3 patients underwent reconstruction of the orbital cavity, and 36 patients underwent exposed orbital implants covering.

The complications reported were bone formation (2.12%), granuloma (4.25%), recurrent exposure (10.63%).

Table 2
Use of periosteal graft

Removal site	Use destination	Number of case	Complication
-	Scleral covering	1	-
Anterior tibial	Keratoprosthesis extrusion	1	1 Bone formation
Anterior tibial	Scleral covering	2	-
-	Palpebral Reconstruction	1	-
-	Corneal ulcer	2	-
Palate	Orbital cavity	3	-
Eye socket	Implant covering	5	1 Recurrent exposure
Frontal	Implant covering	15	2 Recurrent exposure
Retroauricular	Implant covering	10	2 Recurrent exposure
Pericranium	Exposed orbital implants	7	1 Granuloma 1 Granuloma
		Total = 47	Total = 7

Periosteal flap

A total of 159 patients (Table 3) were treated using a periosteal flap. Of these, 58 were submitted to a flap of nasal bone for reconstruction of the posterior palpebral lamella, 25 were submitted to pericranial flap for palpebral reconstruction, 75 patients were submitted to lateral eye socket flap for posterior

lamella reconstruction, and 1 patient was submitted to pericranium flap for orbit reconstruction.

The complications reported were partial correction of the defect (2.51%), infection (0.62%), partial (3.14%) and total (0.62%) ischemia of the flap, ectropion (1.25%), and palpebral ptosis (0.62%).

Table 3
Use of periosteal flap

Removal site	Use destination	Number of case	Complication
Pericranium	Orbital reconstruction	2	-
Eye socket	Palpebral Reconstruction	75	4 cases partial remission
Nasal bone	Palpebral Reconstruction	58	-
Pericranium	Palpebral Reconstruction	24	1 Infection, 2 Ectropion, 1 Ptosis 5 Partial ischemia, 1 Total ischemia
		Total = 159	Total = 14

Pericranium

A total of 48 patients (Table 4) were treated with periosteum from Pericranium (including frontal periosteum). Of these, 22 cases were collected as graft for orbital implant covering, and 26 cases were collected as flap for orbital cavity reconstruction⁽²⁾ and palpebral reconstruction.⁽²⁴⁾

The success of surgical intervention using a pericranial graft was 86.36%, showing only 2 cases of recurrent implant exposure, and 1 case with local granuloma formation.

The success of surgical intervention using pericranial flap was 61.53%, with 1 case evolving with palpebral ptosis, 2 cases with ectropion, 1 case with local infection, 5 cases of partial ischemia, and 1 case of total ischemia.

DISCUSSION

The use of periosteum in Ophthalmology is for the most part in Oculoplastics for orbit and eyelid reconstruction, and for the covering of exposed orbital implants, where we can find most of the publications on the subject. However, its initial use from the chronological point of view was designed to cover the ocular surface in cases of scleral tissue replacement such as cases of scleromalacia and necrotizing scleritis.^(2,11)

In all cases reported in the literature, the use of periosteal tissue presented satisfactory results with low complication rates (10.67%) and a minimum number of complications requiring new surgical intervention or patient dissatisfaction with the final result

Quadro 4
Use of pericranium

Collection technique	Destination	Number of Cases	Complications
Graft	Implant covering	22	2 Recurrent Exposures 1 Granuloma
Flap	Orbital reconstruction	2	-
	Palpebral Reconstruction	24	1 Infection, 2 Ectropion, 1 Ptosis 5 Partial ischemia, 1 Total ischemia
		Total 48	Total 13

(2.42%). It is necessary to consider that part of the complications presented may be related to the technique used and not to the material being evaluated since there are no adequate comparative studies to date.

Koenig et al. report a series of cases of periosteal graft use for enhancing the scleral wall in necrotizing scleritis, and relate more satisfactory use of periosteum compared to the donor sclera due to its smaller thickness and greater flexibility of the tissue.⁽¹¹⁾ These characteristics of resistance and malleability allowed the group of Okumoto et al. to use the periosteal graft to cover a cartilage sphere collected from the costal region and used as an orbital implant.⁽¹²⁾

Although it is not the gold standard treatment, the use of periosteum is also described in the literature for corneal covering both in cases of sterile corneal ulcers and in Mooren's ulcer, as well as gonococcal keratitis with ocular perforation.^(13,14)

Liao et al. and Gupta et al. published a series of cases in which they successfully used retroauricular myoperiosteal graft to cover orbital and scleral buckle implants, and emphasize that the periosteum was shown as a more robust option than the sclera or dermoadiposal graft.^(15,16)

The effect of primary and secondary contraction observed in the technique of collection and cicatrization of biological grafts and flaps is of great importance for adequate surgical planning. Skin grafts show a primary contraction of about 9-22% depending on factors such as thickness and amount of elastin, and a final contraction of 40-45%.⁽¹⁷⁻¹⁹⁾ When assessing the contraction presented using periosteum, no study objectively evaluates these criteria. The group of Yoshimura et al. reports that in their experience the use of periosteal graft may present a contraction of up to 30% in the recent postoperative period, but that decreases between the second and third month after surgery to 10-20% of the initial size used.⁽⁴⁾

Massry et al. describe that periosteal grafts up to 25mm in diameter can be collected from the frontal bone through an incision performed in the palpebral groove safely, whereas Guyot et al. describe a technique for the collection of mucoperiosteal graft of the palate under local anesthesia allowing the collection of grafts of up to 40x20mm for idealized use in palpebral reconstruction.^(20,21)

Of all periosteal extraction areas presented in review, pericranium is shown as a more advantageous option by offering a large area for collection, direct access, rich vascularization with multiple anastomoses, minimal probability of nerve damage, and possibility of hiding the surgical scar in the scalp.^(5,22,23)

Retrospective analysis shows that the use of autologous tissues such as periosteum presents better final results when compared to the use of homologous tissues for the orbital implant covering.⁽²⁴⁾

The pericranial flap has excellent blood supply allowing the support of other adjacent grafts in reconstructive surgeries such as skin, bone and cartilage.⁽¹⁾ In addition, it can be used in regions with exposure to air swirling as in reconstruction of orbital fistulas with nasal sinus.⁽¹⁰⁾

The main advantages of using periosteum are:

- The use of an autologous tissue of fast access and availability inducing a lower inflammatory response, early revascularization, and not inducing sensitization with donor tissue;
- Greater tissue bank independence and lower infectious risk;
- Satisfactory support and structuring ability when used for orbital and palpebral reconstruction;
- Good results when used for orbital and buckle implant covering;
 - Adequate resistance, malleability and thickness for scleral wall reinforcement;
 - Possibility of use for covering of corneal ulcers;
 - Possibility of using tissue flap with blood supply, and support of neighboring tissues with poor circulation.

The main disadvantages of using periosteum are:

- Learning curve technique for removal of periosteal tissue from different possible regions, often not with great familiarity with ophthalmologist surgeons;
 - Need for exploration of possible second surgical site for tissue collection;
 - Theoretical increase in the risk of sympathetic ophthalmia, not shown by the studies⁽³⁾

Limitations of the study

The use of periosteum in ophthalmology is shown in the literature with great potential of use and versatility. However, two important points limit the consolidation of knowledge: few studies published in the area of knowledge recently, being subject to a bias of temporality in data analysis, and lack of studies with greater analytical power, with most of the studies analyzed being reports and series of cases.

CONCLUSION

The use of Periosteum in Ophthalmology is promising, with satisfactory results published so far, and should always be a therapeutic option to be considered by the Ophthalmologist for their patient. However, there is a need for further studies on the case, especially comparative clinical trials to better sediment the knowledge on the subject.

REFERENCES

1. Tse DT, Goodwin WJ, Johnson T, Gilberg S, Meldrum M. Use of galeal or pericranial flaps for reconstruction or orbital and eyelid defects. *Arch Ophthalmol* (Chicago, Ill 1960). 1997;115(7):932-7.
2. Rao GN, Aquavella JV, Palumbo AJ. Periosteal graft in scleromalacia. *Ophthalmic Surg.* 1977;8(5):86-92.
3. Beaver HA, Patrinely JR, Holds JB, Soper MP. Periocular autografts in socket reconstruction. *Ophthalmology.* 1996;103(9):1498-502.

4. Yoshimura Y, Nakajima T, Yoneda K. Use of the palatal mucosal graft for reconstruction of the eye socket. *J Craniomaxillofac Surg.* 1995;23(1):27–30.
5. Ibanez-Flores N, Abia-Serrano M, Aznar-Pena I, Mascaro-Zamora F, Castellar-Cerpa J, Anaya-Alaminos R, et al. Pericranium grafts for exposed orbital implants: An observational case-series study. *J Craniomaxillofac Surg.* 2015;43(7):1017–20.
6. Augustin G, Antabak A, Davila S. The periosteum. Part 1: Anatomy, histology and molecular biology. *Injury.* 2007;38(10):1115–30.
7. Ritsila VA, Santavirta S, Alhopuro S, Poussa M, Jaroma H, Rubak JM, et al. Periosteal and perichondral grafting in reconstructive surgery. *Clin Orthop Relat Res.* 1994;(302):259–65.
8. Goldberg RA, Rosenbaum AL, Tong JT. Use of apically based periosteal flaps as globe tethers in severe parietic strabismus. *Arch Ophthalmol (Chicago, Ill 1960).* 2000;118(3):431–7.
9. O'Driscoll SW. Technical considerations in periosteal grafting for osteochondral injuries. *Clin Sports Med.* 2001;20(2):379–402, vii.
10. Leatherbarrow B, Watson A, Wilcsek G. Use of the pericranial flap in medial canthal reconstruction: another application for this versatile flap. *Ophthalm Plast Reconstr Surg.* 2006;22(6):414–9.
11. Koenig SB, Kaufman HE. The treatment of necrotizing scleritis with an autogenous periosteal graft. *Ophthalmic Surg.* 1983;14(12):1029–32.
12. Okumoto T, Koike G, Yoshimura Y. Secondary reconstruction of a mobile eye socket 30 years after enucleation of the eyeball for retinoblastoma: a case report. *J Plast Reconstr Aesthet Surg.* 2014;67(3):399–402.
13. Samira N, Bani AP, Susiyanti M. Rare case of bilateral perforated corneal ulcer due to gonococcal infection, managed with temporary periosteal graft. *BMJ Case Rep.* 2016;2016.
14. Dingeldein SA, Insler MS, Barron BA, Kaufman HE. Mooren's ulcer treated with a periosteal graft. *Ann Ophthalmol.* 1990;22(2):56–7.
15. Liao SL, Kao SCS, Tseng JHS, Lin LL-K. Surgical coverage of exposed hydroxyapatite implant with retroauricular myoperiosteal graft. *Br J Ophthalmol.* 2005;89(1):92–5.
16. Gupta SR, Anand R, Diwan S, Gupta N. Salvaging recurrent scleral buckle exposure with autologous periosteal patch graft. *Retin Cases Brief Rep.* 2014;8(3):178–82.
17. Harrison CA, MacNeil S. The mechanism of skin graft contraction: an update on current research and potential future therapies. *Burns.* 2008;34(2):153–63.
18. Davis JS. The immediate contraction of cutaneous grafts and its cause. *Arch Surg.* 1931;23(6):954–65. 8004
19. Hinshaw JR, Miller ER. Histology of healing split-thickness, full-thickness autogenous skin grafts and donor sites. *Arch Surg.* 1965;91(4):658–70.
20. Massry GG, Holds JB. Frontal periosteum as an exposed orbital implant cover. *Ophthalm Plast Reconstr Surg.* 1999;15(2):79–82.
21. Guyot L, Layoun W, Benso-Layoun C, Richard O, Gola R. [Hard palate mucosal graft for posterior lamella repair]. *J Fr Ophtalmol.* 2004;27(9 Pt 1):1071–6.
22. Desai SC, Sand JP, Sharon JD, Branham G, Nussenbaum B. Scalp reconstruction: an algorithmic approach and systematic review. *JAMA Facial Plast Surg.* 2015;17(1):56–66.
23. Cho JM, Jeong JH, Woo KV, Lee YH. Versatility of retroauricular mastoid donor site: a convenient valuable warehouse of various free graft tissues in cosmetic and reconstructive surgery. *J Craniofac Surg.* 2013;24(5):e486-90.
24. Remulla HD, Rubin PA, Shore JW, Sutula FC, Townsend DJ, Woog JJ, et al. Complications of porous spherical orbital implants. *Ophthalmology.* 1995;102(4):586–93.

Corresponding author:

Felipe Baccega
 Rua Oscar Freire, 1758. Apto 114B
 Phone: (11)985354218
 E-mail: felipebaccega@gmail.com