

Straatsma syndrome

Síndrome de Straatsma

Aluisio Rosa Gameiro Filho¹ <https://orcid.org/0000-0002-8787-0417>

Rodrigo Rosa Gameiro² <https://orcid.org/0000-0001-9600-6228>

Flávio Mac Cord Medina³ <https://orcid.org/0000-0003-2656-2960>

ABSTRACT

The presence of retinal myelinated nerve fibers is not a rare finding during routine examinations, and it is usually a benign and isolated finding. However, in some rare cases, it can be associated with other ophthalmological conditions. We describe a case of a patient with the triad myelin nerve fibers, myopia and ambliopia, which configures the Straatsma Syndrome.

Keywords: *Anisometropia; Ambliopia, Myopia/diagnosis; Myopia/etiology; Myopia/physiopathology; Nerve fibers, myelinated/pathology; Optic nerve diseases/complications*

RESUMO

A presença de fibras de mielina é um achado comum durante exames oftalmológicos de rotina. Na maior parte das vezes, tem caráter benigno e é um achado isolado. No entanto, em alguns raros casos, a presença de mielinização pode estar associada a outras condições oftalmológicas. Descrevemos um caso de paciente com a tríade presença de fibras nervosas retinianas mielinizadas, miopia, e ambliopia, configurando a síndrome de Straatsma.

Descritores: Anisometropia; Ambliopia; Miopia/diagnostico; Miopia/etiologia; Miopia/fisiopatologia; Fibras nervosas mielinizadas/patologia; Doenças do nervo óptico/complicações

¹ Programa de Residência em Oftalmologia, Hospital Federal dos Servidores do Estado do Rio de Janeiro, Rio de Janeiro, RJ, Brazil.

² Acadêmico de Medicina, Pontifícia Universidade Católica do Paraná, Curitiba, PR, Brazil.

³ Setor de Retina e Vítreo, Hospital Federal dos Servidores do Estado do Rio de Janeiro, Rio de Janeiro, RJ, Brazil.

Institution: Hospital Federal dos Servidores do Estado do Rio de Janeiro, Rio de Janeiro, RJ, Brazil.

The authors declare no conflicts of interests.

Received for publication 07/05/2019 - Accepted for publication 21/05/2019.

INTRODUCTION

First described by Virchow in 1856,⁽¹⁾ myelinated nerve fiber appears at funduscopy as white striated opacities, following the distribution of retinal nerve fibers. They are usually benign⁽²⁾ and diagnosis is usually made by chance. In some cases it can be associated with other conditions, such as neurofibromatosis and vitreoretinal disorders.⁽³⁾ Patients are usually asymptomatic, but a few cases can present significant visual abnormalities, in special axial myopia and amblyopia, configuring the Straatsma Syndrome. We report a case of a 60 years old female patient with this rare syndrome.

CASE REPORT

60 years old female patient, attended at our Ophthalmology ambulatory referred by her endocrinologist for funduscopy for diabetic retinopathy screening. Patient referred low visual acuity on her left eye (OS) since her childhood, and denied any other complaints. She had well controlled type 2 diabetes for 12 years, high blood pressure for 49 years and history of a treated breast cancer 10 years before.

On exam: best corrected visual acuity (BCVA) of 20/20 in her right eye (OR) (+0.75 = -1.25 x 95°) and 20/60 in her left eye (OS) (-6.00 = -1.75 x 40°). Biomicroscopy showed nuclear cataract (1/4+) in both eyes. At funduscopy: OR was normal and OS showed white striated opacities emerging from the optic disk, following the distribution of retinal nerve fibers (Figure 1). Fundus autofluorescence showed hyperautofluorescence (Figure 2). The axial length of her eyes was 22,39mm in OR and 26,48mm in OS. OCT (optical coherence tomography) showed presence of myelin at the same topography in OS.

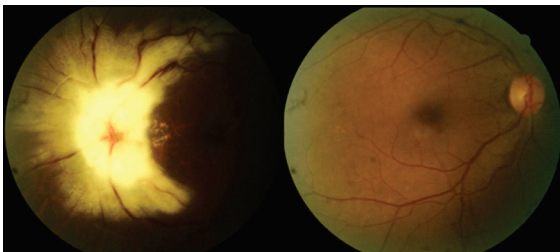


Figure 1: Funduscopy of both eyes. OR normal and OS showing myelin fibers

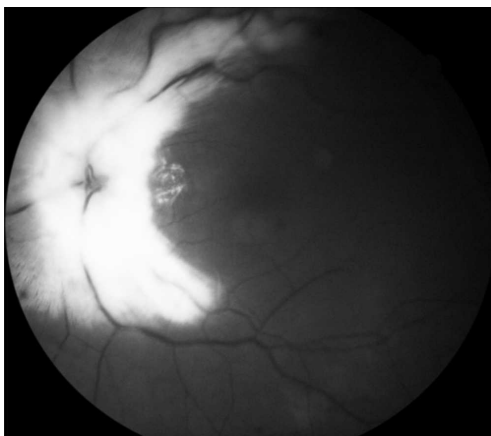


Figure 2: Fundus autofluorescence showing hyperautofluorescence along myelinated areas

DISCUSSION

Straatsma estimates that only 0,54% of the eyes have some sort of myelin fibers, with bilateral involvement in just 7,7% of cases⁽⁴⁾ and with no gender predominance. The pathogenesis of this condition isn't fully well known: myelination starts at the 5th month of pregnancy, and it is over before birth. The lamina cribosa acts as a barrier for the myelination. Parulekar⁽⁵⁾ believes that the presence of myelin in some eyes occurs as a result of a disruption of this lamina. Other possibilities were suggested in literature, such as heteropic cells migrating to retina during in utero development,⁽⁶⁾ but there is no consensus until today.

Usually this condition is asymptomatic, and it is discovered during routine examinations. However, in some cases, it can be associated with other conditions, such as retinal telangiectasia, neurofibromatosis, Down syndrome, vitreoretinal degenerations, familiar myelinated retinal fibers, Straatsma syndrome, coloboma, keratoconus, craniosynostosis, hydrocephalus, Gorlin syndrome, and others. Myelin fibers are more frequent in the superior temporal quadrant, followed by the inferior temporal quadrant. It is typically stationary, but regression was previously reported in the literature: after Leber neuropathy, arterial occlusions, radiotherapy, and others.^(3,7,8,9)

Straatsma Syndrome was described initially in 1979, and it is responsible for only 0.3-10% of all cases of eyes with myelin fibers. It is characterized by the association of myelin fibers, axial myopia and amblyopia. Some authors also describe the association of strabismus with this syndrome, which is not a sine qua non condition for this syndrome.

The mechanism for development of myopia in these cases is also obscure. Some theories were previously suggested: Moradian believes that an eye with a largest axial length would present a slowly development of the lamina cribosa, which could generate an anomalous functional barrier, allowing a transitory myelination.⁽³⁾ On the other side, Straatsma suggests that the presence of myelin fibers in a crucial phase on ocular development would interfere in image acquisition, generating a visual privation, and consequently an increase in axial length.⁽⁴⁾

Amblyopia can occur for 3 main reasons: a Structural defect, in which the presence of myelin would change the normal light transmission, and also the conduction of the luminous stimulus;⁽³⁾ a Refractive defect, in which anisometropia as a result of the unilateral presence of myelin fibers would be responsible for amblyopia; and last, but not least a Strabismus component could also be responsible for amblyopia. Because of this multifactorial etiology, occlusion and other common therapies do not have satisfactory results in these cases.⁽³⁾

The treatment for this syndrome is usually made by the use of glasses or contact lenses, as well as occlusion for the amblyopia, if is the case. However, even with the correct treatment, only one third of patients will have a final visual acuity better than 20/30.⁽¹⁰⁾

CONCLUSION

Although Ophthalmologists are familiar with of the presence of myelin fibers, a benign and innocuous condition, which is usually detected incidentally during ocular examination, it is important to also know about ocular associations and differential diagnosis of this condition, such as Straatsma Syndrome.

REFERENCES

1. Virchow VR. Zur pathologhisen anatomic der netzaut und der scherven. *Virchows Arch Patol Anat* 1856;10:170-93;
2. Rodrigues MI, Loureiro C, Almeida L, Grillo MM. Persistência de fibras de mielina e não só: Síndrome de Straatsma. *Ophthalmologia*. 2013;37(2):117-24
3. Tarabishy AB, Alexandrou TJ, Traboulsi EI. Syndrome of myelinated retinal nerve fibers, myopia, and amblyopia: a review. *Surv Ophthalmol*. 2007;52(6):588-96.
4. Straatsma BR, Heckenlively JR, Foos RY, Shahinian JK. Myelinated retinal nerve fibers associated with ipsilateral myopia, amblyopia, and strabismus. *Am J Ophthalmol*. 1979;88(3 Pt 1):506-10.
5. Parulekar MV, Elston JS. Acquired retinal myelination in neurofibromatosis 1. *Arch Ophthalmol*. 2002;120(5):659-5.
6. Felipe DL, Sánchez TD. Síndrome de mielinización de fibras nerviosas retinales, miopía y ambliopía. *Rev Cubana Ophthalmol*. 2013; 26(1):668-78.
7. Coman I, Barbin G, Charles P, Zalc B, Lubetzki C. Axonal signals in central nervous system myelination, demyelination and remyelination. *J Neurol Sci*. 2005;233(1-2):67-71. Review.
8. Straatsma BR, Foos RY, Heckenlively JR, Taylor GN. Myelinated retinal nerve fibers. *Am J Ophthalmol*. 1981;91(1):25-38.
9. Leys AM, Leys MJ, Hooymans JM, Craandijk A, Malenfant M, van Germeersch D, et al. Myelinated nerve fibers and retinal vascular abnormalities. *Retina*. 1996;16(2):89-96.
10. Lee MS, Gonzalez C. Unilateral peripapillary myelinated retinal nerve fibers associated with strabismus, amblyopia, and myopia. *Am J Ophthalmol*. 1998;125(4):554-6.

Corresponding author:

Aluisio Rosa Gameiro Filho
Rua Sacadura Cabral, 178 - Saúde - Rio de Janeiro - RJ - Brazil
Zip code: 20221-903
E-mail: agameirofilho@yahoo.com.br