

# Unilateral intravitreal dexamethasone implant for the treatment of cystoid macular edema in intermediate uveitis

## *Implante unilateral de dexametasona intravítrea para tratamento de edema macular cistoide na uveíte intermediária*

Bruno Boalento dos Santos<sup>1</sup> <https://orcid.org/0000-0001-7558-6534>  
Maurélio de Lima Batista Ribeiro Jr<sup>1</sup> <https://orcid.org/0000-0003-2242-6865>  
Marcello Novoa Colombo Barboza<sup>2</sup> <https://orcid.org/0000-0001-7573-885X>  
Marta Fabiane Gouvea Barioni<sup>2</sup> <https://orcid.org/0000-0003-1037-229X>

### ABSTRACT

*This report aims to describe the effectiveness of a unilateral intravitreal dexamethasone implant (Ozurdex®) used for the treatment of cystoid macular edema in a patient with recurrent intermediate uveitis. Bearing in mind the adverse effects of the prolonged use of systemic corticosteroids, the objective here was to provide a less damaging form of intervention, and also to demonstrate the safety of the dexamethasone implant for patients who fail to respond to conventional treatment. In the present case, there was bilateral improvement in retinal anatomy and function with use of the unilateral intravitreal dexamethasone implant (Ozurdex®).*

**Keywords:** Intravitreal injections/adverse effects; Dexamethasone; Cystoid macular edema; Uveities, intermediate

### RESUMO

Neste estudo, o objetivo foi descrever, a partir de um relato de caso, a eficácia do uso de implante de dexametasona intravítrea (Ozurdex®) unilateral, para o tratamento de edema macular cistoide, em um paciente com quadro de uveíte intermediária recorrente, visando uma terapêutica menos lesiva, diante dos efeitos colaterais do uso prolongado de corticosteroides sistêmicos, demonstrando também a segurança desse tratamento alternativo para aqueles pacientes que se apresentam refratários a terapêutica tradicional. No caso relatado, vale ressaltar a melhora bilateral da anatomia e função retiniana com o implante unilateral de dexametasona intravítrea (Ozurdex®).

**Descritores:** Injeções intravítreas/efeitos adversos; Dexametasona; Edema macular cistoide; Uveíte intermediária

<sup>1</sup> Instituto Visão do Bem, Santos, São Paulo, Brazil.

<sup>2</sup> Hospital Oftalmológico Visão Laser, Santos, São Paulo, Brazil.

Approved by the following research ethics committee: Hospital Guilherme Alvaro (CAAE: 28449219.1.0000.5448)

**The author declare no conflict of interest**

Received for publication 30/3/2020 - Accepted for publication 10/9/2020.



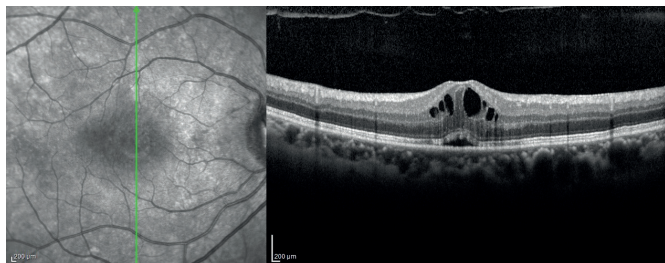
## INTRODUCTION

Corticosteroids are a mainstay in the treatment of intermediate uveitis; however, this treatment involves undesirable adverse effects, particularly when use is prolonged, as is often necessary in cases of recurrence or followed by complications. Electrolyte, gastrointestinal, cardiovascular and ocular disorders are common during chronic use of corticosteroids or when high doses are used.<sup>(1,2)</sup> Therefore, with the objective of minimizing damage to the patient while guaranteeing effective and safe treatment, the use of an intravitreal implant appears to represent an alternative therapeutic option for cystoid macular edema, particularly in related cases of intermediate uveitis.<sup>(3,4)</sup>

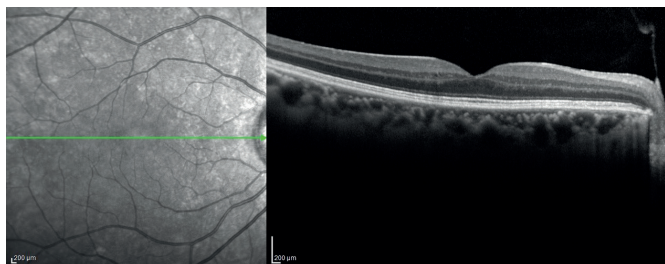
### Case Report

A 53-year old black housekeeper presented with a complaint of low visual acuity (VA) and hyperemia in both eyes over the preceding eight years. She reported being in use of oral prednisone 60 mg/day. In addition, she had diffuse joint pain and recurrent crises of uveitis, and had undergone treatment with oral and intramuscular corticosteroids, with no improvement in vision. She mentioned having felt ill after starting the treatments. Previous exams consisted of: purified protein derivative (PPD) skin test: 00 mm, a negative VDRL, a negative *Treponema pallidum* test, a non-reactive HIV test and normal chest x-ray. Ophthalmologic examination revealed: uncorrected VA 20/40 and 20/25; intraocular pressure 14 and 15 mmHg. Biomicroscopy: white and fine keratic precipitates (KP), with some being granulomatous, in both eyes; anterior chamber reaction 2+ in right eye and 1+ in left eye; vitreous cells 3+ with crystalline opacity in both eyes. Retinal imaging: pink optic disc with clear borders in both eyes; vitritis 3+ in right eye and 1+ in left eye; Dalen-Fuchs nodules in both eyes. Management: Chest computed tomography (CT); optical coherence tomography (OCT) macular scan; and evaluation by a rheumatologist. Prednisolone 1% and tropicamide were prescribed for both eyes. The patient was instructed to taper off oral prednisone use.

One month later, with no oral medication: uncorrected VA



**Figure 1:** Macular optical coherence tomography of the right eye before use of a unilateral intravitreal dexamethasone implant (Ozurdex®)



**Figure 3:** Macular optical coherence tomography of the right eye after use of a unilateral intravitreal dexamethasone implant (Ozurdex®)

20/60 and 20/30. Biomicroscopy: fine KPs; no anterior chamber reaction; crystalline opacity in both eyes. OCT: cystoid macular edema in both eyes (Figures 1 and 2). Non-contrast chest CT: normal. Management: intravitreal dexamethasone implant (Ozurdex®) in the right eye.

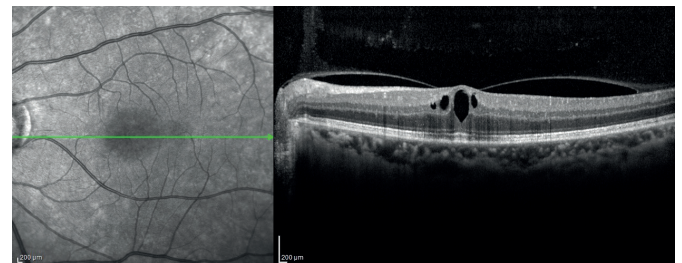
One month after the implant: uncorrected VA 20/30 and 20/25; intraocular pressure 16 and 14 mmHg. Biomicroscopy: no anterior chamber reaction and a subcapsular cataract in both eyes. OCT: regression of the cystoid macular edema in both eyes (Figures 3 and 4). After 8 months, no signs of eye inflammation. A second chest CT with contrast was normal.

## DISCUSSION

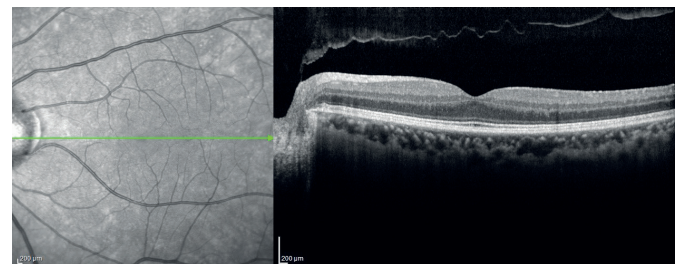
Because of the anatomy and physiology of the eye, there are few treatment options for the possible complications resulting from intermediate and posterior uveitis. Of the principal complications, macular edema greatly affects the patient's quality of life due to the increase in inflammatory mediators and breakdown of the blood-retinal barrier. Corticosteroids play a crucial role in the treatment of retinal diseases by blocking these mediators.

The blood-retinal barrier prevents topical and systemic drugs from reaching necessary therapeutic levels in the structures of the posterior pole of the eye. A more effective alternative consists of intravitreal administration.<sup>(1)</sup> Local therapy reduces the incidence of systemic adverse effects, which include fluid retention, arterial hypertension, osteoporosis, mood swings and psychosis, skin disorders, weight changes, musculoskeletal disorders and connective tissue disorders.<sup>(2,3)</sup>

Adverse effects have been directly associated with the dose of corticosteroid required for treatment. Notably, a 10-mg increase in the daily dose of prednisone accounts for a 1.5 to 2.6-fold increase in the rate of adverse events.<sup>(4)</sup> This means that a patient with active uveitis in use of 60 mg/day of prednisone will have, on average, 10.1 times more secondary effects compared to a patient in use of 10 mg/day. Indeed, the results of the VISUAL-1 and VISUAL-2 clinical trials suggest that the incidence rates of adverse events during chronic use are dose-dependent.<sup>(4)</sup>



**Figure 2:** Macular optical coherence tomography of the left eye before use of a unilateral intravitreal dexamethasone implant (Ozurdex®)



**Figure 4:** Macular optical coherence tomography of the left eye after use of a unilateral intravitreal dexamethasone implant (Ozurdex®)

To insert the Ozurdex® (dexamethasone) intravitreal implant, a puncture is made into the eye 3.5 mm from the limbus, followed by intravitreal injection of the poly (lactic-co-glycolic) acid (PLGA) implant, which releases dexamethasone with a stable half-life into the eye for up to thirty days, treating macular edemas over a 3-6-month period.<sup>(5)</sup>

The present case consisted of cystoid macular edema as a complication, in a classic presentation of recurrent intermediate uveitis, in which the patient became intolerant to the use of systemic corticosteroids (prednisone 60 mg/day) and failed to improve VA after a month of topical treatment (20/60 and 20/30), with the presence of fine PKs, but no anterior chamber reaction and no vitreous cells in both eyes at biomicroscopy, besides cystoid macular edema in both eyes, observed in OCT. However, it is noteworthy that chest CT was performed during the use of systemic corticosteroids, fact that can hide the final diagnosis. Therefore, with the improvement of the inflammatory condition, it was decided to treat the cystoid macular edema, as we would continue the diagnostic investigation.

Since the failed improvement of VA with topical treatment, after advising on the risks or need for future applications, and in agreement with the patient, it was decided to opt for the intravitreal treatment of cystoid macular edema, with Ozurdex® implant, in the eye with lower VA. One month later, there was significant anatomical and functional recovery in both eyes, with an improvement in VA to 20/30 and 20/25, while macular thickness decreased from 496 µm to 285 µm in the right eye and from 397 µm to 305 µm in the left eye, with no increase in intraocular pressure, no anterior chamber reaction at biomicroscopy and regression of the cystoid macular edema at OCT. The patient was followed up for eight months, with no recurrence.

One of the possible side effects of the implant is an increase in intraocular pressure, which was reported in less than 16% of patients in the GENEVA study. Nevertheless, according to the Shasta study, it is known that only 1.7% of patients with increased intraocular pressure following use of the implant will be submitted to surgery for glaucoma, suggesting that the corticosteroid-related increase in pressure is transitory.<sup>(6-8)</sup>

Habot-Wilner et al.,<sup>(9)</sup> reported bilateral improvement of cystoid macular edema with unilateral Dexamethasone implant, in a patient with non-infectious uveitis. The observed fact was related to the compromised blood-retina barrier in eyes with uveitis.

Ciszewska et al.,<sup>(10)</sup> similar to the previous case, was able to observe positive effect of unilateral Dexamethasone implant in the contra-lateral eye, for cystoid macular edema.

In the current year, Pareja-Ríos et al.,<sup>(11)</sup> described three patients with bilateral improvement of cystoid macular edema after unilateral use of the implant, in diabetic patients.

No complications were seen in the case reported here, showing the effectiveness and safety of intravitreal treatment with the Ozurdex® implant for cystoid macular edema in intermediate uveitis. This is particularly useful in cases that prove intolerance

to conventional treatment. Above all, even it is unclear why Dexamethasone implant affects the contralateral eye, the bilateral improvement in cystoid macular edema with only unilateral use of the implant is noteworthy.

## REFERENCES

- Hosoya K, Tachikawa M. Inner blood-retinal barrier transporters: role of retinal drug delivery. *Pharm Res.* 2009;26(9):2055–65.
- Kim JS, Knickelbein JE, Nussenblatt RB, Sen HN. Clinical trials in noninfectious uveitis. *Int Ophthalmol Clin.* 2015;55(3):79–110.
- Chirikov VV, Shah R, Kwon Y, Patel D. Oral corticosteroid exposure and increased risk of related complications in patients with noninfectious intermediate, posterior, or panuveitis: real-world data analysis. *Ophthalmic Epidemiol.* 2019;26(1):27–46.
- Suhler EB, Thorne JE, Mittal M, Betts KA, Tari S, Camez A, et al. Corticosteroid-related adverse events systematically increase with corticosteroid dose in noninfectious intermediate, posterior, or panuveitis: post hoc analyses from the VISUAL-1 and VISUAL-2 trials. *Ophthalmology.* 2017;124(12):1799–807.
- Lowder C, Belfort R Jr, Lightman S, Foster CS, Robinson MR, Schiffman RM, et al.; Ozurdex HURON Study Group. Dexamethasone intravitreal implant for noninfectious intermediate or posterior uveitis. *Arch Ophthalmol.* 2011;129(5):545–53.
- Haller JA, Bandello F, Belfort R Jr, Blumenkranz MS, Gillies M, Heier J, et al.; OZURDEX GENEVA Study Group. Randomized, sham-controlled trial of dexamethasone intravitreal implant in patients with macular edema due to retinal vein occlusion. *Ophthalmology.* 2010;117(6):1134–1146.e3.
- Capone A Jr, Singer MA, Dodwell DG, Dreyer RF, Oh KT, Roth DB, et al. Efficacy and safety of two or more dexamethasone intravitreal implant injections for treatment of macular edema related to retinal vein occlusion (Shasta study). *Retina.* 2014;34(2):342–51.
- Malclès A, Dot C, Voirin N, Vié AL, Agard É, Bellocq D, et al. Safety of intravitreal dexamethasone implant (Ozurdex): the SAFODEX study. Incidence and risk factors of ocular hypertension. *Retina.* 2017;37(7):1352–9.
- Habot-Wilner Z, Sorkin N, Goldenberg D, Goldstein M. Bilateral effect of unilateral dexamethasone intravitreal implant in a case of noninfectious uveitic macular edema and vitritis. *Retin Cases Brief Rep.* 2015;9(2):151–3.
- Ciszewska J, Brydak-Godowska J, Kuznik-Borkowska A, Kecik D. The effect of a single intravitreal implantation of dexamethasone on the fellow eye in bilateral non-infectious uveitis - case report. *Eur Rev Med Pharmacol Sci.* 2016;20(6):1003–7.
- Pareja-Ríos A, Bonaque-Gonzalez S. Unilateral intravitreal dexamethasone implant for diabetic macular edema: effect in the contralateral eye. *Arq Bras Oftalmol.* 2020;(83):73–5.

### Corresponding author:

Bruno Boalento dos Santos

Rua Dr. Arthur Porchat de Assis 50, Apto. 34, Boqueirão

Zip code: 11045-540 Santos, SP, Brazil.