

# Fundus autofluorescence in a case of benign concentric annular macular dystrophy

## *Autofluorescência em um caso de distrofia macular anular concêntrica benigna*

Clarissa dos Reis Pereira<sup>1</sup> <https://orcid.org/0000-0001-5006-0288>  
Maurício B. Pereira<sup>2</sup> <https://orcid.org/0000-0002-1527-4448>  
Eduardo de França Damasceno<sup>2</sup> <https://orcid.org/0000-0002-7881-3584>

### ABSTRACT

*The benign concentric annular macular dystrophy (BCAMD) is a very rare and probably underdiagnosed eye disease, characterized by a retinal fault in bull's eye pattern, without the association with antimalarial use, but related with good visual acuity. Since there aren't many publications about this condition, is hard to find data regarding the results of complementary examination. In this article, is presented the description of fundus autofluorescence in a classic BCAMD case, yet unpublished, and capable of helping the diagnosis and follow-up of this pathology.*

**Keywords:** Retinal dystrophy; Macular dystrophy; Fundus Autofluorescence; Eye disease.

### RESUMO

A distrofia macular anular concêntrica benigna (DMACB) é uma patologia retiniana rara e provavelmente subdiagnosticada em nosso meio, que se caracteriza por um defeito retiniano em bull's eye sem uso prévio de antimaláricos, associado à preservação relativa da acuidade visual. Devido à escassez de publicações sobre o tema, existem poucos dados referentes aos resultados dos exames complementares nesta patologia. No presente artigo, apresenta-se a descrição da autofluorescência em um caso clássico de DMACB, ainda inédita na literatura, podendo acrescentar achados importantes para auxiliar no diagnóstico e seguimento da doença.

**Descritores:** Distrofia retiniana; Distrofia macular; Autofluorescência retiniana; Oculopatias.

<sup>1</sup> Hospital das Clínicas, Universidade de São Paulo, São Paulo, SP, Brazil.

<sup>2</sup> Universidade Federal Fluminense, Niterói, Rio de Janeiro, RJ, Brazil.

**The authors declare no conflicts of interests.**

Received for publication 12/10/2018 - Accepted for publication 04/12/2018.

## INTRODUCTION

**B**enign concentric annular macular dystrophy (BCAMD) is a rare condition with no estimated incidence.<sup>(1)</sup> The disease was first described by Deutman in 1974,<sup>(2)</sup> and is characterized by a ring of hypopigmentation around a seemingly normal fovea (bull's eye) but without previous history of antimalarials use.<sup>(2)</sup> In general, visual acuity is good or slightly impaired, and there may be dyschromatopsia, especially in the blue-yellow spectrum.<sup>(1-4)</sup> It has an autosomal dominant inheritance,<sup>(2)</sup> being important to consider the family history as a contributing factor for the diagnosis.<sup>(1)</sup> Although rare, its importance lies in the differential diagnosis of other macular degenerations that do not have a benign visual prognosis.<sup>(1,3-6)</sup>

Complementary examinations help in the differentiation of such more serious pathological conditions. Fluorescein angiography shows a Retinal pigment epithelial window defect translated by ring hyperfluorescence around the fovea.<sup>(1,3,4)</sup> The visual field may demonstrate typical annular scotoma or only paracentral defects;<sup>(1-4)</sup> the full-field electroretinogram (ERG) tends to be normal since it is a disease restricted to the macular region.<sup>(1,3-6)</sup> There are rare descriptions of optical coherence tomography (OCT) in the literature reporting sensorineural retinal atrophy associated with RPE thickening with areas of high and low reflectivity below it.<sup>(7)</sup>

To date, few cases have been reported, and there is no scientific publication on the autofluorescence pattern exclusively in this condition. Thus, the importance of such a description is justified to add data in the evaluation of BCAMD.

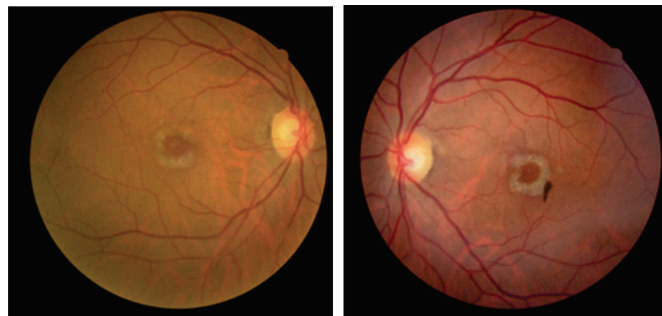
## OBJECTIVE

To describe the findings of autofluorescence in a classic case of benign concentric macular annular dystrophy, adding data to the diagnosis of this rare condition which is one of the differential diagnoses of target maculopathies.

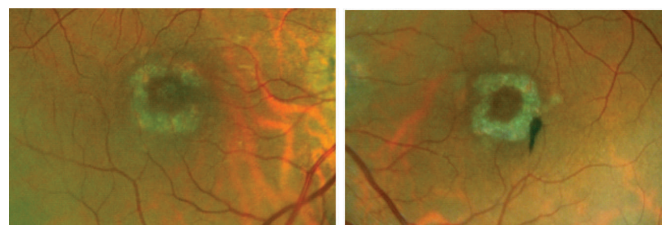
## CASE REPORT

SS, 68 years old, male, complaining of LVA after phacoemulsification of the LE about 1 year ago. He denies pain, ocular hyperemia or other symptoms. He denies complications or post-surgical trauma. He has systemic arterial hypertension well controlled with Losartan 50 mg/day. He denies other comorbidities or the use of other medications throughout life. There are no relevant data in family history. It was not possible to examine his parents as they had already died; the patient has no siblings. His children did not want to be examined so far.

At ophthalmologic examination, corrected vision was 20/25 RE (-1,25 ESF), and 20/50 LE (-2,75 ESF). Ishihara test revealed dyschromatopsia (2 plates/16). The anterior segment biomicroscopy showed 2+ corticonuclear cataract in the RE, and topical IOL in the LE, with no evidence of posterior capsule opacity. There were no signs of previous ocular inflammation, and the IOP was normal in BE. Fundoscopy showed an increase in the excavation/disc ratio of 0.6Vx0.6H in the RE and 0.5VX0.6H in the LE, and a ring of hypopigmentation concentric to the fovea (bull's eye) in BE, with a more pronounced atrophy in the LE, where it was also observed hyperpigmented lesion adjacent to the ring in the inferior temporal region suggestive of bony spicule (Figures 1 and 2).

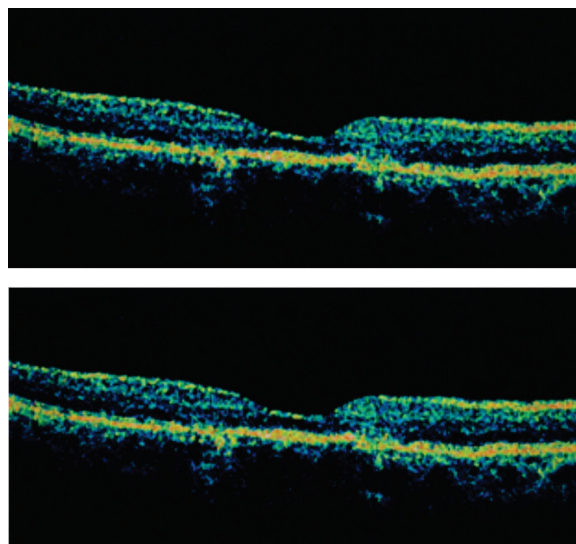


**Figure 1:** Color retinography of the RE and LE revealing the characteristic image of bull's-eye macular atrophy.



**Figure 2:** Enlarged color retinography of the RE and LE revealing the characteristic image of bull's-eye macular atrophy and pigmented lesion in the LE.

OCT revealed significant atrophy of the sensorineural retina with a central thickness of 170 microns in the RE and 150 microns in the LE. There was also a slight thickening of RPE with areas of hypo- and hyperreflectivity sub-RPE more evident in the LE (Figure 3).



**Figure 3:** OCT optical section showing significant atrophy of the foveal sensorineural retina.

The full field ERG was normal (Figure 4), and the computerized visual field (CVF) strategy 60.2 (Humphrey, Zeiss, Germany) showed typical annular scotoma (Figure 5) with relative preservation of the 10th central in the CVF strategy 10.2 (Figure 6), although the parameters were not fully reliable due to the patient's difficulty in maintaining the fixation in the first campimetry carried out..

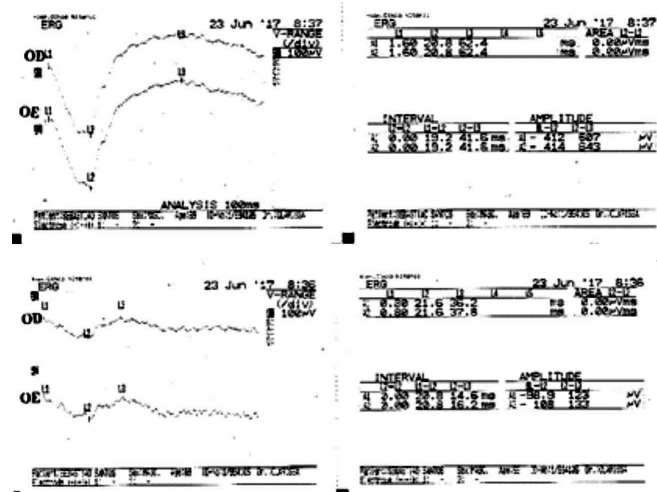


Figure 4: Full field ERG

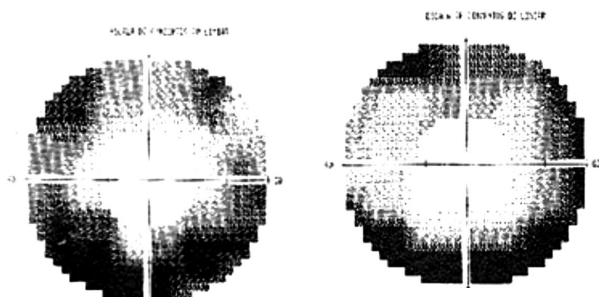


Figure 5: Computerized visual campimetry (60.2) of the RE and LE

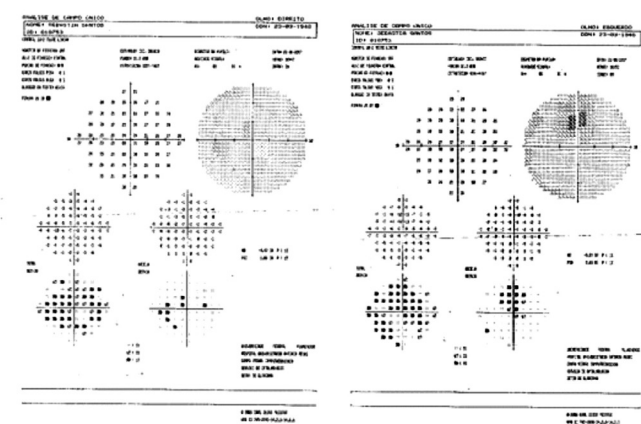


Figure 6: Computerized visual campimetry (10.2) of the RE and LE

Autofluorescence showed concentric ring hypo autofluorescence to a discreetly hypoaurofluorescent fovea in BE. In the LE, we also observed small satellites to the ring, also hypoaurofluorescent (Figure 7).

Adding the clinical and complementary findings, besides considering the preservation of visual acuity in the sixth decade of life, to the typical findings of target maculopathy with no history of antimalarials use, the diagnosis of BCAMD was determined keeping the patient under ambulatory follow-up twice a year.

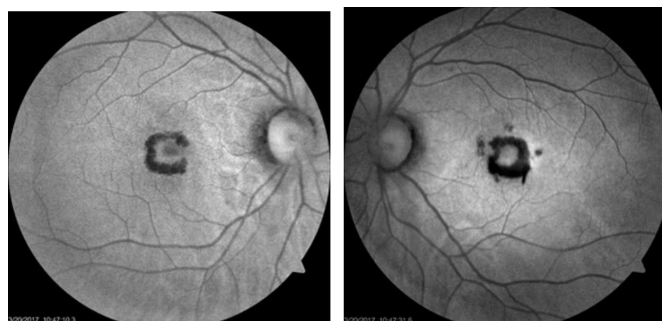

Figure 7: Autofluorescence retinographies of the RE and LE.

## DISCUSSION

Despite its first description in 1974 by Deutman,<sup>(2)</sup> BCAMD remains a rare entity to date, with few cases reported in the literature. Because of its mostly benign nature and difficulty in accessing specialized care, it may be underdiagnosed in our country.

Satisfactory visual acuity was initially reported as a striking finding of this condition, but some evidence already contradicts this statement presenting cases with progression of tapetoretinal dystrophy,<sup>(4,5)</sup> consequent worsening of VA, dyschromatopsia (mainly involving the blue-yellow spectrum), and exceptionally the development of bony spicules and/or subretinal neovascular membrane.<sup>(4,5)</sup>

However, the importance of this condition still lies in the differential diagnosis of other pathologies with expectation of worse vision, such as cone dystrophy, retinal toxicity by antimalarials, Stargardt's disease, and central aerolar choroidal atrophy.<sup>(1-6)</sup>

Inheritance is autosomal dominant with wide variability of clinical expression.<sup>(1,2)</sup> There is a possible association with mutations in the IMPG1 gene located on chromosome 6.<sup>(5,6)</sup>

The most typical finding of BCAMD is a concentric and bilateral atrophy of RPE around the fovea (1-6) manifesting in fluorescein angiography as a hyperfluorescent ring concentric to the macular region.<sup>(3,4,6)</sup>

The OCT in this condition has already been described by Burton et al.,<sup>(7)</sup> but their findings are nonspecific. Despite this, the patient in the case reported has a very similar pattern to the above, which corroborates his diagnosis and reaffirms this complementary examination as one of the tools to elucidate BCAMD.

The Full Field ERG tends to be normal as it is a macula-restricted disease.<sup>(3-6)</sup> Multifocal ERG would be more expressive in this case.

The visual field reflects the defect found in the funduscopy, evidencing annular scotoma corresponding to the ring of atrophy of the RPE surrounding the fovea. However, this ring pattern is not mandatory for the diagnosis, since the degree of macular lesion may be heterogeneous, revealing only paracentral defects also typical of BCAMD.<sup>(1,3,4)</sup>

Regarding autofluorescence in BCAMD, there are still no exclusive reports in the literature up to the present moment. Autofluorescence is a property of the retinal cells due to the production of lipofuscin in the external photoreceptor segments.<sup>(8)</sup> This metabolite is phagocytosed by RPE under normal conditions.<sup>(8)</sup> However, when there is a pathology involving the RPE-photoreceptor complex this process of metabolizing lipofuscin is impaired, causing its accumulation.<sup>(8)</sup> The more

lipofuscin, the greater the autofluorescence of the tissue.<sup>(8)</sup> However, with the progression of the involvement and consequent death of the photoreceptors, there is a reduction of the pigment, decreasing autofluorescence.<sup>(8)</sup> Therefore, it is possible to consider this test as a good marker of RPE integrity, being useful to evaluate the progression of retinal dystrophies.<sup>(8)</sup>

In the patient of the reported case, we found hypoauto fluorescence in concentric halo in the macular region translating a marked atrophy of the RPE in this area. This alteration can be justified by the age of the patient who is already at the end of the sixth decade of life, corroborating evidence that the disease presents a structural progression that may or may not correlate with the functional damages since there is no marked low vision in this case, despite the typical annular scotoma in CVF 60.2.

Thus, it is possible to consider the autofluorescence examination as another tool for the diagnosis and follow-up of BCAMD, which has few publications, as it is such a rare condition and thus still poorly understood.

## REFERENCES

1. Mendonça LS, Lavigne LC, Chaves LF, Garcia JM, Isaac DL, Ávila M. Benign concentric annular macular dystrophy. *Rev Bras Oftalmol.* 2015;74(3):183-5.
2. Deutman AF. Benign concentric annular macular dystrophy. *Am J Ophthalmol.* 1974;78(3):384-96.
3. Salinas Alamán A, Sádaba Echarri LM, Corcóstegui Crespo I, García Layana A. Benign concentric annular macular dystrophy. *Arch Soc Esp Oftalmol.* 2005;80(1):45-8.
4. Pérez Alvarez MJ, Clement Fernández F. Benign concentric annular macular dystrophy: two cases. *Arch Soc Esp Oftalmol.* 2003;78(8):451-4.
5. Van den Biesen PR, Deutman AF, Pinckers AJ. Evolution of benign concentric annular macular dystrophy. *Am J Ophthalmol.* 1985;100(1):73-8.
6. Gómez-Faiña P, Alarcón-Valero I, Buil Calvo JA, Calsina-Prat M, Martín-Moral D, Lillo-Sopena J, et al. Benign concentric annular macular dystrophy. *Arch Soc Esp Oftalmol.* 2007;82(6):373-6.
7. Burton BJ, Holder GE, Duguid G, Gregory-Evans K. Optical coherence tomography findings in benign concentric annular dystrophy. *Eye (Lond).* 2005;19(6):699-701.
8. Côco M, Baba NT, Sallum JM. Avaliação da autofluorescência do fundo de olho nas distrofias de retina com o aparelho Heidelberg Retina Angiograph2. *Arq Bras Oftalmol.* 2007;70(5):739-45.

---

### **Corresponding author:**

Maurício B. Pereira

R. Alberto de Sequeira, 59 – Tijuca – Rio de Janeiro - Brazil

ZIP Code:20260-160

E-mail: profmauricio@live.com