

# Visual rehabilitation with contact lenses after corneal keratoplasty

## *Reabilitação visual com lentes de contato após transplante de córnea*

Jamile Reimann Mendonça<sup>1</sup> <http://orcid.org/0000-0002-3148-2458>

Luiz Formentin<sup>1</sup> <http://orcid.org/0000-0001-9833-5455>

### ABSTRACT

Contact lens fitting after corneal transplantation has been considered a challenge in visual rehabilitation. There is currently the possibility of adapting contact lenses of various sizes, various designs and with different thicknesses and materials, such as gelatinous lenses, gas-permeable rigid corneal lenses, corneal-scleral lenses, mini-scleral and scleral lenses. The objective of this study was to present a review of current literature that may exemplify the use of some of the different types of contact lenses that can be used after corneal transplantation. An integrative review of the medical literature in the English language, using as a database for the research, Pubmed and Mendeley. Twenty six articles were selected, with year of publication between 2001 and 2018, as inclusion criterion, the relevance of articles according to the authors' experience was used. Five articles were selected that have as main subject corneal transplantation, nine articles on contact lenses in general, and 12 articles on scleral or mini scleral contact lenses. Due to the greater transmissibility of oxygen to the cornea, the use of rigid gas-permeable corneal lenses was shown to be safer and more likely to be used for a longer period of time.

**Keywords:** Corneal keratoplasty; Penetrating keratoplasty; Contact lens; Gas permeable rigid contact lenses; Scleral lens, Mini scleral lenses

### RESUMO

A adaptação de lentes de contato após o transplante de córnea tem sido considerada um desafio na reabilitação visual. Atualmente existe a possibilidade de adaptação de lentes de contato de vários tamanhos, diversos desenhos e com diferentes espessuras e materiais, como por exemplo lentes gelatinosas, lentes corneanas rígidas gás-permeáveis, lentes córneo-esclerais, mini esclerais e esclerais. O objetivo deste estudo foi apresentar uma revisão da literatura atual que possa exemplificar a utilização de alguns dos diferentes tipos de lentes de contato que possam ser usadas após o transplante de córnea. Foi realizada uma revisão integrativa da literatura médica na língua inglesa, utilizando como base de dados para a pesquisa, Pubmed e Mendeley. Como critério de inclusão, foi estabelecido a relevância do artigo de acordo com a experiência da equipe. Foram selecionados 26 artigos, com ano de publicação entre 2001 e 2018. Dentre os artigos selecionados, cinco possuem como principal assunto o transplante de córnea, nove artigos sobre lentes de contato em geral, e 12 artigos sobre lentes de contato esclerais ou mini esclerais. Devido a maior transmissibilidade de oxigênio para a córnea, o uso das lentes corneanas rígidas gás-permeáveis mostrou-se mais seguro e com probabilidade de uso por um período maior de tempo.

**Descritores:** Transplante de córnea; Transplante penetrante; Lentes de contato; Lentes de contato rígidas gás permeáveis; Lentes esclerais; Lentes mini esclerais

<sup>1</sup>Paulista Medical School. Federal University of São Paulo, São Paulo, SP, Brazil.

The authors declare no conflicts of interests.

Received for publication: 28/07/2019 - Received for publication: 10/01/2020.

## INTRODUCTION

Corneal keratoplasty has been carried out for more than 100 years to promote visual rehabilitation from a whole variety of corneal dystrophies and disorders. Corneal ectasias, mainly keratoconus, corneal scars (secondary trauma and infections), many kinds of keratopathies (herpes simplex keratitis and pseudophakic bullous keratopathy) and congenital corneal opacities like Peter's Anomaly are among corneal dystrophies and disorders recommended for corneal keratoplasty.<sup>(1)</sup>

Advancements in technical surgeries and measurement procedures have allowed most patients to have an optically feasible graft without opacity. However, despite such effectiveness, some patients can get an impaired visual function due to refractive issues such as anisometropia (spherical and astigmatic) and irregular astigmatism. Furthermore, contact lenses play an important role in improving the visual function of patients with the aforementioned refractive changes, although the selective suture removal and the adoption of refractive surgery after corneal keratopathy remain a resource available.<sup>(2)</sup>

### Aim

The aim of the present study was to carry out an integrative literature review in order to exemplify the possible application of some contact lens types after corneal keratopathy.

## METHODS

An international integrative literature review was performed; it included publications in English. The scientific evidence level observed in the articles was the adopted inclusion criterion. Time intervals for publications were not determined. Another inclusion criteria was article relevance based on the experience of the team. In total, 26 articles were selected to the study. Pubmed and Mendeley were the databases chosen for the research; the following meshes were selected for it: "Corneal Keratoplasty, Penetrating Keratoplasty, Contact Lens, Gas Permeable Rigid Contact Lenses, Scleral Lenses, Mini-scleral Lenses".

## RESULTS

The search led to 1,322 articles related to the selected meshes. Articles considered by the researchers to have the greatest coverage and relevance for the study were selected (26 articles). Among them, one finds 5 articles that had corneal keratopathy as main subject, 9 articles about overall contact lens and 12 articles about scleral contact lenses or mini-scleral contact lenses (Figures 1 and 2). Figure 3 depicts the scientific evidence level of articles selected for this literature review: 4 articles recording evidence level 4, and 9 articles with evidence level 5. One of the articles concerned a theoretical study (mathematical calculation) that has made the classification possible.

## DISCUSSION

### Corneal keratopathy

Keratoconus and corneal dystrophies were the main causes of recommendation for penetrating corneal transplantation in the study by Wietharn et al; they accounted for 37.1% and 28.6% of

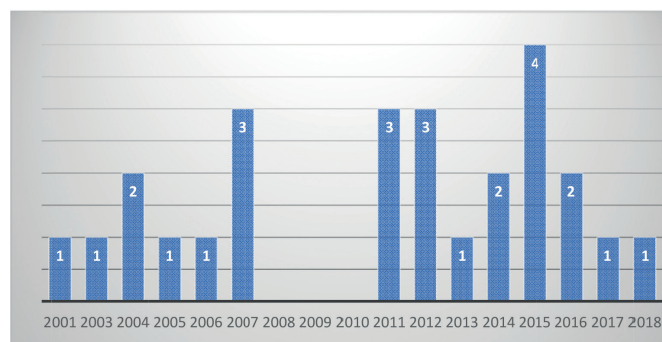


Figure 1: Articles distributed per publication year

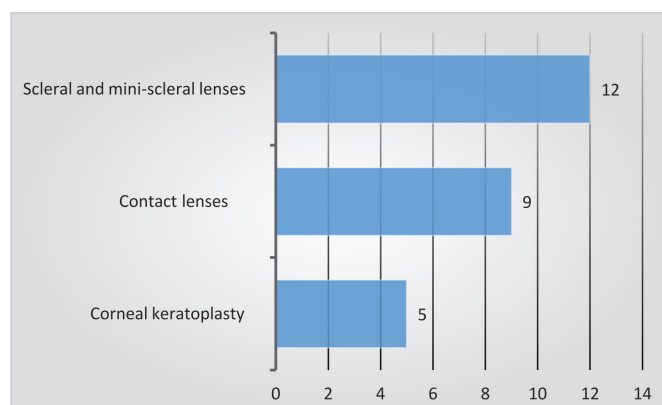


Figure 2: Articles distributed per subject

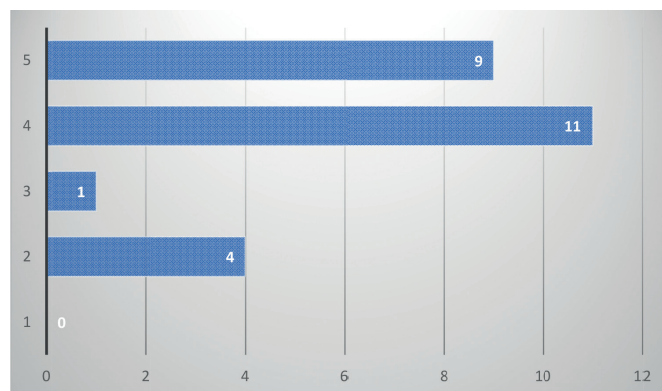


Figure 3: Articles divided per scientific evidence level

recommendation for corneal keratopathy, respectively.<sup>(2)</sup>

According to Kelly et al., keratoconus penetrating grafts recorded survival rates (in the first 15 years after the procedure) higher than grafts performed due to other recommendations; after this period, the survival rate appeared to disregard the recommendation. Rejection episodes in transplanted eyes due to keratoconus is a significant risk factor for transplantation failures. Although most rejection episodes happen right after the transplantation (90% of them take place in the first post-operative years), some of these episodes can be observed years later – the longest period for the first rejection was recorded 21 years after the surgery.<sup>(3)</sup>

Late graft failures in eyes transplanted through keratoconus were more often attributed to recurring unspecific causes, or to astigmatism, and less often attributed to rejection. Geographic

location (transplant center effect) was considered a risk factor for transplantation failure 15 years after surgery, or more. Risk rates in the worse center was seven times higher than in the best center. <sup>(3)</sup>

Normal cornea is avascular and the growth of new vessels – estimated through hypoxia related to the use of contact lenses presenting low oxygen transmissibility – can increase the risk of transplantation rejection. Transplant size has also been related to transplantation survival rates; oftentimes, graft diameter lies between 7.5 and 8.5 mm. Tiny (diameter smaller than 7mm) or big transplants (diameter bigger than 8.5mm) use to record survival rate lower than that of mid-sized transplants. <sup>(4)</sup>

Astigmatism is a particular issue for keratoconus transplantations; moreover, it can be the cause of late graft failures. Visual acuity in keratoconus patients can take many years to get stable; based on the study by (XXX), relatively stable visual acuity is not observed within a period shorter than 5 years after transplant evolution. <sup>(5)</sup>

Corneal retransplantation after graft failure (performed for keratoconus treatment) records survival rates lower than the first penetrating transplantation. The second transplantation, and subsequent transplantations, present significantly higher risk of failing when the previous corneal keratopathy records survival time shorter than 10 years. Graft failure within the first 10 years is associated with graft inflammation and rejection episodes, whereas failures observed after this period are more likely to be the result from non-inflammatory conditions. <sup>(5)</sup>

Sari et al. assessed a series of randomized prospective cases and found that new techniques such as DALK (deep anterior lamellar keratoplasty) have been gaining room since they preserve receptors' endothelium and rule out endothelial rejection risk, as well as, preserve endothelial cell density. The main concern with this technique lies on the occurrence of opacity and irregularities in the host-donor interface. The introduction of the technique known as “big bubble” to separate the corneal stroma-Descemet's membrane interface allowed the obtainment of transparent interfaces, which leads to better visual postoperative outcomes (visual acuity, refractions, sensitivity to contrast and high-order aberrations) similar to the ones obtained through corneal penetrating transplantations. <sup>(6)</sup> Similarly, Reinhart et al. also found corrected visual acuity and refractive errors after the conduction of DARK and corneal penetrating transplantation. <sup>(7)</sup>

Unfortunately, visual outcomes obtained through corneal keratopathy are not satisfactory in a significant part of patients. It is quite common founding four diopters, or more, of either regular or irregular astigmatism. Surgical alternatives to improve vision include re-suture, keratotomy for astigmatism correction (manual or femtosecond laser-assisted), corneal rings, toric intraocular lenses and refractive surgery. However, these procedures are not effective in, or acceptable by, many patients. <sup>(8)</sup>

In cases where astigmatism is regular, it is possible prescribing glasses, and the refractive surgery can be taken into consideration to reduce the amount of astigmatism. If the astigmatism is irregular, it is more likely to need rigid gas permeable contact lens adaptation in order to optimize visual acuity. Even toric soft lenses are not capable of neutralizing the irregular astigmatism. <sup>(4)</sup>

## Contact lenses

### Rigid gas permeable contact lens and soft lens

Based on the study conducted by Wietharn et al., all patients who had adapted to soft lens after the corneal transplantation

were not happy with the vision provided by the glasses. The stigmatism observed in 62.9% of the assessed eyes was the most common cause of adaptation to contact lens; it was followed by spherical anisometropia, which accounted for 57.1% of the eyes (it was defined as the difference of three, or more, diopters of the spherical equivalent between the two eyes); astigmatic anisometropia, which was found in 54.3% of the eyes (defined as the difference of at least two diopters in the total astigmatism between the two eyes); and finally, aphakic eyes, which was observed in 8.6% of the assessed eyes as a factor contributing to anisometropia. <sup>(2)</sup>

Constant lenses are the optical correction of choice for anisometropia cases because they help reducing image magnification, which often happens due to the use of glasses. The following rule can be applied to access the binocular function without aniseikonia symptoms: 1.5% magnification for each diopter difference between the two eyes. It is likely that aniseikonia would be intolerable if the difference in the image was higher than 5%, so, it would not be recommended for contact-lens use prescription. <sup>(4)</sup>

Large diameter rigid gas permeable lenses would be recommended if the residual astigmatism was lower than four diopters; the lens must have diameter smaller than the donor's button graft. Soft lenses could be an option for visual correction if the astigmatism was below one diopter. <sup>(9)</sup>

Corneal topography must guide constant lens adaptation in order to select the best design for the posterior surface of the lens. Based on video keratotomy, there are five classical types of corneal profile described after keratoplasty: prolate shape (regular astigmatism with central red bow tie pattern, which highlights a more curved central region and the most plane periphery), oblate shape (regular astigmatism with central blue bow tie shape, with a more plane central region and a more curved periphery), mixed shape (regular astigmatism - it goes all the way through the topographic map), asymmetric shape (with two more curved hemimeridians, non-asymmetric to each other, and/or out of the 180°), plane curve pattern (when the cornea is more curved in one side, which becomes progressively more plane in the opposite side). <sup>(4)</sup>

According to Lagnado et al., approximately 30% of the post-penetrating-transplantation eyes have corneal shape classified as plane or oblate, i.e., plane cornea. <sup>(10)</sup>

The approach applied to rigid gas permeable contact lenses (RGP) adaptation after corneal keratopathy concerns multi-curved lens use and, oftentimes, the use of large diameter lens, in order to improve lens' stability. Traditional multi-curved lenses (tinier center, with progressively wider periphery) are not likely to have good adaptation to plane grafts. The expected result is to have excessive central deliverance, although peripheral adaptation can be considered satisfactory. Multi-curved lenses - added with a second more sloped curve to its design than the posterior central curve - were firstly recommended by orthokeratology. Recently, these lenses started to be applied to post refractive surgery and to post corneal penetrating transplantation. <sup>(10)</sup>

Lenses presenting rigid reverse geometry design have one, or more, peripheral curves that are tighter than the posterior central curve. The second curve is the tightest one in most reverse geometry lenses (they have narrower radius). These lenses are ideally adapted to oblate corneas (centrally plane and more curved in the periphery), similarly to cornea subjected to refractive surgery (such as radial keratotomy, laser keratomileusis in situ) for myopia reduction. <sup>(4)</sup>

Lenses with design based on toric posterior curve, or bitoric design lenses are the choice for regular astigmatism that goes

from the graft's central region to its periphery because they can have improved adaptation and correct residual astigmatism. (11)

According to Phan et al., RGP lenses with bitoric design demand longer adaptation time and closer care by the health professional than spherical RGP lenses. However, a larger number of complications is associated with corneal spherical RGP lenses in comparison to corneal bitoric RGP lenses. It is likely so, because there is best alignment between the cornea and bitoric RGP lenses after the transplantation. Keratometric astigmatism patients can be the most benefited ones from bitoric RGP lenses adaptation. (12)

The posterior surface of the lens is the most important one to improve lens accommodation on the cornea; thus, the posterior toric face provides more comfort and lower complication indices when the graft's surface after the transplantation is considerably toric. On the other hand, the need of having, or not, an anterior toric surface – which features a bitoric lens – will depend on overcooling showing reduced or induced astigmatism. In case of induced astigmatism, the use of safety material can be appropriate to bitoric lenses, mainly when it comes to refraction index.

Leal et al. conducted a comparative study between hybrid material contact lenses (HM) - with flexible polymers - and rigid gas permeable contact lenses in patients with compound myopic astigmatism and keratoconus. Although the hybrid material combined the optical skills of the rigid gas permeable material to the qualities of the soft material, visual performance and comfort outcomes were similar and did not differ from results recorded for rigid gas permeable contact lenses. (13)

The “piggyback” system, which adapts to a soft contact lens covered by a rigid contact lens, can be necessary when the rigid contact lens can damage the cornea due to relevant post corneal transplantation irregularities observed on the topography. The use of soft lenses under the rigid lenses protects the cornea from excessive touches and minimizes the possibility of developing complications resulting from corneal rigid lens use. The “piggyback” system leads to good centralization and comfort. A material containing high water amount should be used in soft contact lenses, and a highly gas permeable material should be applied to rigid lens in order to improve oxygen transmissibility in this system. It is important emphasizing the need of providing extra care to lens adaptation at the post-transplantation period, because corneal central sensitivity gets quite reduced at this point; therefore, patients may not feel the discomfort caused by corneal friction or by other forms of corneal impairments. (4)

Giasson et al. conducted a study about the “piggyback” system based on measuring the equivalent oxygen percentage and on the research of corneal edema related to “piggyback” system use. They concluded that the combination of selected corneal RGP and soft lenses does not induce corneal hypoxia. (14)

The comparison between hydrophilic soft contact lenses to rigid gas permeable lenses has been showing its association with higher complication rates; they are less used than RGP lenses, which are more permeable to oxygen and have more rigid surface and are more resistant to flexion (they provide better correction to astigmatism); therefore, they are often more adapted than the hydrophilic soft contact lenses. (2) The use of hydrogel lens incorporated to the contact lens corrects high astigmatism, makes the lens thicker and reduces oxygen transmissibility. This process can lead to corneal ischemia and, consequently, to increased risk of transplantation rejection. (1)

According to the retrospective study conducted by Geerards

et al., the adaptation of large diameter RGP curved contact lenses (12mm) was successful in 90 patients (47%) of the 190 transplanted ones. Lens adaptation was recommended for patients with at least three after surgery who present visual acuity worse than 20/50, even in the presence of suture or topical measurement. Large diameter lenses divide the pressure made over the cornea between the peripheral cornea (receptor cornea) and the graft (donator cornea), which improves comfort and visual acuity. According to the aforementioned authors, great-diameter rigid gas permeable lenses and highly gas-permeable lenses (highly oxygen permeability) are good choices for transplanted eyes, since they are well-tolerated. Semi-scleral lenses are good second options if one takes into consideration their high price. In cases of extremely high astigmatism, these authors recommend the use of scleral lenses. (15)

### Scleral and Mini-scleral lenses

Based on the classification of lens according to lens size, mini-scleral lenses have diameter ranging from 15 to 18 mm, and the diameter of scleral lenses is bigger than 18 mm (more than 6mm of them touch the sclera) (16).

Alipour et al. used mini-scleral lenses in patients who did not reach visual acuity, not even with glasses, or with the use of RGP contact lenses (9.3 to 11mm diameter). Mini-scleral lenses have the potential to hold the whole cornea and the ability to correct refractive mistakes and high-order aberrations caused by unevenness on the anterior surface of the cornea, even at challenging situations such as in case of patients presenting advanced keratoconus, patients with corneal ring or penetrating post-transplantation. The adaptation of these lens is relatively easy due to their great diameter (15 to 18mm), they have good concentration and their use is oftentimes well-tolerated. (8)

Transplanted patients who were adapted to mini-scleral lenses reached superior corrected visual acuity due to the use of glasses. This outcome may derive from the high degree of irregular astigmatism observed in the assessed cases. (8)

Nowadays, scleral lenses also have application in transplanted patients; they started to be clinically used by Fick and Muller in 1880, and were made of glass at that time; subsequently, they started to be made of polymethylmethacrylate (PMMA). In 1983, Ezekiel improved the use of these lenses after making them with gas permeable material, which made them more tolerable and, consequently, they led to better outcomes. (17) Gas permeable material introduction in scleral lenses' production allowed a longer time of use due to better corneal oxygenation and to the lower probability of developing corneal edema, in comparison to PMMA lenses.

Gas-permeable material development associated with technological innovations in designs for scleral lens production has opened new perspectives for the use of these lenses. Four types of scleral lenses emerged from this process, namely: spherical lenses, lenses with toric anterior surface, lenses with toric periphery, and lenses with simultaneous toric periphery and toric anterior surface. (8)

Visser et al. adapted scleral lenses presenting total diameter between 18 and 25 mm. (18) The main recommendations for scleral lenses adaptation were keratoconus in 143 eyes (50.4%) and penetrating keratoplasty in 56 eyes (19.7%), primary or secondary irregular astigmatism in 36 eyes (12.7%), sicca keratoconjunctivitis in 15 eyes (5.3%), corneal dystrophy in 10 eyes (3.5%)

and multiple diagnoses in 24 eyes (8.5%). This same study used the four aforementioned designs and found the ratio of 1:1.1 in lenses without toric periphery (spherical lenses and lenses with toric anterior face) and in lenses with toric periphery (lenses with toric periphery and with simultaneous toric periphery and toric anterior face).<sup>(17)</sup> This ratio goes against the experience of the aforementioned authors, according to whom, most eye bulbs are toric. Unfortunately, it was not possible taking bulb topographic measurements in the current study.<sup>(18)</sup>

According to Severinsky et al., the visual acuity deriving from scleral lenses was significantly better than that obtained with glasses; it was defined as a two lines gain, or more – this outcome was observed in 94% of patients. According to the Snellen table, 82% of patients reached visual acuity of 0.5, or even better visual acuity than that.<sup>(1)</sup> Barnett et al., found that the best corrected visual acuity was 20/20, or better, in 39.6% of patients in their study about scleral and mini-scleral lenses after penetrating transplantation. Approximately 91.7% of eyes reached visual acuity of 20/40, or better.<sup>(19)</sup>

### Time of use recommended for scleral and mini-scleral lenses

With respect to scleral lenses in the study by Severinsky et al., the mean time of use recommended for scleral lenses after the transplantation was 11.8 hours a day; use interval should be of one day. Tear exchange under the lens throughout the day also gets reduced by lens “sealing”, and it can expose the cornea to toxic substances that lie between the lens and the cornea. Pre-corneal fluid stagnation can cause severe epithelial keratopathy. On the other hand, tear aspiration under the edges of the lens has been associated with increased oxygen transportation to the cornea, as well as with adaptation success and longer lens-use time.<sup>(1)</sup> Alipur et al., reported that the mean lens-use time was of almost 10 h a day in their study with mini-scleral lenses after penetrating transplantation and post-DALK.<sup>(8)</sup>

According to Visser et al., almost half of patients (approximately 48.9%) removed and replaced the lenses throughout the day-use period.<sup>(17)</sup> Similarly, Schornack (2005) conducted a literature review and mentioned that patients who have systematically removed, washed, fulfilled and replaced the lenses throughout the day were statistically more prone to be successful with their scleral lenses use than the ones who did not follow these procedures.<sup>(20)</sup>

### Complications from, and abandonment of, scleral and mini-scleral lens use

Based on the study about scleral lenses conducted by Severinsky et al., approximately 10 eyes (305) of the 31 adapted eyes recorded at least one graft rejection episode; 8 of them were clinically successfully treated and the other two evolved to corneal decompensation - shorter contact lenses-use was recommended. Two patients (6%) had microbial keratitis episodes likely related to bad lens-use by the patients themselves. Approximately 6% of patients has presented recurrent transitory corneal edema episodes; edema tends to emerge when the oxygen level is below the required minimal rate for normal corneal oxygenation – this hypoxia condition can benefit from the use of lenses throughout the day (non-stopping use). The other mentioned complications are erosion and corneal compression caused by recurrent ectasia.<sup>(1)</sup>

The corneal rejection rate after penetrating transplantation ranges from 13% to 35% in the literature.<sup>(19)</sup> Felipe et al. fou-

nd transplantation rejection rate of 30%, with 5% to 7% graft failure.<sup>(21)</sup>

Barnett et al., have found that approximately 6 eyes (12.5%) developed transplantation rejection in their study with scleral and mini-scleral lenses, but they did not find any case of infectious keratitis. Only one of the transplantation rejection cases has evolved to graft failure; it was observed in one eye that had history of bad outcomes due to epithelial impairment and that had already been subjected to tarsorrhaphy after the initial transplantation.<sup>(19)</sup>

Michaud et al. conducted a study whose theoretical calculation was adopted to predict oxygen transmissibility in scleral lenses' use, based on the corneal demand for oxygen and on the use of different combinations of scleral lenses to different tear film layer thicknesses. This study has shown that most scleral adaptations carried out nowadays could be associated with some degree of corneal edema induced by hypoxia. Lens made of a material presenting more DK available, designed with maximal central thickness of 250 250  $\mu\text{m}$  and adapted in such fashion that the tear film posterior to the lens would not exceed 200  $\mu\text{m}$  (space between the lens and the cornea) would be the best combination of scleral lenses to tear film layer thickness in order to avoid the corneal edema of the central cornea. Lens thickness could lie between 250 and 350  $\mu\text{m}$  in the corneal periphery, with tear film layer posterior to the lens ranging between 10 and 60  $\mu\text{m}$ . The same study mentions that it is better using smaller lens (12-15mm), since they have reduced central thickness and can be adapted to a tear film layer posterior to the smaller lens (narrower gap between the lens and the cornea) in comparison to greater-diameter lenses (bigger than 15mm). Smaller lens can also favor better tear exchange under the lens.<sup>(22)</sup>

Authors in this same study state that D represents the coefficient of diffusion in DK/t, as well as that (K) is oxygen solubility and (t) is lens thickness. These authors used theoretical calculations to estimate oxygen transmissibility in scleral lenses. Lens central thickness of 250 and 500  $\mu\text{m}$ , with vault (corneal release) between 100 and 400  $\mu\text{m}$  – lenses with DK of 100, 150 and 170 – were used in the calculation. Oxygen transmissibility achieved through the use of scleral lenses with DK of 100 ranged from 10 to 26.7 DK/t, from 12.0 to 34.3 DK/t in lens with DK of 150 and from 12.6 to 36.7 DK/t in lens with DK 170.<sup>(22)</sup>

Bergmanson et al., reported the importance of tear film mix under the scleral, haptic and corneal portion of scleral lenses (tear film mix under the lens) to provide enough oxygen to the cornea.

Mini-scleral lenses are quite beneficial, smaller scleral lenses can be thinner, need a smaller vault (gap between the lens and the cornea) and avoid interaction with asymmetric sclera. With respect to lens thickness, mini-scleral lenses can be thinner than the bigger scleral ones because lens rigidity is better at smaller diameters. Therefore, these lenses can provide a superior DK/t to the cornea. In cases where the corneal endothelium is as compromised as the transplanted cornea, it is necessary having more oxygen, which would be possible to be achieved by smaller and thinner lenses.<sup>(24)</sup>

Guillon et al. described the occurrence of transplantation rejection and corneal edema, even when high-Dk mini-scleral lenses were used.<sup>(25)</sup>

Assumingly, a high Dk, alone, does not assure good oxygen transmissibility, because transmissibility also depends on lens thickness and on the tear layer set between the lens and the cornea.

Limbal cells play an important role in the renovation and proliferation of the corneal epithelium; it is prudent avoiding

limbal epithelium disturbances, as well as prominent touches in this region, which presents great sensorial-nerve density – it could cause discomfort.<sup>(26)</sup> Subepithelial fibrosis has been documented to happen in the touch area of the lens on the graft/host interface in transplanted patients.<sup>(1)</sup>

Alipur et al. assessed the use of mini-scleral lenses after penetrating transplantation and DALK and reported that less than half of patients in their study had requested the lenses, and a smaller percentage of them (25%) kept on using the lenses – this percentage is smaller than that reported for other centers. Economic issues (patients could not pay for the lenses and assurance companies did not cover their acquisition), hard time handling the lenses and work conditions (contamination likelihood in unsafe work sectors) were the main reasons for not ordering the lenses.<sup>(8)</sup>

According to the study by Barnett et al. about scleral and mini-scleral lenses after penetrating transplantations, the main cause of non-adherence to scleral lens-use lies on the hard time putting them on and removing them. Dissatisfaction with the vision, scleral lens-related discomfort and transplantation rejection were other causes of non-adherence to these lens' use.<sup>(19)</sup>

Great diameter lenses like the scleral ones, can be an option for hard adaptation such as in the case of post corneal transplantation; however, this may not be the best option for all patients, mainly for the ones presenting low endothelium cell counting or history of corneal edema.<sup>(12)</sup>

Corneal RGP lenses are the first option for post-transplantation cases if one considers that they present better oxygen transmissibility; however, these lenses become inappropriate for decentralization, intolerance or exacerbated touch cases, which can cause localized erosion. In these cases, mini-scleral or scleral lenses have better rehabilitation indications, within a limited time of use.

If one takes into account differences characteristic of corneal, corneal-scleral and scleral lenses, as well as the potential difference between mini-scleral and scleral lenses, it is not possible assuming that all of these lenses affect the anterior segment of the eye in the same way. Lens thickness and the thickness of the tear fluid posterior to the scleral lens can represent an important barrier to oxygen transmissibility and lead to hypoxia-related complications. It is possible being confident that the risk of inaction or of surgical intervention in patients with little disease-management options overcomes the potential risk of using scleral lenses, but the exact location of the scleral lenses inside the whole management strategy is yet to be defined.<sup>(20)</sup>

## CONCLUSION

Contact lenses adaptation is a visual and therapeutic resource to correct post corneal keratoplasty refractive errors, such as, spherical and astigmatic anisometropias, and regular and irregular corneal astigmatisms. Each case must be analyzed in separate at the time to choose the best lenses, because they must respect the ocular physiology and corneal surface of the patient. Based on the present literature review, it is essential choosing the adaptation of contact lenses presenting the following features: High DK, smaller thickness and adequate diameter – together these features must allow good oxygen transmissibility to the cornea and respect corneal surface.

Nowadays, it is possible adapting varied-sized contact lenses, with different designs, thicknesses and materials. The safer use of gas

permeable rigid corneal lenses for longer periods-of-time proved to be possible due to the improved oxygen transmissibility to the cornea.

## REFERENCES

1. Severinsky B, Behrman S, Frucht-Pery J, Solomon A. Scleral contact lenses for visual rehabilitation after penetrating keratoplasty: long term outcomes. *Cont Lens Anterior Eye*. 2014;37(3):196–202.
2. Wietharn BE, Driebe WT Jr. Fitting contact lenses for visual rehabilitation after penetrating keratoplasty. *Eye Contact Lens*. 2004;30(1):31–3.
3. Kelly TL, Williams KA, Coster DJ; Australian Corneal Graft Registry. Corneal transplantation for keratoconus: a registry study. *Arch Ophthalmol*. 2011;129(6):691–7.
4. Szcotka LB, Lindsay RG. Contact lens fitting following corneal graft surgery. *Clin Exp Optom*. 2003;86(4):244–9.
5. Kelly TL, Coster DJ, Williams KA. Repeat penetrating corneal transplantation in patients with keratoconus. *Ophthalmology*. 2011;118(8):1538–42.
6. Söütlü Sari E, Kubalo lu A, Ünal M, Piñero Llorens D, Koytak A, Oflu lu AN, et al. Penetrating keratoplasty versus deep anterior lamellar keratoplasty: comparison of optical and visual quality outcomes. *Br J Ophthalmol*. 2012;96(8):1063–7.
7. Reinhart WJ, Musch DC, Jacobs DS, Lee WB, Kaufman SC, Shtein RM. Deep anterior lamellar keratoplasty as an alternative to penetrating keratoplasty a report by the american academy of ophthalmology. *Ophthalmology*. 2011;118(1):209–18.
8. Alipour F, Behrouz MJ, Samet B. Mini-scleral lenses in the visual rehabilitation of patients after penetrating keratoplasty and deep lamellar anterior keratoplasty. *Cont Lens Anterior Eye*. 2015;38(1):54–8.
9. Ozkurt Y, Atakan M, Gencaga T, Akkaya S. Contact lens visual rehabilitation in keratoconus and corneal keratoplasty. *J Ophthalmol*. 2012;2012:832070.
10. Lagnado R, Rubinstein MP, Maharajan S, Dua HS. Management options for the flat corneal graft. *Cont Lens Anterior Eye*. 2004;27(1):27–31.
11. Gruenauer-Kloevekorn C, Kloevekorn-Fischer U, Duncker GI. Contact lenses and special back surface design after penetrating keratoplasty to improve contact lens fit and visual outcome. *Br J Ophthalmol*. 2005;89(12):1601–8.
12. Phan VA, Kim YH, Yang C, Weissman BA. Bitoric rigid gas permeable contact lenses in the optical management of penetrating keratoplasty. *Cont Lens Anterior Eye*. 2014;37(1):16–9.
13. Leal F, Lipener C, Chalita MR, Uras R, Campos M, Höfling-Lima AL. Lente de contato de material híbrido em pacientes com ceratocone e astigmatismo miópico composto. *Arq Bras Oftalmol*. 2007;70(2):247–54.
14. Giasson CJ, Perreault N, Brazeau D. Oxygen tension beneath piggyback contact lenses and clinical outcomes of users. *CLAO J*. 2001;27(3):144–50.
15. Geerards AJ, Vreugdenhil W, Khazen A. Incidence of rigid gas-permeable contact lens wear after keratoplasty for keratoconus. *Eye Contact Lens*. 2006;32(4):207–10.
16. Rathi VM, Mandathara PS, Taneja M, Dumpati S, Sangwan VS. Scleral lens for keratoconus: technology update. *Clin Ophthalmol*. 2015;9:2013–8.
17. Visser ES, Visser R, van Lier HJ, Otten HM. Modern scleral lenses part II: patient satisfaction. *Eye Contact Lens*. 2007;33(1):21–5.
18. Visser ES, Visser R, van Lier HJ, Otten HM. Modern scleral lenses part I: clinical features. *Eye Contact Lens*. 2007;33(1):13–20.
19. Barnett M, Lien V, Li JY, Durbin-Johnson B, Mannis MJ. Use of scleral lenses and miniscleral lenses after penetrating keratoplasty. *Eye Contact Lens*. 2016;42(3):185–9.

20. Schornack MM. Scleral lenses: a literature review. *Eye Contact Lens*. 2015;41(1):3–11.
21. Felipe AF, Hammersmith KM, Nottage JM, Rapuano CJ, Nagra PK, Cohen EJ, et al. Indications, visual outcome, and ectasia in clear corneal transplants 20 years old or more. *Cornea*. 2013;32(5):602–7.
22. Michaud L, van der Worp E, Brazeau D, Warde R, Giasson CJ. Predicting estimates of oxygen transmissibility for scleral lenses. *Cont Lens Anterior Eye*. 2012;35(6):266–71.
23. Bergmanson JP, Ezekiel DF, van der Worp E. Scleral contact lenses and hypoxia: theory versus practice. *Cont Lens Anterior Eye*. 2015;38(3):145–7.
24. Fadel D. Modern scleral lenses: mini versus large. *Cont Lens Anterior Eye*. 2017;40(4):200–7.
25. Guillon NC, Godfrey A, Hammond DS. Contact Lens and Anterior Eye Corneal oedema in a unilateral corneal graft patient induced by high Dk mini-scleral contact lens. *Cont Lens Anterior Eye*. 2018;(5):468–62.
26. Walker MK, Bergmanson JP, Miller WL, Marsack JD, Johnson LA. Complications and fitting challenges associated with scleral contact lenses: A review. *Cont Lens Anterior Eye*. 2016;39(2):88–96.

---

**Corresponding author:**

Jamile Reimann Mendonça – Rua Botucatu n. 822 Vila Clementino, São Paulo, SP – Brasil CEP 04023-062.

E-mail: jamile.mendonca@hc.ufpr.br