

# Unilateral third nerve palsy after use of oral Metronidazole

## *Paresia unilateral do terceiro nervo após uso de Metronidazol oral*

Mauro César Gobira Guimarães Filho<sup>1</sup> <https://orcid.org/0000-0002-0483-8789>

Mauro César Gobira Guimarães<sup>2</sup> <https://orcid.org/0000-0003-2995-7351>

João Pedro Rodrigues Braga<sup>1</sup> <https://orcid.org/0000-0002-7635-8071>

Deborah Cristina da Silva Cardoso<sup>1</sup> <https://orcid.org/0000-0002-2120-6601>

Diêgo Alves Feitosa<sup>1</sup> <https://orcid.org/0000-0003-0662-8803>

### ABSTRACT

*Female patient, 19 years old, with a complaint of diplopia, nausea and vomiting of sudden onset. Upon physical examination, the patient presented herself with the head position rotated to the left and limitation of adduction of the right eye, suggesting paresis of the medial rectus muscle. Absence of palpebral ptosis or paresis of other extrinsic musculature of the eye, and without other alterations in the ophthalmological evaluation. It was reported by the patient the use of Metronidazole, two doses of 500 mg, the same day the symptoms started. The magnetic resonance imaging of the skull was requested. The result showed a cyst of the pineal gland, the other aspects being within normality. The paresis of the medial rectus muscle and diplopia persisted for 14 days, even after the antibiotic was discontinued, thus opting to initiate oral corticosteroid therapy, evolving with good clinical response, improvement of symptoms and regression of muscular paresis.*

**Keywords:** Metronidazole/adverse effects; Metronidazole/toxicity; Third nerve palsy; Diplopia

### RESUMO

Paciente do sexo feminino, 19 anos, com queixa de diplopia, náusea e vômito de início súbito. Ao exame físico, a paciente apresentava rotação da cabeça para a esquerda e limitação da adução do olho direito, sugerindo paresia do músculo reto medial. Ausência de ptose palpebral ou paresia de outra musculatura ocular extrínseca e sem outras alterações na avaliação oftalmológica. Foi relatado pelo paciente o uso de Metronidazol, duas doses de 500 mg, no mesmo dia em que os sintomas começaram. A ressonância magnética do crânio foi solicitada. O resultado mostrou um cisto da glândula pineal, estando os outros aspectos dentro da normalidade. A paresia do músculo reto medial e diplopia persistiram por 14 dias, mesmo após a suspensão do antibiótico, optando, assim, por iniciar a corticoterapia oral, evoluindo com boa resposta clínica, melhora dos sintomas e regressão da paresia muscular.

**Descritores:** Metronidazol/efeitos adversos; Metronidazol/toxicidade; Paralisia do terceiro nervo; Diplopia

<sup>1</sup>Belo Horizonte University Center, Belo Horizonte, MG, Brazil.

<sup>2</sup>Ophthalmology Specialized Center, Teófilo Otoni, Teófilo Otoni, MG, Brasil.

Institution: Belo Horizonte University Center, Belo Horizonte, MG, Brazil.

**The authors declare no conflict of interest**

Received for publication 20/5/2019 - Accepted for publication 11/10/2019.

## INTRODUCTION

**M**etronidazole is a nitroimidazole widely used against anaerobic bacteria and some protozoa types. It is a pro-drug that releases cytotoxic free radicals to the nucleic acid structure of microorganisms whenever it is reduced by enzyme nitro-reductase. The DNA helicoid structure is destabilized in the nucleic acid structure leading to protein-synthesis inhibition. Metronidazole is a good option to treat gastrointestinal infections (such as amebiasis or giardiasis), gynecological infections, pseudomembranous colitis by *Clostridium*, *Helicobacter pylori* infection, colon preparation, among others.<sup>(1)</sup>

Gastrointestinal, psychiatric, neurological and visual disorders are some of the possible effects of Metronidazole. Neuro-ophthalmological toxicity, including paresis of the extraocular muscles and diplopia, can occur in very rare cases. The aim of the current study is to report a rare case of partial oculomotor nerve palsy (III cranial nerve) after the oral administration of metronidazole.

### Case Report

Female patient, aged 19 years, melanodermic, from the countryside presented to outpatient assistance claiming sudden diplopia, nausea and vomiting. Examinations have revealed head position tilted to the left and limited adduction of the right eye, suggesting paresis of the medial rectus muscle (Figure 1). Isochoric and photoreactive pupils were observed in both eyes. There was no eyelid ptosis or paresis of other extrinsic muscles of the eye. Intraocular pressure of 16 mmHg was recorded for both eyes, as well as 20/20 flat static refraction. Biomicroscopy revealed transparent and clear cornea and no anterior chamber reaction in both eyes. Computerized campimetry showed preserved foveal sensitivity and absence of scotomas in both eyes. Optical coherence tomography with preserved retinal thickness and architecture, normal retina-RPE complex in both eyes. Retinography displayed transparent vitreous, colored optic disc with sharp edges, well-pigmented macula, reflex and periphery without abnormalities in both eyes. The patient reported to had taken two doses of Metronidazole (500mg, each) in the same day the symptoms had started to treat an intestinal parasitosis. She was subjected to magnetic resonance imaging of the skull,





which depicted a cyst in the pineal gland; all other aspects were within normality. HIV, syphilis and toxoplasmosis examinations recorded negative results. CBC and ERS did not show any change. Paresis of the medial rectus muscle and diplopia lasted 14 days, even after the antibiotic was suspended. Therefore, the patient was referred to empirical oral corticotherapy and reported good evolution in clinical responses, symptom alleviation and muscle paresis regression (Figure 2)

## DISCUSSION



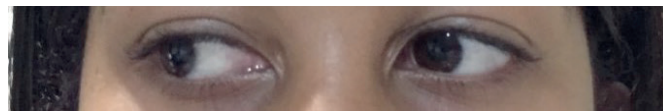

Neuro-ophthalmologic toxicity induced by the metronidazole administration is rare; it can lead to temporary visual alterations, such as diplopia, blurred vision, decreased visual acuity and optic neuropathy. There are no reports in the literature about patients who had function changes in the medial rectus muscle due to metronidazole administration; however, there are rare reports about diplopia related to the use of this medication. The current case has reported diplopia, nausea, vomiting and paresis of the extrinsic ocular musculature (medial rectus muscle) since the first day of Metronidazole therapy, a fact that adds peculiarity to the case.

The physiopathology of the neurotoxic effect of Metronidazole is not fully known, although some theories point out the involvement of cytotoxic edema, vasogenic edema and de-energization of axons in it due to metabolites. Evidences have shown no association among treatment dosage, duration and neurotoxic effects, which can change from individual to individual.<sup>(2)</sup> Diagnosis is performed based on the correlation between clinical history and the exclusion of other causes, although magnetic resonance imaging of the skull can show any change in most neurotoxicity cases caused by metronidazole administration. The presence of partial lesion in the third cranial nerve, which is difficult to notice in imaging examinations, is another peculiarity of the reported case.

According to the literature, treatment of the side effects of metronidazole consists of interrupting the medicine therapy and providing supportive care.<sup>(3)</sup> The choice for corticotherapy made in the present study lied on the fact that symptoms (diplopia and paresis of the medial rectus muscle) lasted longer than 10 days after medication suspension. Corticosteroids were empirically



**Figure 1:** Paresis of medial rectus muscle



**Figure 2:** Regression of muscle paresis

administered since this procedure is not recommended in the literature. However, there seems to be a link between the pathophysiology of this disease and its anti-inflammatory effect of decreasing vascular permeability.<sup>(4,5)</sup> It is important highlighting the patient's significant clinical evolution after corticotherapy prescription, given the full alleviation of symptoms after few days.

### CONCLUSION

The current case study reported acquired paresis of the medial rectus muscle, diplopia and nausea episodes after Metronidazole administration - according to the literature, this is an extremely rare condition. It is not possible defining the direct link between the use of corticosteroids and patient's improvement, because it is common observing spontaneous improvement in neurotoxicity. Further studies are needed in order to determine the efficiency of corticosteroids in cases of adverse effects refractory to Metronidazole suspension.

### REFERENCES

1. Dingsdag S, Hunter N. Metronidazole: an update on metabolism, structure-cytotoxicity and resistance mechanisms. *J Antimicrobial Chemother.* 2017; 73(2):265-79.
2. Kuriyama, A., Jackson, J., Doi, A. and Kamiya, T. (2011). Metronidazole-Induced Central Nervous System Toxicity. *Clin Neuropharmacol.* 2011; 34(6): 241-7.
3. Bouraoui R, Limaïem R, Bouladi M, Mghaieth F, El Matri L. (2016). Effets secondaires neuro-ophtalmologiques du traitement par métronidazole chez l'enfant : à propos de deux cas. *Arch Pédiatrie.* 2016; 23(2):167-70.
4. Bahn Y, Kim E, Park C, Park HC. Metronidazole induced encephalopathy in a patient with brain abscess. *J Korean Neurosurg Soc.* 2010;48(3):301-4.
5. Kim E, Na DG, Kim EY, Kim JH, Son KR, Chang KH. MR imaging of metronidazole-induced encephalopathy: lesion distribution and diffusion-weighted imaging findings. *AJNR Am J Neuroradiol.* 2007;28(9):1652-8.

---

#### **Corresponding Author:**

Mauro César Gobira Guimarães Filho  
Rua Antônio Alves Benjamin, 18, Teófilo Otoni, MG,  
CEP 39800-021, Brasil.  
E-mail: maurofilho5@hotmail.com  
Telephone: 5533988033404