

Bilateral tractional retinal detachment in hemoglobin SC disease patient

Descolamento tracional de retina bilateral em hemoglobinopatia S-C

Marina Malheiro Cruz¹ , Aline Cristina Fioravanti Lui¹ ¹Complexo Hospitalar Padre Bento de Guarulhos, São Paulo, SP, Brazil.

How to cite:

Cruz MM, Lui AC. Bilateral tractional retinal detachment in hemoglobin SC disease patient. Rev Bras Oftalmol. 2024;83:e0010.

doi:

<https://doi.org/10.37039/1982.8551.20240010>

Keywords:

Hemoglobin SC disease; Retinal detachment; Retinal diseases

Descritores:

Doença da hemoglobina SC; Descolamento de retina; Doenças retinianas

Received on:

Jul 5, 2023

Accepted on:

Nov 30, 2023

Corresponding author:

Marina Malheiro Cruz
Avenida Emílio Ribas, 1.819 – Gopouva
07051-000 – Guarulhos, SP, Brazil
E-mail: marina_malheiro@hotmail.com.

Institution:

Complexo Hospitalar Padre Bento de
Guarulhos, Guarulhos, SP, Brazil.

Conflict of interest:

no conflict of interest.

Financial support:

no financial support.

This paper was presented at *Congresso Brasileiro de Oftalmologia* (CBO), Annual Meeting, in 2022, Curitiba (PR).

Copyright ©2024

ABSTRACT

A 36-year-old black male presented with a progressive loss of visual acuity in both eyes for 7 years. He had a history of tractional retinal detachment in the right eye and vitreous hemorrhage followed by retinal detachment in the left eye. He denied any systemic illness, trauma, or drug abuse. After clinical investigation, he was diagnosed with SC hemoglobinopathy and proliferative sickle cell retinopathy stage V in both eyes.

RESUMO

Paciente do sexo masculino, 36 anos, negro, apresentou baixa acuidade visual progressiva em ambos os olhos por 7 anos. Possuía antecedentes de descolamento tracional de retina no olho direito e hemorragia vítrea, seguida de descolamento de retina no olho esquerdo. Negava doenças sistêmicas, trauma ou abuso de drogas. Após investigação clínica, foi diagnosticado com hemoglobinopatia S-C e retinopatia falciforme proliferativa estágio V em ambos os olhos.

INTRODUCTION

Hemoglobinopathy is a group of inherited disorders characterized by quantitative or qualitative malformations of hemoglobin (Hb). Some of these diseases present vaso-occlusive phenomena that are responsible for high morbidity in clinical and ophthalmologic terms.⁽¹⁾ In the Brazilian population, the most frequent abnormal Hbs are S and C. The most commonly found anomaly is HbS, with the most common abnormal genotype being HbAS, occurring in 9.11% of the samples. Other represented genotypes include one associated with beta-thalassemia in 5.50% of the samples, HbAC in 2.47%, HbSS in 0.76%, and HbSC in 0.39%.⁽²⁾

The double heterozygous variant, HbSC, is linked to a higher occurrence of ophthalmic complications, including proliferative sickle cell retinopathy (PSCR).⁽³⁾

The goal of treatment for PSCR is to avoid vision loss by preventing recurrent vitreous hemorrhage, retinal detachment, and epiretinal membrane development. However, the treatment for PSCR is stage-dependent and controversial. Of untreated individuals, 5 to 10% suffer from vision loss.⁽⁴⁾

We report a case of hemoglobinopathy SC with bilateral retinal detachment.

CASE DESCRIPTION

A 36-year-old male, native of Itabuna (BA) and from Guarulhos (SP), of Black ethnicity, presented with progressive visual acuity loss over 7 years in both eyes. He had a history of tractional retinal detachment in the right eye in 2015 and vitreous hemorrhage followed by retinal detachment in the left eye in 2017. He denied having any systemic illness, trauma, family history of disease, or drug abuse. He reported sporadic mild arthralgia and abdominal pain. At the time of presentation, his best-corrected visual acuity was hand movement in the right eye and counting fingers at one meter distance in the left eye, respectively.

A biomicroscopy showed a white cataract in the right eye, a comma sign in the inferior bulbar conjunctiva (Figure 1), and no changes in the left eye. A dilated fundoscopic exam of the left eye revealed retinal folds in the macula, large areas of fibrovascular vitreoretinal traction, and tractional retinal detachment along the inferotemporal/nasal vasculature (Figures 2 and 3). We performed an AB-scan of the right eye, which showed a large area of tractional retinal detachment (Figure 4).

Routine laboratory tests showed no abnormalities, and serologies and antibody levels were within the normal

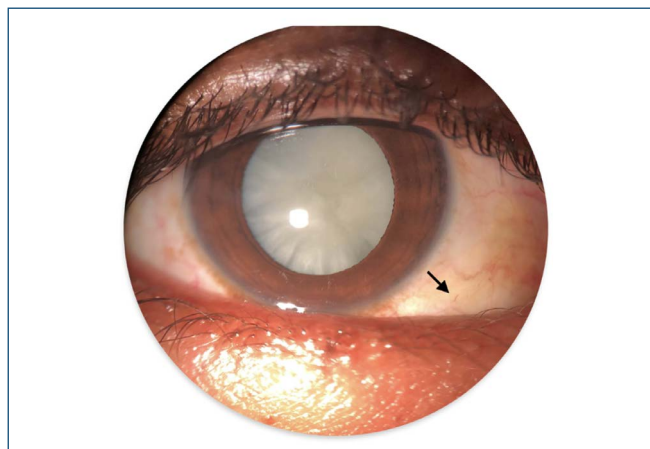


Figure 1. Right eye. Dense white cataract, with a comma sign in the inferior bulbar conjunctiva (arrow).

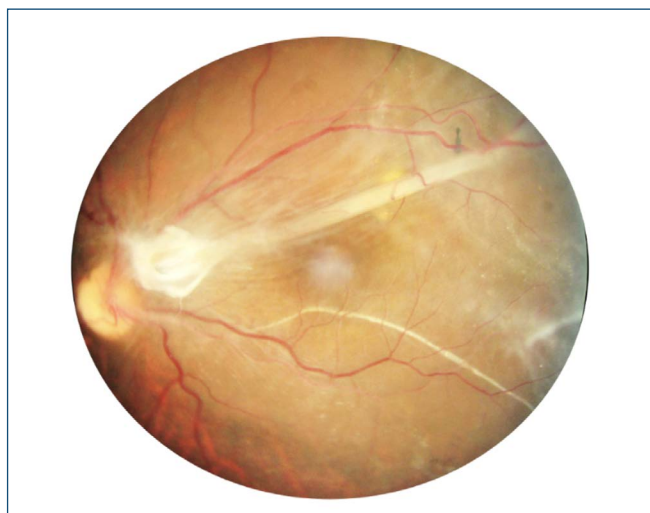


Figure 2. Retinal folds in the macula, large areas of fibrovascular vitreoretinal traction and tractional retinal detachment along the inferior temporal/nasal vasculature.

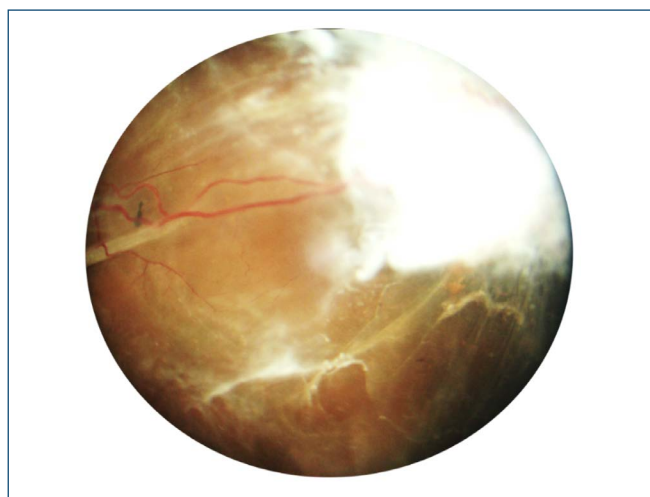


Figure 3. Large areas of fibrovascular vitreoretinal traction and tractional retinal detachment along the inferotemporal/nasal vasculature.

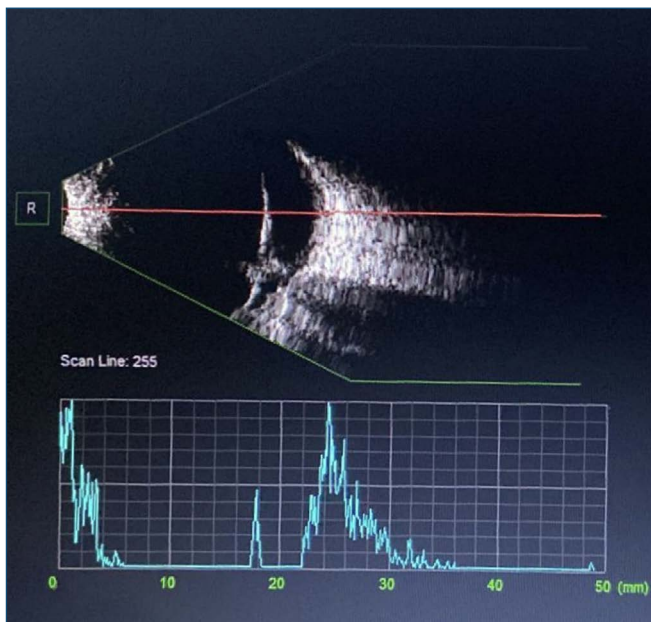


Figure 4. AB-scan of the right eye that presented large area of tractional retinal detachment.

range. A contrasted chest computed tomography (CT)-scan revealed an atrophic and calcified spleen. His baseline Hb was 15g/dL, with a Hb electrophoresis consistent with HbSC disease, showing 48.3% S, 41.7% C, 5.7% F, and 4.3% A2-Hb.

Despite the advanced stage of his condition at the moment of diagnosis, an expectant approach was adopted due to the poor prognosis. After the diagnosis was defined, the patient was referred to the hematology service and continued to be followed up in our department.

DISCUSSION

Hemoglobinopathy is a group of hereditary disorders characterized by abnormal Hb formation.⁽¹⁾ These changes promote the polymerization of HbS in cases of hypoxia, resulting in the characteristic sickle cell shape of red blood cells. Common features of the disease include anemia, hemolysis, and a spectrum of complications that affect multiple organs.⁽⁴⁾

Hemoglobin SC is the second most common variant of sickle-cell disease worldwide, after HbSS. It is caused by a mutation in the sixth codon of the beta globin gene, which results in the substitution of glutamic acid by lysine (GAG > AAG).⁽⁴⁾ Thus, the double heterozygous variant, HbSC, is associated with an increased frequency of ophthalmic complications, including PSCR.⁽⁵⁾ Despite sickle cell hemoglobinopathy with the greatest number of clinical manifestations being the SS type, which leads to hemolysis and sickling crises, patients of the SC genotype, who rarely present systemic changes, are usually those with the most severe retinal manifestations.^(1,6)

Proliferative sickle cell retinopathy usually presents during the third decade of life and affects 43% of patients with sickle SC disease,⁽⁷⁾ which correlates with male gender, recurrent painful crises, and a history of splenic sequestration.⁽³⁾ Sickle cell disease is classified according to the Goldberg system.⁽⁸⁾ Stage I disease indicates peripheral arteriolar occlusions. At Stage II, peripheral arteriolar-venular anastomoses are visible. At Stage III, neovascular and fibrous proliferations are present. In Stage IV, there is vitreous hemorrhage. Without treatment, the most advanced disease results in retinal detachment (Stage V), as seen in our patient.

In Brazil, an estimated 700 to 1,000 new cases of SCD occur annually. Therefore, sickle cell diseases pose a significant public health problem in our country. Bahia has the highest frequency of HbS; a study conducted in Salvador from 2007 to 2009 revealed that the incidence in the state was 1 in 677 live births.⁽¹⁾

A prospective longitudinal study conducted over 20 years in Jamaica showed that the hazard of PSCR onset was 4.2 times higher in SC disease than in SS disease (95%CI 2.3-7.8). Among 473 participants, PSCR had developed in 43% of SC subjects (95% CI 33%-54%) and 14% of SS subjects (95%CI 8%-26%).⁽⁶⁾ Another longitudinal prospective study conducted over 10 years corroborated a higher incidence of visual loss in the eyes with proliferative disease (31 per 1,000 eye-years) than in the eyes with non-proliferative disease (1.4 per 1,000 eye-years of observation).⁽⁹⁾

A study from Curaçao showed that peripheral retinal neovascularization was noted in 4% of the HbSS patients and in 52% of the HbSC patients. Furthermore, out of 50 HbSC patients with neovascularization, 18 had developed vitreous hemorrhage at an average of 35 years. In eight patients, retinal detachment occurred at an average age of 38 years, which is the same age as our patient.⁽¹⁰⁾

CONCLUSION

Considering the prevalence of hemoglobinopathies and the high incidence of sickle cell retinopathy, early detection and treatment are necessary to reduce the socioeconomic impact and improve the quality of life for patients.

REFERENCES

1. Bonanomi MT, Lavezzo MM. Sickle cell retinopathy: Diagnosis and treatment. *Arq Bras Oftalmol.* 2013;76(5):320-7.
2. Aigner CP, Sandrini F, Duarte EG, Andrade MP, Largura MA, Largura A. Estudo do perfil de hemoglobinas em 9.189 testes realizados no Álvaro Centro de Análises e Pesquisas Clínicas. *Rev Bras Anal Clin.* 2006;38(2):107-9.
3. Rosenberg JB, Hutcheson KA. Pediatric sickle cell retinopathy: correlation with clinical factors. *J AAPOS.* 2011;15(1):49-53.

4. Rezende PV, Santos MV, Campos GF, Vieira LL, Souza MB, Belisário AR, et al. Clinical and hematological profile in a newborn cohort with hemoglobin SC. *J Pediatr (Rio J)*. 2018;94(6):666-72.
5. McKinney CM, Siringo F, Olson JL, Capocelli KE, Ambruso DR, Nuss R. Red cell exchange transfusion halts progressive proliferative sickle cell retinopathy in a teenaged patient with hemoglobin SC disease. *Pediatr Blood Cancer*. 2015;62(4):7213.
6. Condon PI, Serjeant GR. Ocular findings in hemoglobin SC disease in Jamaica. *Am J Ophthalmol*. 1972;74(5):921-31.
7. Downes SM, Hambleton IR, Chuang EL, Lois N, Serjeant GR, Bird AC. Incidence and natural history of proliferative sickle cell retinopathy: Observations from a cohort study. *Ophthalmology*. 2005;112(11):1869-75.
8. Goldberg MF. Classification and pathogenesis of proliferative sickle retinopathy. *Am J Ophthalmol*. 1971;71(3):649-65.
9. Moriarty BJ, Acheson RW, Condon PI, Serjeant GR. Patterns of visual loss in untreated sickle cell retinopathy. *Eye (Basingstoke)*. 1988;2(3):330-5.
10. Meurs JC van. Geographical section Ocular findings in sickle cell patients on Curacao. *Int Ophtalmol*. 1991;53-9.