

Giant frontal lipoma mimicking frontal mucocele

Lipoma frontal gigante mimetizando mucocele frontal

Rayssa Medeiros Léda¹ <https://orcid.org/0000-0002-6555-6611>

Mirna de Melo Dias¹ <https://orcid.org/0000-0003-0138-9428>

Bruna Angelina Alves Souza¹ <https://orcid.org/0000-0002-6095-1532>

Eduardo Damous Feijó² <https://orcid.org/0000-0001-7380-5684>

ABSTRACT

Lipoma is a usually painless benign adipose tumor. Nevertheless, it can cause compression of adjacent structures, depending on its location. Mucoceles are benign cystic lesions in the frontal-ethmoidal region, caused by chronic obstruction of the paranasal sinus and consequent inflammatory processes. The increase of mucocele diameter caused by inflammation often results in bony degradation and reabsorption, increasing pressure on adjacent structures, including the orbit and the base of the skull, leading to possibly serious consequences. Here we report a case of lipoma mimicking a frontal mucocele, managed surgically at the Ophthalmological Hospital of Anápolis.

Keywords: Lipoma; Mucocele; Orbital neoplasms; Ophthalmologic surgical procedures

RESUMO

O lipoma é um tumor do tecido adiposo de caráter benigno, usualmente indolor, porém que pode gerar compressão de estruturas adjacentes, dependendo da sua localização. A mucocele consiste em uma lesão cística de caráter benigno, na região fronto-etmoidal, devido à obstrução crônica dos óstios dos seios paranasais e consequente processo inflamatório. O aumento do diâmetro da mucocele por inflamação muitas vezes causa degradação e reabsorção ósseas, o que pode elevar a pressão em estruturas adjacentes como órbita e base de crânio, causando intercorrências possivelmente graves. Neste estudo relatamos um caso de lipoma simulando mucocele frontal, com pedicúta cirúrgica.

Descritores: Lipoma; Mucocele; Neoplasias orbitárias; Procedimentos cirúrgicos oftalmológicos

¹ Anápolis Ophthalmological Hospital, Anápolis, GO, Brazil.

² Department of Ocular Plastic Surgery, Anápolis Ophthalmological Hospital, Anápolis, GO, Brazil.

The authors declare no conflicts of interests.

Received for publication 27/09/2018 - Accepted for publication 09/12/2018.

INTRODUCTION

Lipoma is a benign tumor of adipose tissue, originating from mesenchymal cells. It is more frequent in females and has a hereditary character. It is uncommon in children and, despite being composed of fatty tissue, does not occur more often in obese patients. True (encapsulated) lipomas are usually unique and are located in the upper portion of the body. They are usually painless, but can generate compression of adjacent structures depending on their location. Lipomas in the frontal region are extremely rare, and depending on the location, frontal sinus mucocele may be the differential diagnosis. Frontal mucocele, unlike lipoma, is a benign cystic lesion that usually occurs in the fronto-ethmoid region, caused by obstruction of the paranasal sinuses.^(1,2)

The course of mucocele is characterized by inflammation following chronic obstruction of the paranasal sinuses. Migration of monocytes and lymphocytes is accompanied by production of cytokines by fibroblasts. This is followed by bony degradation and resorption as the diameter of the mucocele increases; this may increase pressure in adjacent structures including the orbit and skull base as it expands, possibly causing ptosis, periorbital edema, peripheral vision, proptosis, chemosis, restriction of extrinsic ocular motility and consequent diplopia.^(3,4)

In this report we present the case of giant fronto-orbito-nasal lipoma simulating a frontal mucocele in a 72-year-old woman.

CASE REPORT

Patient DRS is a 72-year-old woman who presented with a 4-year history of a tumor in the left fronto-orbito-nasal region. The tumor grew painlessly and insidiously over the four years, achieving considerable size by the time she was first seen in our service.

On palpation, the tumor had a fibroelastic consistency, with substantial mobility. It was adhered to the deep planes at its posterior portion. The patient had normal visual acuity, with absence of exophthalmos, palpebral ptosis and ocular dystopia. She denied previous history of chronic sinusitis or trauma in the region. Our clinical diagnosis was frontal mucocele (Figure 1A).

We obtained a CT scan of the skull and orbits (Figure 1B), which revealed an expansive, well-defined, regular, oval-shaped lesion with fat density, measuring approximately 2.2 x 2.6 x 1.7 cm, located in the subcutaneous tissue of the left fronto-orbito-nasal region. There appeared to be no invasion of structures adjacent to the lesion. The primary diagnostic hypothesis became mesenchymal tumor of adipose lineage.

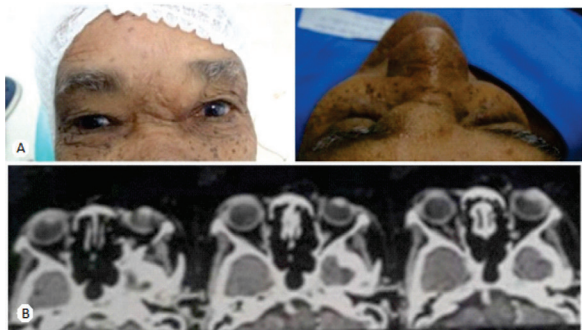


Figure 1: (A) the lesion preoperatively lesion, simulating a frontal mucocele; (B) Computed tomography of the orbits with contrast, revealing an expansive lesion of 2.2 x 2.6 x 1.7 cm, in the subcutaneous tissue of the left fronto-orbito-nasal region.

The treatment chosen for this case was surgical, with excision of the tumor (Figures 2A, B and C) and an anatomopathological study.

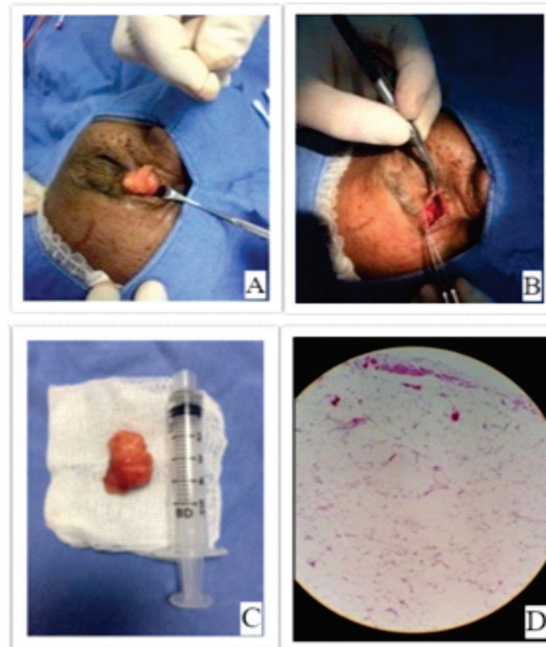

Figure 2: (A) intraoperative excision of the tumor; (B) view after tumor excision; (C) material sent for biopsy material; (D) tumor biopsy section for anatomopathological analysis, consistent with lipoma, without signs of malignancy.

The anatomopathological examination revealed a soft nodular mass of yellowish tissue, measuring 3.0 x 2.0 x 2.0 cm, consistent with a lipoma, without signs of malignancy (Figure 2D). The patient progressed without complications.

DISCUSSION

Lipomas are benign tumors of adipose tissue, usually subcutaneous and slow-growing. They arise in any area of the body where there is fat, including the frontal and periorbital region. It is rare in the orbit, corresponding to less than 1% of all orbital tumors. A review described by Shields et al. reported that, out of a total of 1264 patients with periorbital lesions, only two were lipomas.⁽⁵⁻⁷⁾ Because of their encapsulated and circumscribed character, clinical appearance and similar location, lipomas can mimic mucoceles. Khubchandani et al. reported that the highest incidence occurred in patients between the fifth and sixth decade of life.⁽⁸⁻¹⁰⁾

The etiology of lipomas and their variants remains uncertain. Genetic aberrations, trauma and intermittent chronic compression, are related to the appearance of lipomas.⁽¹¹⁾ Mucoceles more frequently involve the frontal sinus (65% of cases), but may also affect the anterior, maxillary, sphenoid and infrequently the posterior ethmoid sinus. Usually, they are unilateral in nature and affect patients in their 40s and 70s. The clinical appearance is a palpable mass in the superonasal region of the face (as in the present case), a region containing fatty tissue that may also be the site of lipomas. The process develops when the mucosa of the frontal and ethmoidal sinuses becomes inflamed, consequently increasing the amount of mucus in the region. This accumulation of mucus induces cells of the fibroblast lineage to produce cytokines,

recruiting other cells of the immune system, including monocytes and lymphocytes.^(3,12,13)

Reports by Bijith et al. and Nikakhlagh et al. presented patients with mucoceles, but with clinical aspects very similar to those of the present case. Both patients presented with tumors in the frontonasal region with more than three years of evolution and characterized by insidious, painless, non-pulsatile and mobile growth. These patients also had normal visual acuity and negative histories of trauma and chronic sinusitis. As opposed to the present case, these patients had restricted ocular movement of the ipsilateral eye in terms of elevation and adduction; there were also differences in the appearance of the lesions on optical coherence tomography of the skull and orbits.^(3,4)

Although mucoceles are primarily benign, their recurrent nature causes them to dilate the paranasal sinuses due to the accumulation of mucoid secretions, generating increased size and pressure on adjacent structures. The upper wall of the orbit is the most susceptible to bony erosion; in these cases, compression exerted by the expanding mucocele can displace the globe inferiorly.^(4,14,15)

The clinical differentiation between lipoma and mucocele can be difficult, particularly in the periorbital region, as this is a preferential site for frontal mucoceles. In cases where the diagnosis is in doubt, computed tomography of the skull and orbits is recommended. Tomographic findings of a homogeneous mass with fat density indicate a tumor of lipomatous lineage, and may represent a lipoma or liposarcoma. To differentiate these two entities, it is necessary to correlate clinical aspects, radiological appearance and histology.⁽⁸⁾

Differentiated liposarcomas can simulate lipomas because of their well-defined contours and mobility. Computed tomography can reveal a mass with fat density interspersed with areas of higher density that may resemble lipomas, in which case the definitive diagnosis is made through biopsy.⁽¹⁶⁾

As described in the literature, the treatment of lipoma is surgical excision of the tumor, especially if there is diagnostic doubt, and complete removal is required to avoid recurrence.^(5,8)

Paranasal sinus pathologies and those with lipomatous lineage should be included in the differential diagnoses of orbital and periorbital disorders, including in patients presenting with proptosis or other ocular symptoms. Lipomas and mucoceles are benign, potentially curable lesions that can mimic one another. Therefore, early diagnosis with well-performed clinical examination, differentiation and appropriate treatment are very important for appropriate treatment.

REFERENCES

1. Accetta P, Accetta I, Vassallo E, Milman M, Souza A, Accetta A. Lipomas gigantes. *Rev Col Bras Cir.* 1998;25(5):364-365.
2. Carranza-Romero C, Armario-Hita JC, Fernandez-Vozmediano JM. Frontal congenital lipoma. *Pediatr Dermatol.* 2012;29(4):490-4.
3. Bijith EV, Mathew S, Mahadevan K. Frontal mucocele mimicking a frontal subcutaneous tumor. *Asian J Neurosurg.* 2017;12(4):760-2.
4. Nikakhlagh S, Rasekhi R, Saki N. Frontal mucocele presenting as a subcutaneous giant mass. *Biomed Pharmacol J.* 2015;8(Mar Suppl Ed):43-5.
5. Eloy JA, Shukla PA, Choudhry OJ, Eloy JD, Langer PD. In-office balloon dilation and drainage of frontal sinus mucocele. *Allergy Rhinol (Providence).* 2013;4(1):e36-40.
6. Sanchez MR, Golomb FM, Moy JA, Potozkin JR. Giant lipoma: case report and review of the literature. *J Am Acad Dermatol.* 1993;28(2 Pt 1):266-8.
7. Shields JA, Shields CL, Scartozzi R. Survey of 1264 patients with orbital tumors and simulating lesions *Ophthalmology.* 2004;111(5):997-1008.
8. Simango S, Ramdial PK, Madaree A. Subpectoral post-traumatic lipoma. *Br J Plast Surg.* 2000;53(7):627-9.
9. Chi MJ, Roh JH, Lee JH, Paik HJ. A case of orbital lipoma with exophthalmos and visual disturbance. *Jpn J Ophthalmol.* 2009;53(4):442-4.
10. Khubchandani M, Thosar NR, Bahadure RN, Baliga MS, Gaikwad RN. Fibrolipoma of buccal mucosa. *Contemp Clin Dent.* 2012;3(5 Suppl 1):S112-4.
11. Vasconcelos JS, Gharaibeh F, Nittinger HC. Trauma as pathogenesis of a plantar forefoot fibrolipoma: first case and review of the literature. *Case Rep Surg.* 2013;2013:691276.
12. Rosado P, de Vicente JC, Villalaín L, Fernández S, Peña I. Posttraumatic frontal mucocele. *J Craniofac Surg.* 2011;22(4):1537-9.
13. Aydin E, Akkuzu G, Akkuzu B, Bilezikci B. Frontal mucocele with an accompanying orbital abscess mimicking a fronto-orbital mucocele: case report. *BMC Ear, Nose Throat Disord.* 2006;6:6.
14. Mohan S. Frontal sinus mucocele with intracranial and intraorbital extension: a case report. *J Maxillofac Oral Surg.* 2012;11(3):337-9.
15. James E, Dutta A, Swami H, Ramakrishnan R. Frontal Mucocele causing Unilateral Proptosis. *Med J Armed Forces India.* 2009;65(1):73-4.
16. Ehara S, Rosenberg AE, Kattapuram SV. Atypical lipomas, liposarcomas, and other fat-containing sarcomas. CT analysis of fat element. *Clin Imaging.* 1995;19(1):50-3.

Corresponding author:

Eduardo Damous Feijó
Ocular Plastic Surgery Sector of the Anápolis Ophthalmological Hospital, Anápolis, Goiás, Brazil.
Address: Av. Faiad Hanna, 235. Cidade Jardim Anápolis, GO,
Zip code: 75080-410
E-mail: eduardodff@yahoo.com.br