

# Rothmund syndrome

## *Síndrome de Rothmund*

---

Thiago Gonçalves dos Santos Martins<sup>1</sup>, Ana Luiza Fontes de Azevedo Costa<sup>2</sup>, Thomaz Gonçalves dos Santos Martins<sup>3</sup>

### **ABSTRACT**

*Rothmund-Thomson syndrome (RTS) is a rare autosomal recessive genodermatosis. While its incidence is unknown, approximately 300 cases have been reported in the literature. The syndrome typically presents with a characteristic facial rash (poikiloderma), its diagnostic hallmark, and heterogeneous clinical features including congenital skeletal abnormalities, sparse hair distribution, juvenile cataracts, and a predisposition to osteosarcoma. This is a report describing a patient diagnosed with RTS referred to us because of low vision and red eyes.*

**Keywords:** Rothmund-Thomson syndrome/complications; Vision, low/etiology; Visual acuity; Case reports

### **RESUMO**

A síndrome de Rothmund (RTS) é uma rara genodermatose, de herança autossômica recessiva. Sua incidência é desconhecida, com aproximadamente 300 casos descritos na literatura. A síndrome é determinada por eritema facial (poiquilodermia), seu marco diagnóstico, além de alterações esqueléticas, alopecia, catarata juvenil e predisposição a osteossarcoma. Neste relato, descrevemos uma paciente com esta síndrome, que foi referida ao serviço de oftalmologia por baixa visão e hiperemia ocular.

**Descritores:** Síndrome de Rothmund-Thomson/complicações; Baixa visão/etiologia; Acuidade visual; Relatos de casos

---

<sup>1</sup> Federal University of São Paulo, São Paulo, SP, Brazil.

<sup>2</sup> University of São Paulo, São Paulo, SP, Brazil.

<sup>3</sup> Medicine College, Estácio de Sá University, Rio de Janeiro, RJ, Brazil.

**The authors declare no conflicts of interests.**

Received for publication 21/01/2015 - Accepted for publication 02/04/2015

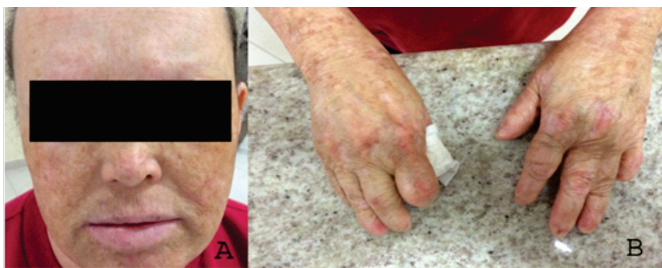## INTRODUCTION

The Rothmund syndrome (congenital poikiloderma) is a recessive autosomal disease that begins in childhood with the presence of facial erythema (poikiloderma) associated to bone abnormalities, short stature, radio changes, alopecia, absence of eyelashes and eyebrows, juvenile cataracts and predisposition to neoplasia.<sup>1</sup>

We report the case of a patient with Rothmund syndrome with limbic insufficiency in both eyes, who was accompanied by a multidisciplinary team due to their systemic manifestations.

## CASE REPORT

The patient reported that since childhood has suffered from growth retardation and dermatological symptoms, with dry and scaly skin, followed by photosensitivity and erythema poikiloderma, particularly in the face, neck and limbs (Figures 1A and 1B)

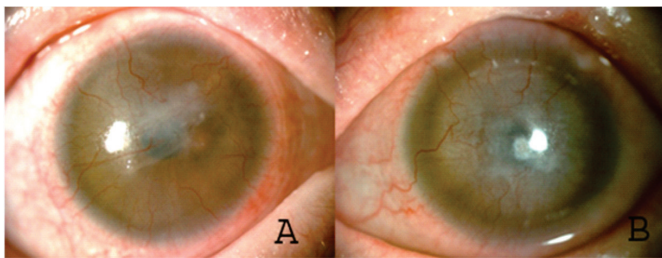


**Figure 1 (A e B):** Dry and scaly skin, alopecia, poikiloderma, hypoplasia of the fingers

After being diagnosed with Rothmund syndrome in childhood, presented episodes of chronic microcytic and hypochromic anemia, persistent despite the iron replacement therapy. She underwent facectomy in both eyes at age 14 with no complications.

The examination showed glossitis, cheilitis, thinning of hair, nail dystrophy, change of fingers and dental abnormalities, being the teeth removed and a prostheses being currently used. The visual acuity was of 20/100 in both eyes, with ocular hyperemia, neovascularization and corneal stromal opacities in both eyes (Figures 2A and 2B). Absence of eyelashes and eyebrows, eyelid entropion and intraocular pressure of 10 mmHg in both eyes. No changes in the posterior segment in ultrasound exams.

The patient had been complaining of low visual acuity and ocular hyperemia for seven years. She had been using eye lubricants in the form of eyedrops and gels for a year.



**Figure 2 (A e B):** Corneal neovascularization, stromal opacities and no eyelashes.

In the family history there were no other cases similar to hers and the karyotype was normal, as well as her neurocognitive development.

## DISCUSSION

The Rothmund syndrome was first described in 1868 by A. Rothmund,<sup>2</sup> a German ophthalmologist who noted that children born in the villages in Bavaria where consanguineous marriage was common were affected by poikiloderma, growth retardation and juvenile cataracts. In 1936, M. Thomson, an English dermatologist, reported three patients with similar skin disorders, growth retardation and skeletal defects.<sup>3</sup> The symptoms described by Thomson are identical to those observed by Rothmund, except for cataracts. In 1957, W. Taylor, an American physician, determined the eponym Rothmund-Thomson syndrome to describe patients with these signs and symptoms.<sup>4</sup>

There are two clinical forms of the disease. Type 1 is characterized by poikiloderma, ectodermal dysplasia and juvenile cataracts, whereas type 2 presents poikiloderma, bony birth defects, increased risk of osteosarcoma during childhood and skin cancer in adulthood. The genetic defect of type 1 has not been identified yet, but type 2 is caused by mutations in helicase RECQL4 gene on chromosome 8, which produces RECQ protein that, when defective, impairs the ability of the repair the DNA.<sup>5</sup>

Dermatologists are often the first to diagnose this syndrome, since the skin, hair, nails and teeth are often the first to be affected. The main clinical framework of the syndrome is skin erythema, which usually appears between six months and three years old, and initially usually involves the cheeks, extending to the edges, affecting buttocks and extensor and flexor surfaces of the limbs. The torso and abdomen are usually not affected. The patient usually has thin and sparse hair, and no eyelashes and eyebrows.

Growth retardation is the second most important symptom of the syndrome. Skeletal disorders can occur, as well as juvenile cataract, in 50% of patients<sup>5,6</sup>. The main tumors to which these patients are predisposed are osteosarcoma (childhood and adolescence) and squamous cell carcinoma in adults.

A genetic evaluation is not necessary for the diagnosis of the syndrome. The differential diagnosis includes other causes of poikiloderma in childhood, with Gottron syndrome, hereditary sclerosing poikiloderma, Kindler syndrome, Bloom syndrome, Werner syndrome, dyskeratosis congenita, xeroderma pigmentosum, Fanconi anemia, ataxia-telangiectasia and Cockayne syndrome.<sup>6,7</sup>

The patient was referred to the oculoplastics service to correct the entropion, to be later submitted to a limb and cornea transplantation aimed to improve the visual acuity.

## CONCLUSION

We reported a rare syndrome with ophthalmologic manifestations and surgical indication to improve the vision. The visual symptoms are considered minor signs for the diagnosis, although the juvenile cataract may be present in up to 50% of patients. The patient should be followed by a multidisciplinary medical team due to the systemic changes described and the risk of developing cancer.

## REFERENCES

1. Larizza L, Roversi G, Volpi L. Rothmund-Thomson syndrome. *Orphanet J Rare Dis.* 2010 Jan 29;5:2.
2. Rothmund A. [Uber Cataracte in Verbindung mit einer eigenthuemlichen Hautdegeneration]. *Albrecht Von Graefes Arch Klin Exp Ophthalmol.* 1868; 14:159-82. German.
3. Thomson MS. Poikiloderma congenitale. *Br J Dermatol.* 1936; 48:221-34.
4. Taylor W B. Rothmund's syndrome-Thomson syndrome. *Arch Dermatol.* 1957; 75(2): 236-44.
5. Vennos EM, Collins M, James WD. Rothmund-Thomson syndrome: review of the world literature. *J Am Acad Dermatol.* 1992;27(5 Pt 1):750-62. Review.
6. Wang LL, Levy ML, Lewis RA, Chintagumpala MM, Lev D, Rogers M, Plon SE. Clinical manifestations in a cohort of 41 Rothmund-Thomson syndrome patients. *Am J Med Genet.* 2001;102(1):11-7.
7. Vennos EM, James WD. Rothmund-Thomson syndrome. *Dermatol Clin.* 1995;13(1):143-50. Review.

---

### **Corresponding author:**

Thiago Gonçalves dos Santos Martins  
Rua Botucatu, 821 Vila Clementino, São Paulo  
ZIP Code: 04023-062  
phone: 552125712248  
E-mail: thiagogsmartins@yahoo.com.br