

Clinical analysis therapy and tomographic parameters of patients diagnosed with keratoconus attended at Fundação Hilton Rocha

Análise clínica, terapêutica e dos parâmetros tomográficos de pacientes portadores de ceratocone atendidos na Fundação Hilton Rocha

Izabela dos Santos de Moura e Silva¹, Cristiane Samara Botteon¹

ABSTRACT

Objective: Analyze clinical data, therapy and tomographic parameters of patients attended at Fundação Hilton Rocha. **Methods:** This essay is a retrospective study based on a random sample of 150 patients submitted to cornea tomography and previous segment (Pentacam – Oculus, Wetzlar, Germany) at Fundação Hilton Rocha in the year 2015. The patients were classified as carriers or suspects of keratoconus through the following parameters: pachymetry, anterior and posterior central elevation, Ambrosio Relational Thinnest (ART), value of D and keratometry. After the selection an analysis of the medical records was done, followed by harvest of clinical and therapeutical data of the patients. The data was put on table and then analyzed. **Results:** From the numbers of the patients diagnosed with carriers of keratoconus, 23% had 6 altered parameters, and 10% were classified with only 1 altered parameter. The ART index was the one that suffered the largest change (83%) on the keratoconus carriers. After analysis of clinical and therapeutical data, 76.8% of patients showed better or more of 20/60 degree of visual acuity, and 19% mentioned signs of atopy, 90% of the patients were using only corrective lenses as treatment (glasses and contact lenses). **Conclusion:** The use of tomographic indexes for the diagnosis of keratoconus has been increasing the sensibility and specificity of the triage of carriers of this ectasy, allowing an earlier and better diagnosis of this medical condition.

Keywords: Keratoconus, Cornea, Diagnosis, Ectasy, Tomography.

RESUMO

Objetivo: Analisar dados clínicos, terapêuticos e parâmetros tomográficos dos pacientes portadores de ceratocone atendidos na Fundação Hilton Rocha. **Métodos:** É um estudo retrospectivo com amostra aleatória de 150 pacientes submetidos a tomografia de córnea e segmento anterior (Pentacam - Oculus, Wetzlar, Alemanha) na Fundação Hilton Rocha no ano de 2015. Os pacientes foram classificados como portadores ou suspeitos de ceratocone através dos parâmetros: paquimetria, elevação central anterior e posterior, Ambrosio Relational Thinnest (ART), valor de D e ceratometria. Após a seleção foi realizada análise dos prontuários, coletados dados clínicos e terapêuticos dos pacientes. Os dados foram colocados em tabela e analisados. **Resultados:** Dos pacientes classificados como portadores de ceratocone, 23% tinham 6 parâmetros alterados, e 10% foram classificados com apenas 1 parâmetro alterado. O índice ART foi o que mais se alterou (83%) nos pacientes portadores de ceratocone. Na análise dos dados clínicos e terapêuticos, 76,8% dos pacientes apresentaram acuidade visual melhor ou igual a 20/60, e 19% mencionaram apresentar atopia e, 90% dos pacientes utilizavam como tratamento apenas lentes corretoras (óculos e lente de contato). **Conclusão:** A utilização de índices tomográficos para o diagnóstico do ceratocone têm aumentado a sensibilidade e a especificidade na triagem de pacientes portadores desta ectasia, possibilitando o diagnóstico de maneira mais precoce e consequentemente maior sucesso terapêutico.

Descritores: Ceratocone, Córnea, Diagnóstico, Ectasia Tomografia.

¹ Department of Cornea, Fundação Hilton Rocha, Belo Horizonte, MG, Brazil.
Study carried out at Fundação Hilton Rocha, Belo Horizonte, Minas Gerais, Brazil

The authors declare no conflict of interests.

Received for publication 24/07/2017 - Accepted for publication 19/11/2017.

INTRODUCTION

The cornea is a transparent structure which tends to be spherical, and together with the sclera make up the fibrous tunic of the eye.⁽¹⁾ Keratoconus is a non-inflammatory, usually bilateral, asymmetric corneal ectasia characterized by progressive thinning causing an increase in corneal curvature, irregular astigmatism leading to gradual decrease of vision.⁽²⁻⁵⁾ The approximate incidence of keratoconus in the general population is between 50 and 230 / 100,000 inhabitants.⁽⁴⁾

The etiology proposed for keratoconus includes physical, biochemical and molecular changes in the corneal tissue. However, no theory fully explains the findings related to keratoconus.^(4,5) There is already a well-established correlation to hereditary diseases, atopic diseases, some systemic diseases, prolonged use of contact lenses, collagen diseases and frequent eye friction.^(4,5)

The differentiation between moderate and severe keratoconus is made through the analysis of the classic signs present in retinoscopy and biomicroscopy (thinning of the localized cornea, Fleischer ring, Munson's sign, Rizzuti's sign, and Vogt's striae.^(1,5) On the other hand, the identification of initial and subclinical forms is a challenge, since the patient mostly presents good visual acuity with correction, and shows no signs to the examination.⁽¹⁾

The identification of subclinical keratoconus is important for the follow-up of patients with irregular astigmatism, irregular keratoconus, and family history of keratoconus.^(1,6) Corneal tomography is the most effective method for the diagnosis of early forms of keratoconus. It can be made by various methods: horizontal scanning slot (Orbscan II®, Bausch & Lomb), rotating Scheimpflug camera (Pentacam®, Oculus), high frequency ultrasound (Artemis®, Ultralink), and anterior segment optical coherence tomography (Visante®, Zeiss)¹.

The tomographs have maps and displays that aid in the diagnosis of early forms of keratoconus, increasing the sensitivity and specificity in screening patients for ectasia.⁽⁷⁾ These parameters are able to detect smooth abnormalities related to ectasia previous to the alterations of the topographic parameters.⁽⁷⁾

OBJECTIVE

The objective of the present study is to analyze clinical, therapeutic and tomographic parameters of patients with keratoconus treated at Fundação Hilton Rocha, a reference center in ophthalmology located in Belo Horizonte / MG.

METHODS

Retrospective study with a random sample of 150 patients drawn from the universe of 1535 patients submitted to corneal and anterior segment tomography (Pentacam - Oculus, Wetzlar, Germany) at Fundação Hilton Rocha/ Belo Horizonte in the year 2015, with subsequent analysis of the of patients' medical records considered suspected or suffering from keratoconus.

Patients were considered suspected or suffering from keratoconus when they presented at least one of the following characteristics: pachymetry lower than 500 µm for suspected and lower than 450 µm for patients with keratoconus; anterior central elevation between 12 and 15 for suspected of keratoconus and greater than 15 for keratoconus patients; posterior central

elevation between 17 and 20 for suspected keratoconus and greater than 20 for keratoconus patients; Ambrosio Relational Thinnest (ART) between 340 and 380 for suspected of keratoconus and lower than 340 for keratoconus patients; D value greater than or equal to 1.6 for suspected and greater or equal to 2.6 for keratoconus patients; and, keratometry greater than 47.2D for suspected and greater than 48.7D for patients of the disease.

After the sample selection, the medical records were analyzed, and the clinical and therapeutic data of the patients was collected. We collected data on visual acuity after refraction, changes in biomicroscopy, underlying diseases of the patient, and treatment instituted.

The inclusion criteria were patients diagnosed with suspect of or with keratoconus who fulfilled the criteria described above and presented CT scans performed correctly with reliability rate with no changes ("OK") and complete, legible, and dated.

The exclusion criteria were patients with other corneal pathologies such as scars, dystrophies, degenerative processes, and active infectious or inflammatory changes.

Data was inserted in a Windows Excel spreadsheet and analyzed using the IBM SPSS Statistics Editor software. A chi-square test was performed for the frequency analysis, with a significance level of 0.05 for interpretation.

The project was posted at Plataforma Brasil (CAAE: 65029616.9.0000.5141) and forwarded for analysis by the Research Ethics Committee of Associação Educativa do Brasil – SOEBRAS/Faculdades Unidas do Norte de Minas, with opinion number: 2.092.932

RESULTS

Of the 150 selected patients, 40 were excluded from the study because they had an altered reliability rate due to lack of data, patient blinking during examination, non-collaborative patient, patient with other corneal diseases, and improperly completed medical records.

A total of 110 patients were analyzed, with a total of 220 eyes. The majority of the patients (n = 169, 76.8%) had visual acuity greater than or equal to 20/60, and 18 patients presented vision worse than or equal to 20/200 (8.1 %) (Table 1).

As for the biomicroscopic findings, the papillae were found in 34 eyes, being present in about 15% of the eyes studied, and Vogt's striae in 18 eyes (8.18%) (Table 2).

Regarding the systemic diseases associated, 75% of patients did not report any disease, and among those who reported it, 21 reported atopy, 10 reported systemic arterial hypertension (SAH), and 2 reported diabetes mellitus (DM). Regarding the treatment used, 70 patients wore glasses; 29 wore contact lenses; 7 underwent intrastraval ring placement, and 4 underwent corneal transplant.

Of the total of 220 eyes evaluated, the majority had keratoconus (n = 189, 85.9% of total). 21 eyes (9.5%) had suspected keratoconus, and 10 eyes (4.6%) neither were suspected nor had keratoconus. Of the patients with keratoconus, 52 eyes presented the 6 criteria altered (23.6% of total), and 42 eyes had 5 criteria altered (19.1%) (Figure 1).

The ART diagnostic criterion considered most eyes with keratoconus (n = 183, 83.2%), and pachymetry considered the smallest part (n = 87, 39.5%). In the eyes with suspected keratoconus, pachymetry considered most of them (n = 86; 39.1%), and the posterior central elevation considered the smallest part of the eyes (n = 8, 3.6%). (Figure 2).

Table 1
Values of visual acuity per eye analyzed

Fractional notation of visual acuity (V=20/p)	N	%
20/20	46	20.9
20/25	33	15.0
20/30	40	18.2
20/40	25	11.4
20/50	17	7.7
20/60	8	3.6
20/70	13	5.9
20/80	6	2.7
20/100	13	5.9
20/150	1	0.5
20/200	5	2.3
20/400	5	2.3
CD 2 M	1	0.5
CD 1 M	5	2.3
MM	1	0.5
NPL	1	0.5
Total	220	100.0

Table 2
Biomicroscopic findings of each eye

Biomicroscopic findings	N
Central thinning	10
Paracentral thinning	10
Hydrops scar	4
Fleisher ring	2
Cataracts	8
Vogt's striae	18
Central opacity	6
Central leukoma	2
Intraocular lens	4
Nubule	2
Pterygium	6
Paracentral opacity	10
Papillae	34
Corneal transplant	4
Total	120

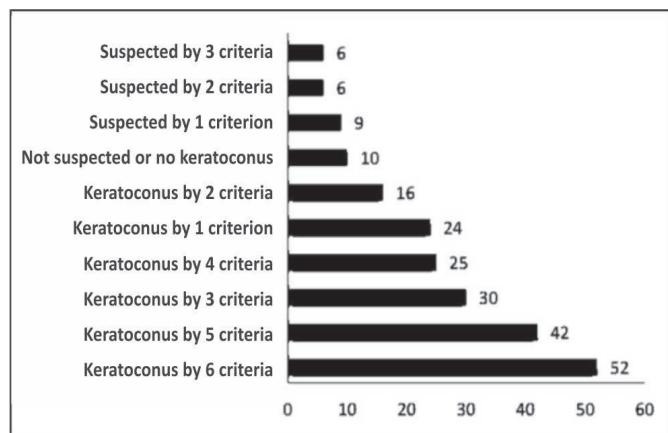


Figure 1: Classification of the eyes of the sample according to topographic criteria such as suspected keratoconus and presence of keratoconus

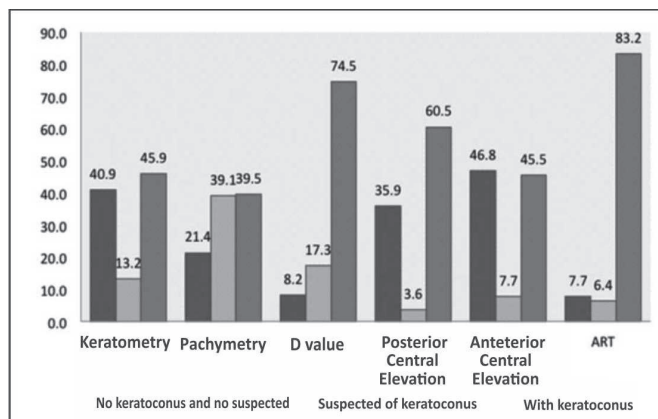


Figure 2: Classification of eyes according to topographic criteria (no keratoconus, no suspected keratoconus, suspected of keratoconus, presence of keratoconus) - percentage.

DISCUSSION

The study showed that, regarding the treatment, 99 patients wore glasses or contact lenses, and 76.8% presented visual acuity better than 20/60. The prescription for glasses and contact lens is made in the initial and soft cases of keratoconus, in which it is possible to have a good visual acuity without invasive treatments.^(5,8) Seven patients (6.3%) underwent intraethromal ring placement. The ring is used as an option in patients with no corneal changes and intolerant to contact lens in an attempt to decrease or delay the corneal transplant.^(5,8)

Twenty-one patients (19%) reported atopy, and 34 eyes of the 220 analyzed (28.3%) had papillae. This data is in agreement with other studies found in the literature, as in the study of Mianet al.⁽⁵⁾ which found a prevalence of 19.2% of patients with keratoconus and atopic. According to Botelho et al.⁽⁹⁾ who analyzed 27 medical records of atopic patients, 48.3% had keratoconus. Along with that, Elias et al.⁽¹⁰⁾ analyzed patients with keratoconus and found a prevalence of 53.3% with atopy.

Pentacam® has maps and displays that aid in the diagnosis of early forms of keratoconus, increasing the sensitivity and specificity in screening patients for ectasia.^(4,7) In the present study, the patients were considered as suspected of keratoconus or with keratoconus after the analysis of 6 parameters of Pentacam®, and about 23% of patients were considered as having keratoconus with 6 parameters changed, and only 10% were considered with only 1 parameter changed. This was probably due to the fact that the patients selected were referred to the ambulatory of Fundação Hilton Rocha, many times already being suspected of keratoconus, or were referred for follow-up after an established diagnosis of keratoconus.

The Ambrosio Relational Thinnest (ART) criterion was the one that considered the patients as having keratoconus, and was altered in about 83% of patients with keratoconus. The value of ART is the best parameter to rank keratoconus patients and evaluates the lowest pachymetric value found and correlates to pachymetric progression.⁽¹⁾ On the other hand, the value of isolated pachymetry was the one that changed the most among the patients suspected of keratoconus, but it should not be evaluated in isolation, since, despite the patients with keratoconus present low pachymetry, it is not every patient who has low pachymetry

that has keratoconus, so this parameter should be analyzed along with the others.

Only 45.9% of patients analyzed presented changes in keratometry, and in case only aceratometry as it is used by many authors who analyze data from topographic examinations was used for keratoconus classification, more than 50% of the patients would not be considered as having keratoconus.

CONCLUSION

Based on the results of the present study, we concluded that there is a considerable amount of patients with atopy related to the habit of scratching the eyes, which can worsen the ectasia. The majority of patients presented a vision better than 20/60, with the most used treatment being wearing glasses and contact lenses.

The tomographic classification allows an analysis by maps and displays and rates that aid in the diagnosis of early forms of keratoconus, increasing the sensitivity and specificity in screening patients for ectasia. With this, the diagnosis is possible in an earlier way, with greater therapeutic success. In the present study, the Ambrosio Relational Thinnest (ART) criterion was the one that considered the patients as having keratoconus.

Many authors suggest rates to diagnose early keratoconus. The development of propaedeutic methods, as well as the use of more modern equipment, has improved the screening of the disease, facilitating the diagnosis of susceptibility to ectasia.

REFERENCES

1. Ambrosio R, Alonso RS, Luz A, Velarde RG. Corneal thickness spatial profile and corneal volume distribution: Tomographic indices to detect. *Journal Cataract Refract Surg.* 2006; 32:1851-9.
2. Ambrosio R. Simplifying ectasia screening with Pentacam corneal tomography. *Highlights Ophthalmol.* 2010; 38(3):12-20.
3. Junqueira LC, Carneiro J. *Histologia básica.* 9a ed. Rio de Janeiro: Guanabara Koogan; 2012.
4. Lopes AC, Pinto AGT, Sousa BA. Ceratocone: uma revisão. *Rev Med Saude (Brasília).* 2015; 4(2): 219-32
5. Mian CL, Carvalho DA, Souza MA, Moraes TC, Costa MI, Moreira GA, et. al. Perfil epidemiológico dos pacientes portadores de ceratocone atendidos em um hospital privado de Campo Grande-MS. *Ensaios Ciênc.* 2013; 17(3):113-21.
6. Valbon BF, Salomão M, Ramos I, Canedo AL, Nogueira L, Ambrosio Junior R. Importância da tomografia de córnea para o diagnóstico de ectasia. *Rev Bras Oftalmol.* 2012; 51(5):302-8.
7. Belim MW, Khachikian SS, Ambrosio Junior R. Keratoconus/ Ectasia detection with the Oculus Pentacam: Belim/ Ambrosio enhanced ectasia display. *Highlights of ophthalmology.* 2010; 35(6):5-12.
8. Siqueira AV, Polo J, Gomes MB, Moreira H. Anel corneano intraestromal assimétrico no tratamento do ceratocone. *Arq Bras Oftalmol.* 2010; 73(5):454-8.
9. Botelho PB, Marback P, Sousa LB, Campos M, Vieira LA. Ceratoconjuntivite alérgica e complicações no segmento ocular anterior de pacientes. *Arq Bras Oftalmol.* 2003; 66(1):25-8.
10. Elias RM, Lipener C, Uras R, Pavês R. Ceratocone: fatores prognósticos. *Arq Bras Oftalmol.* 2005; 68(4):491-4.

Corresponding author:

Izabela dos Santos de Moura e Silva
Avenida José do Patrocínio Pontes, 1355, Mangabeiras, Belo Horizonte, Minas Gerais, Brazil
E-mail: izabela.sms@hotmail.com