

Optic neuropathy toxic after methanol inhalation

Neuropatia óptica tóxica por inalação de metanol

Frederico Gustavo Telles e Souza¹, Vanessa Veloso Eleutério Nogueira², Luana Inostrosa Maynard², Rafael Leite de Oliveira², Thatiane Célia dos Santos Mendonça³, Pablo Dias Oliveira³

ABSTRACT

The methanol toxicity is considered rare event, especially when taken by inhalation. It was portrayed in the present study a case report of a patient who developed toxic optic neuritis after exposure to methanol and acetic acid by inhalation in the workplace. It was described for the therapies from the literature as well as the clinical manifestations and management in this patient.

Keywords: Methanol/adverse effects; Methanol/poisoning; Optic neuritis/chemically induced; Case reports

RESUMO

A intoxicação por metanol é um evento considerado raro, principalmente quando feita por via inalatória. Retratou-se neste presente estudo um relato de caso de um paciente que desenvolveu neurite óptica tóxica após exposição ao metanol e ácido acético por via inalatória em seu ambiente de trabalho. Foi descrito sobre as terapias obtidas na literatura, bem como as manifestações clínicas e o manejo a este paciente.

Descritores: Metanol/efeitos adversos; Metanol/envenenamento; Neurite óptica/induzida quimicamente; Relato de casos

¹ Santa Casa Olhos, Montes Claros, MG, Brazil.

² Faculdades Integradas Pitágoras, Montes Claros, MG, Brazil.

³ Faculdades Integradas do Norte de Minas, Montes Claros, MG, Brazil.

The authors declare no conflict of interests.

Received for publication 16/01/2017 - Accepted for publication 09/11/2017.

INTRODUCTION

Methanol is a volatile alcohol used commercially in a wide variety of products, and may have inhalation, ingestion and absorption by the skin a routes of entry into the human body. The toxicity caused by this substance is interlinked with its metabolites, mainly formic acid.⁽¹⁾ Several symptoms and signs may arise, with the most common ones being related to the central nervous system, the eyes and the gastrointestinal tract.⁽²⁾ Among the clinical manifestations and alterations that occur are confusion, ataxia, visual impairment, metabolic acidosis, brain injury and even death.⁽³⁾ Visual changes may range from blurred vision and visual field deficits to total blindness⁽⁴⁾ associated to headache, nausea, vomiting, and dizziness. The ocular toxicity caused by formic acid worsens acidosis, which allows a greater spread of formic acid in the cells, causing optic disc edema, dysfunction of the myelin sheaths, and injury of the optic nerve.⁽²⁾

We reported a case of a patient with intoxication due to accidental inhalation of methanol due to labor exposure. The early detection of the symptomatology and the institution of the therapy allowed a favorable development of the clinical condition.

CASE REPORT

Patient G. A. R. S, male, 43 years old, born in Montes Claros, MG, laboratory instructor. He reports being exposed to methanol and acetic acid solution for four consecutive mornings, and consequently inhaling these substances during labor activities. He was admitted at the emergency with a significant reduction of visual acuity, paresis of lower limbs, generalized paraesthesia, vomiting and general malaise. As a pathological antecedent, he reported only poorly controlled systemic arterial hypertension. He had arterial gasometry and acidotic respiratory pattern: Ph: 7.05, PCO₂ 11 and HCO₃ 3.0.

Due to the unavailability of the antidote Fomepizol or ethanol, 40 ml of Whiskey was administered orally every 4h, with sodium bicarbonate and vigorous venous hydration. After four days of stabilization of the clinical condition, the patient was admitted to the ophthalmology department with significant low visual acuity and bitemporal scotoma. Figure 1 shows the progression of automated campimetry for central scotoma. He presented corrected visual acuity of 20/400 in the RE and 20/200 in the LE at the first examination. The retinal mapping exam showed margins of the optic disc with inaccurate limits, peridiscal flame shaped hemorrhages in both eyes.

Fluorescent angiography (Figure 2) revealed hyperfluorescence due to superficial and deep optical disk extravasation in the intermediate and late phases, hypofluorescence due to blockage corresponding to superficial retinal hemorrhage points, the and macula was preserved in both eyes. Color and redfree retinography (Figure 3) after 45 days of development showed excavation progression and significant pallor of the optic nerve. MRI of the orbits was requested (Figure 4), and presented a focus of enhancement in the distal orbital portion of the optic nerve bilaterally, suggesting toxic optic neuritis by methanol.

The patient was referred to the neurology service to continue the treatment. Initially, weekly doses of intramuscular injectable B complex were given. After 30 days of treatment, the patient showed significant improvement of vision to 20/40 in the RE and 20/30 in

the LE. However, funduscopy revealed diffuse pallor of the optic nerve and visual campimetry with tubular constriction in both eyes.

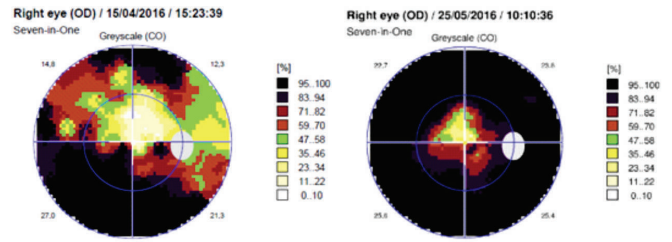


Figure 1: Automated campimetry performed within 45 days.

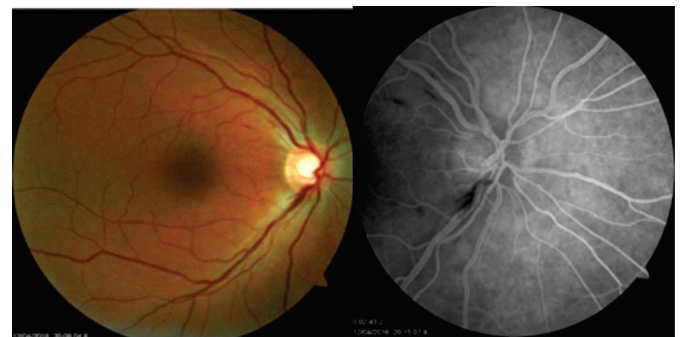

Figure 2: Angiography 04/12/2016

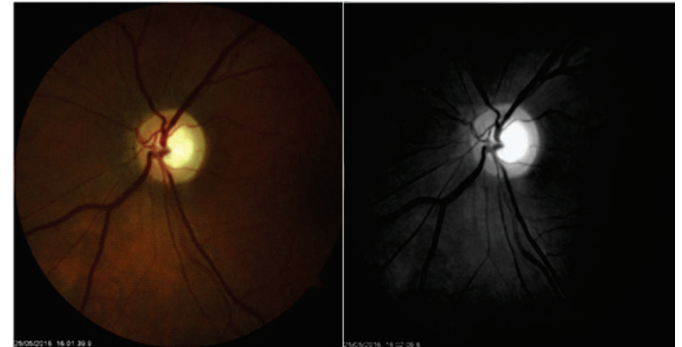

Figure 3: Red Retinography and Red Free 05/25/2016

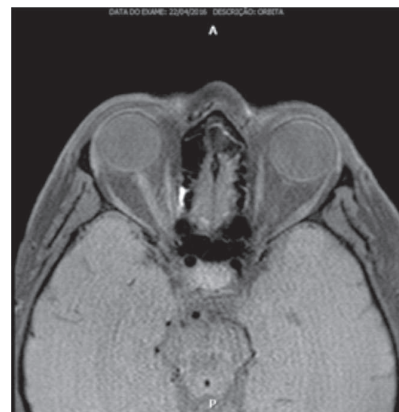

Figure 4: Nuclear magnetic resonance

DISCUSSION

The vast majority of methanol intoxications are due to their ingestion, and the other forms are considered rare.⁽⁵⁾ However, when it comes to labor exposure, inhalation is the most important route, as the patient reported, followed by absorption through the skin. Given this, it is worth mentioning that in the case of labor exposure it can be prevented by the proper use of Personal Protective Equipment (PPE). Serious intoxications with a high mortality rate are always present.^(8,9)

The specific diagnosis of methanol intoxication is given by the measurement of this alcohol in the blood. However, such practice is not available in the clinical routine. In the absence of clinical history, the diagnosis is supported by acidemia with Gap anion and increased osmolar Gap, that is, the osmolality measured is greater than the one calculated.⁽¹⁰⁾ In the patient above the diagnosis was facilitated by the clinical history and characteristic laboratory findings.

The recommended dose is 0.6 to 0.8 g/kg IV, maintaining 130 mg/kg/hour or 10 g/hour, with 1 ml of 100% ethanol being equal to 0.8 g.

It is also possible to use Fomepizol (4-methylpyrazole) to delay the production of toxic metabolites. Although more expensive, this drug should replace the use of ethanol, particularly in cases involving children or people with pancreatitis, and also when there is no laboratory support for a rapid determination of the blood levels of ethanol (for monitoring of the treatment). In addition, ethanol has a higher risk of adverse effects, such as hypoglycemia. The loading dose is 15 mg/kg, followed by 4 doses of 10 mg/kg every 12 hours, and then 15 mg/kg every 12 hours, always via IV in a 30-minute infusion until the serum levels of methanol are below 20mg/dl.

Other measures include favoring the metabolism of the already formed toxin with the administration of folinic acid, which increases the elimination of formic acid (50 to 75 mg every 4 hours, IV for 24 hours).⁽¹¹⁾ 4-methylprednisolone is a competitive inhibitor of alcoholic dehydrogenase as alternative oral therapy.⁽¹²⁾ Correction of acidosis with sodium bicarbonate using 1 to 3 mEq/kg, IV, reducing visual changes in order to hinder the penetration of formic acid in the CNS. In severe cases, hemodialysis to remove methanol and toxic metabolites that are circulating.

As mentioned, in this case the alternative oral administration of 40 ml of whiskey every 4 hours is instituted to mimic the effect of ethanol and compete with formic acid for the affinity with the alcoholic dehydrogenase enzyme, along with the use of sodium bicarbonate for correction of acidosis. Despite the slight change of the standard treatment, the clinical development was satisfactory, considering the improvement of symptoms and stabilization of the laboratory findings.

The initial treatment proposal consisted of multidisciplinary and psychological support, since the patient's work capacity was drastically impaired by the deleterious effects on the visual system and the peripheral nervous system.

The weekly follow-up at the ambulatory was fundamental for clinical support. Progressive visual loss was important, and the campimetric restriction was greatly reduced in both eyes due to peripheral scotoma. The visual acuity developed to improvement in contrast to 20/40 in both eyes with better correction.

REFERENCES

1. Christopher SL, Bradley LD, Jerrold BL. Fatality after inhalation of methanol-containing paint stripper. *Clin Toxicol (Phila)*. 2015; 53(4):411.
2. Barceloux DG, Bond GR, Krenzelok EP, Cooper, Vale JA. The American Academy of Clinical Toxicology Ad Hoc Committee on the Treatment Guidelines for Methanol Poisoning. *Clin Toxicol (Phila)*. 2002; 40(4):415-46.
3. Ernstgard L, Shibata E, Johanson G. Uptake and disposition of inhaled methanol vapor in humans. *Toxicol Sci*. 2005; 88(1):30-8.
4. Givens M, Kalbfleisch K, Bryson S. Comparison of methanol exposure routes reported to Texas Poison Control Centers. *West J Emerg Med* 2008; 9(3):150-5.
5. Badolato ESG, Duran MC. Risco de intoxicação por metanol pela ingestão de bebidas alcoólicas. *Rev Psiquiatr Clín*. 2000; 27(2):90-2.
6. Nogué S, Marruecos L. Guía clínica para el tratamiento de las intoxicaciones por metanol y etilenglicol. *Indicaciones del fomepizol. Reunión de Consenso*. Barcelona; 2006.
7. Trujillo M, Pérez OL, Cerdeiriña DZ, Xarau MN, Junyent SG, Munné Mas JM. Tratamiento com fomepizol de una intoxicación aguda por metanol. *Ver Toxicol*. 2004; 21(1):41-3.
8. Castellanos JL, Limón AB, Hernández AR, Rojas DEF. Intoxicación por metanol, reporte de un caso. *Arch Med Urgencia México*. 2009; 1(2):67-73.
9. Krause IA. Metanol poisonings. *Inensive Care Med*. 1992; 18(7): 391-7.
10. Barceloux DG, Bond GR, Krenzelok EP, Cooper, Vale JA. The American Academy of Clinical Toxicology Ad Hoc Committee on the Treatment Guidelines for Methanol Poisoning. *Clin Toxicol (Phila)*. 2002; 40(4):415-46.
11. Rezende CS, Rezende WW. Intoxicações exógenas. *Rev Bras Med*. 2002; 59(1/2):17-25.

Corresponding author:

Frederico Gustavo Telles e Souza

E-mail: fredts@santacasaolhos.com.br