

Ultra-high resolution optical coherence tomography analysis of bull's eye maculopathy in chloroquine users

Análise da maculopatia em bull's eye pela tomografia de coerência óptica de alta resolução em usuários de cloroquina

Celso Morita¹, Daniel Araujo Ferraz^{2,3}, Thais Zamudio Igami¹, Beatriz Sayuri Takahashi^{1,2}, Tiago Faria e Arantes³, Walter Yukihiko Takahashi⁴

ABSTRACT

Purpose: Register and compare anatomical changes, structural and quantitative found in optical coherence tomography Stratus and Topcon 3D in chronic users of chloroquine. **Methods:** Five patients were diagnosed with toxic "bull's eye" maculopathy was submitted to macular optical coherence tomography examination (Stratus and Topcon 3D). **Results:** Both tools demonstrated an increase reflectivity of choriocapillaris unit just foveal retinal pigment epithelium atrophy. However, Topcon 3D provided to all patients better description of the line corresponding to the transition between inner and outer segments of photoreceptors. Using the possibility of assembling three-dimensional images and subtraction selective retinal layers, we found a lesion with a target that reflects the greater thickness of retinal pigment epithelium in central and parafoveal region that is matched to preserve macular photoreceptors. **Conclusion:** it was observed better resolution and faster image capture by Topcon 3D than Stratus OCT, that provided more detailed analysis of the line corresponding to transition between outer and inner segment of photoreceptors in macular region. With Topcon 3D, it was possible to evaluate soundly the thickness of retinal pigment epithelium in central and parafoveal region that caused an increase reflectivity of choriocapillaris creating a image with a target unpublished before.

Keywords: Chloroquine/toxicity; Tomography, optical coherence/ instrumentation; Tomography, optical coherence/trends; Tomography, optical coherence/utilization; Retina/drug effects; Retinal diseases/diagnosis

RESUMO

Objetivo: Comparar e registrar as alterações quantitativas e qualitativas na tomografia de coerência óptica nos pacientes com uso prolongado de cloroquina. **Métodos:** Avaliaram-se cinco pacientes com diagnóstico de *bull's eye* no exame de tomografia de coerência óptica macular com dois modelos de aparelhos: Stratus e Topcon 3D. **Resultados:** Ambos aparelhos registraram aumento da refletividade coriocalilar foveal provocada pela atrofia do epitélio pigmentar da retina. Somente o Topcon 3D permitiu melhor visualização da linha de transição entre o segmento interno e externo dos fotorreceptores. Este aparelho também permitiu a formação de imagens tridimensionais e subtração das camadas retinianas, com registro da diminuição da espessura do epitélio pigmentado da retina na região central e parafoveal macular. **Conclusão:** Foi possível observar a captação mais rápida e com melhor resolução das imagens geradas pelo Topcon 3D. A diminuição da espessura do epitélio pigmentado da retina, provocando o aumento da refletividade coriocalilar, com a formação de uma imagem linear circular circundando a fóvea, foi mais detalhado pelos cortes realizados no Topcon 3D.

Descritores: Cloroquina/toxicidade; Tomografia de coerência óptica/instrumentação; Tomografia de coerência óptica/tendências; Tomografia de coerência óptica/utilização; Retina/efeitos de drogas; Doenças retinianas/diagnóstico

^{1,2,4}Hospital das Clínicas, Universidade de São Paulo (USP) – São Paulo (SP), Brazil;

³ Fundação Altino Ventura – Recife (PE), Brazil.

The authors declare no conflict of interest.

Received for publication 23/01/2013 - Accepted for publication 23/02/2014

INTRODUCTION

Chloroquine is an antimalarial drug, prescribed for treatment of amebiasis, systemic lupus erythematosus, rheumatoid arthritis and for prophylaxis of malaria. Retinal toxicity with degeneration of neurosensory retina and of retinal pigment epithelium (RPE) as a result of long-term daily use of chloroquine has been well described⁽¹⁻⁵⁾. Most of cases of retinal toxicity have developed when higher than currently recommended dose (3,5 mg/Kg/day using lean body weight) was used⁽⁶⁾.

Paracentral scotoma may be the earliest manifestation of retinal toxicity and may precede the development of any ophthalmoscopic or ERG abnormality⁽⁷⁾. Loss of the foveal light reflex and subtle macular pigment stippling may appear before the development of the classic bull's eye maculopathy, in which a ring of depigmentation surrounded by an area of hyperpigmentation is seen centered on the fovea. Visual acuity decreases when the RPE abnormalities involve the center of the macula. In more severe cases, chloroquine retinopathy develops into the appearance of primary retinal degeneration with narrowed retinal vessels, optic disc pallor and severe visual acuity loss⁽¹⁻⁵⁾.

In the last few years, the optical coherence tomography (OCT) has been used as non-invasive tool to access the macular anatomical status in many macular diseases⁽⁸⁾. Spectral domain OCT (SD OCT) enhances the visualization of intraretinal architectural morphology relative to time domain OCT in many retinal diseases including cases of retinal toxicity⁽⁹⁻¹³⁾. SD OCT also provides 50-70 times faster data acquisition that enables visualization in entire cubes that can be viewed in three dimensions and also gives a single-layer surface maps of RPE. SD OCT images with 5 microns of transverse resolution also enables better visualization of the inner segment and outer segment (IS/OS) photoreceptor (PR) junction and RPE, leading to a different understanding of pathogenic mechanisms for retinal diseases⁽¹⁰⁻¹²⁾.

METHODS

From february 2008 to march 2009, 234 patients, chronic users of chloroquine, were referred to ophthalmologic examination. Of these, five were diagnosed with toxic "bull's eye" maculopathy. This diagnosis was based on historical chronic use of chloroquine, angiographic and fundus findings. These patients also underwent measurement of visual acuity logMAR in best corrected (on the scale of the Early Treatment Diabetic Retinopathy Study - ETDRS) and macular OCT (Stratus OCT and Topcon 3D OCT). It was considered both eyes of each patient for analysis statistics, except in a patient with macular edema after cataract surgery in one eye. To obtain the images with Stratus OCT version 4.0 (Carl Zeiss Meditec) scans were used Linear 5mm through the fovea in the vertical and horizontal fast retinal map. In Topcon 3D OCT, scans were performed in program linear (cross hair) and maps retinal (retinal map). We compared anatomical changes, structural and quantitative found in OCT Stratus and Topcon 3D. Using these parameters in Topcon 3D OCT, were analyzed three-dimensional maps of the surface of RPE. The Ethics Committee approved the study.

RESULTS

Demographic data of 5 patients are shown in table 1. Qualitative analysis of images obtained with both devices showed absence of changes in the vitreous-retinal interface in all patients. Foveal depression is present but with angled edges more acute in relation RPE line. Evaluation of neurosensory retina is hampered by a marked decrease in this layer fovea. Both tools demonstrated an increase reflectivity of choriocapillaris by absence of blocking light in caused by just foveal RPE atrophy. However, Topcon 3D OCT provided to all patients better description of the line corresponding to the transition between inner and outer segments of photoreceptors. Both machines devices enabled to detected reduction of macular thickness and volume in 9 eyes examined. Using tridimensional analysis, when part of the neu-

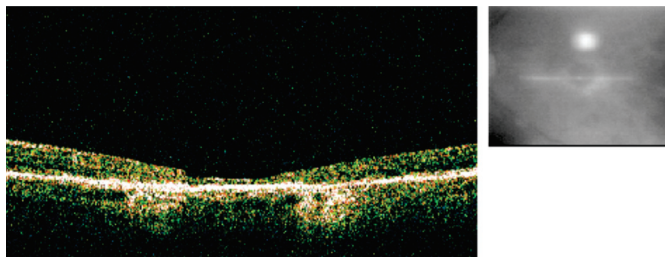


Figure 1: Stratus OCT linear scan with just foveal RPE atrophy

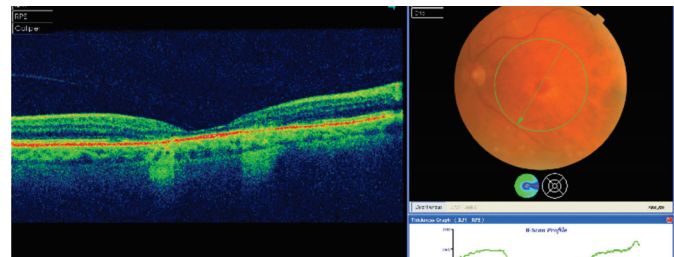


Figure 2: Topcon 3D OCT linear scan with the line corresponding to the transition between inner and outer segments of photoreceptors

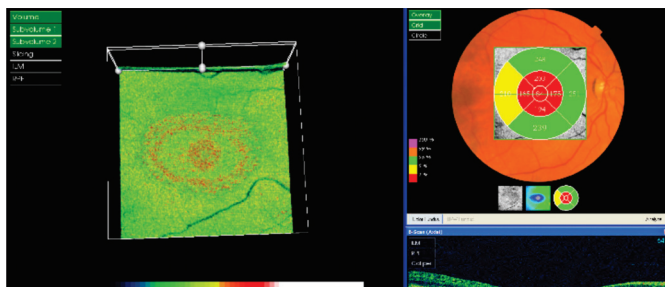


Figure 3: Analyzed three-dimensional map of the surface of RPE with central and paracentral rings show a complex RPE-PR more thinning

rosensory retina is subtracted (internal limiting membrane to outer limiting membrane), were observed a novel target in an image where the central and paracentral rings show a complex RPE-PR apparently more thinning (figures 1-3).

DISCUSSION

Optical coherence tomography has revolutionized the diagnosis and treatment of retinal diseases in last years. Macular thickness decrease using OCT in bull's eye maculopathy of chloroquine users has been documented in previous studies⁽¹³⁾, and was confirmed by both the devices used in this study. In this paper, the better resolution and faster image capture by SD OCT provided more detailed analysis of the line corresponding to transition between outer and inner segment of photoreceptors in macular region. Because of the possibility of assembling three-dimensional images and subtraction selective retinal layers, we found an unpublished document, a lesion with a target that reflects the greater thickness of RPE in central and parafoveal region that is matched to preserve macular photoreceptors.

It was possible to correlate the areas where the target pattern is less evident with thinning of the neurosensory retina in same location, which may indicate that the pattern observed in RPE target will be the "paid" with disease's progression. Thus, in near future, a comparative analysis of three-dimensional graphics of RPE may enable the analysis of progression of maculopathy in bull's eye induced by chloroquine.

REFERENCES

1. Hobbs HE, Eadie SP, Somerville F. Ocular lesions after treatment with chloroquine. *Br J Ophthalmol.* 1961;45 (4):284-97.
2. Hobbs HE, Sorsby A, Freeman A. Retinopathy following chloroquine therapy. *Lancet*, 1959;2(7101):478-80.
3. Marks JS. Chloroquine retinopathy: is there a safe daily dose? *Ann Rheum Dis.* 1982;41(1):52-8.
4. Nylander U. Ocular damage in chloroquine therapy. *Acta Ophthalmol.* (Copenh).1967;Suppl 92:1-71.
5. Okun E, Gouras P, Bernstein H, Von Sallmann L. Chloroquine retinopathy: a report of eight cases with ERG and dark-adaptation findings. *Arch Ophthalmol.* 1963;69:59-71.
6. Ochsendorf FR, Runne U. Chloroquine: consideration of maximum daily dose (3.5 mg/kg ideal body weight) prevents retinopathy. *Dermatology.* 1996;192(4):382-3.
7. Hart WM Jr, Burde RM, Johnston GP, Drews RC. Static perimetry in chloroquine retinopathy. Perifoveal patterns of visual field depression. *Arch Ophthalmol.* 1984 ;102(3):377-80.
8. Huang D, Swanson EA, Lin CP, Schuman JS, Stinson WG, Chang W, et al. Optical coherence tomography. *Science.* 1991;254(5035):1178-81.
9. Witkin AJ, Ko TH, Fujimoto JG, Chan A, Drexler W, Schuman JS, et al. Ultra-high resolution optical coherence tomography assessment of photoreceptors in retinitis pigmentosa and related diseases. *Am J Ophthalmol.* 2006;142(6):945-52.
10. Ko TH, Fujimoto JG, Schuman JS, Paunescu LA, Kowalevicz AM, Hartl I, et al. Comparison of ultrahigh- and standard-resolution optical coherence tomography for imaging macular pathology. *Ophthalmology.* 2005;112(11):1922.e1-15.
11. Drexler W, Sattmann H, Hermann B, Ko TH, Stur M, Unterhuber A, et al. Enhanced visualization of macular pathology with the use of ultrahigh-resolution optical coherence tomography. *Arch Ophthalmol.* 2003;121(5):695-706.
12. Wojtkowski M, Srinivasan V, Fujimoto JG, Ko T, Schuman JS, Kowalczyk A, et al. Three-dimensional retinal imaging with high-speed ultrahigh-resolution optical coherence tomography. *Ophthalmology.* 2005;112(10):1734-46.
13. Rodriguez-Padilla JA, Hedges TR 3rd, Monson B, Srinivasan V, Wojtkowski M, Reichel E, et al. High-speed ultra-high-resolution optical coherence tomography findings in hydroxychloroquine retinopathy. *Arch Ophthalmol.* 2007;125(6):775-80.

Corresponding Author:

Celso Morita, MD.
 Faculdade de Medicina da Universidade de São Paulo
 Av. Dr. Enéas de Carvalho Aguiar, 255 – Cerqueira César
 Zip code: 05403-000, São Paulo (SP), Brazil
 Phone: 55-11-30697871; fax: 55-(11) 3069-7871
<http://www.hcnet.usp.br>
 E-mail: ceslomor@uol.com.br