

A case of atypical *nocardia asteroides* sclerouveitis resistant to fourth-generation fluoroquinolones

Um caso atípico de esclero-uveíte por Nocardia Asteroides resistente a fluorquinolona de quarta-geração

Túlio Frade Reis¹, Marina Labarrère de Albuquerque¹, Vânia Martins Ribeiro Hummel¹, João Eudes Filho¹, Patrick Frensel Tzelikis¹

ABSTRACT

We describe an unusual case of Nocardia spp scleritis in a health girl resistant to topical fourth-generation fluoroquinolones. Clinically, there was only partial response of the scleritis to initial therapy. Treatment was changed to meropenem intravenously and topical amikacin. Following several weeks of antibiotic treatment, the patient's infection resolved but her vision was reduced to no light perception. Nocardia asteroides must be considered as a possible agent in cases of necrotizing scleritis in patients without a clear source. Antibiotic sensitivity testing has a definitive role in view of the resistance to these new medications.

Keywords: Scleritis/microbiology; Scleritis/pathology; Scleritis/therapy; Nocardia asteroides/isolation & purification; Fluoroquinolones; Eye infections/microbiology; Drug resistance; Case reports

RESUMO

Nós descrevemos um raro caso de esclerite por *Nocardia spp* em uma criança sadia resistente a utilização tópica de fluorquinolona de quarta-geração. Clinicamente, a paciente apresentou apenas uma resposta parcial do quadro de esclerite a terapêutica inicial. O tratamento foi então modificado para meropenem intravenoso e amicacina tópica. Após várias semanas de tratamento com antibiótico, o quadro infeccioso regrediu porém a visao da pacientes evoluiu para perda da percepção luminosa. Em casos de esclerite necrotizante em pacientes sem fatores de risco aparente é necessário considerar a *Nocardia Asteroides* como possível agente causador. Os testes de sensibilidade medicamentosa apresentam importância significativa em virtude do aparecimento de resistência aos novos medicamentos.

Descritores: Esclerites/microbiologia; Esclerites/patologia; Esclerites/terapia; *Nocardia asteróides*/isolamento & purificação; Fluoroquinolonas; Infecções oculares/microbiologia; Resistência a medicamentos; Relatos de caso

¹Hospital de Base do Distrito Federal, Brasília, DF, Brazil.

Presented as a poster at the 2015 World Cornea Congress, San Diego, CA, USA, April 15-17.

The authors declare no conflicts of interests.

Received for publication 12/03/2015 - Accepted for publication 28/06/2015

INTRODUCTION

The diverse aetiology of scleritis is well illustrated by the large number of infections and local and systemic diseases that have been described to either cause or be associated with scleritis.¹ A number of studies show the varying frequency and pattern of infectious scleritis. The severe inflammation and destructive nature of scleritis often spreads to involve adjacent structures, most commonly the cornea and uvea.

Nocardia species, soilborne aerobic actinomycetes with worldwide distribution, can cause local or disseminated infections in humans.² The different species (*N. asteroides*, *N. brasiliensis*, *N. farcinica*, *N. nova*, *N. otitidiscaviarum*, *N. transvalensis*) have all been associated with human disease, but each has a different virulence and pattern of antibiotic resistance.³

We report a case of microbial sclerouveitis, with isolation of the organism *Nocardia asteroides* from subconjunctival abscess that did not respond to topical moxifloxacin.

CASE REPORT

A 7-year-old black girl was referred to the cornea unit at our hospital with persistent ocular pain and photophobia in her left eye. She presented previously to another service with a 4-week history of gradual onset ocular pain and redness. At that time, the patient began taking 0.3% tobramycin and 0.1% dexamethasone (Tobradex®) drops four times a day. Her eye did not improve, and few weeks later, she was referred to the cornea service. She was otherwise quite well with no systemic symptoms. She had no previous history of ocular disease, surgery, or trauma and did not wear contact lenses. She general medical history was unremarkable.

On examination at our hospital, uncorrected visual acuity (UCVA) was found to be 20/20 right eye and 20/60 in the left eye. The right eye was normal. Slit-lamp examination of the left eye revealed an inflamed conjunctiva adjacent to the nasal limbus and a white subconjunctival mass lesion extending to the peripheral cornea. The anterior chamber was deep with a whitish nodule on corneal endothelium (Figure 1). Examination of posterior segment was unremarkable. Autoimmune, metabolic, and infectious causes were all considered. A swab culture of the suppurative material of the left eye was performed. Hematologic studies revealed an erythrocyte sedimentation rate of 40 mm/h with a normal C-reactive protein, and autoantibodies including rheumatoid factor were negative. Mantoux testing was negative and a chest radiograph was clear.

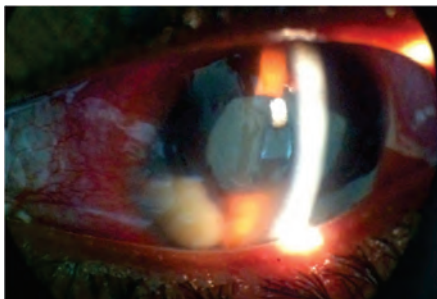


Figure 1: *Nocardia asteroides* scleritis. Slit lamp examination: left eye, with inflamed conjunctiva adjacent to the nasal limbus and a anterior chamber exudate.

Infectious sclerouveitis was diagnosed and the patient started using 0.5% topical moxifloxacin and ointment of ciprofloxacin every 2 hours. Five days later, the uveitis did not resolve and 1% prednisolone was added to the treatment regimen when the cultures were reported as negative. During the next 2 weeks, the patient's was reviewed regularly and her condition worsened (Figure 2). The patient had severe pain and photophobia, the visual acuity in her left eye had decreased to 20/400, and the conjunctival injection had also worsened. At this time, use of all eye drops was stopped, topical corticosteroids was ceased and the cornea was recultured 24 hours late.

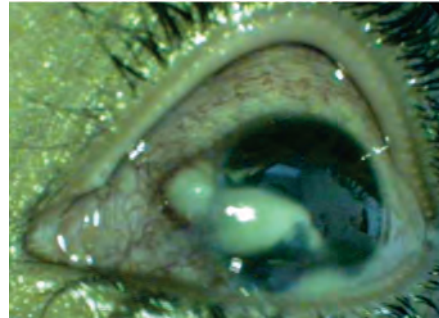


Figure 2: *Nocardia asteroides* scleritis A small scleral nasal abscess with associated purulent material noted centrally.

After one week, the culture showed a gram-positive bacillus identified as *Nocardia asteroides* (Figure 3), she was admitted to the hospital and treatment was changed to 2.5% topical amikacin administered hourly around the clock and intravenous (IV) meropenem.

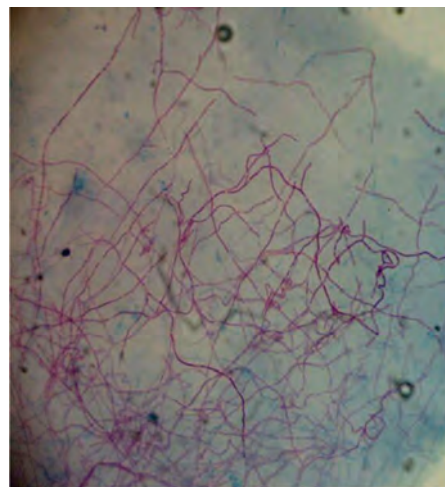


Figure 3: Scleral scrapings stained with 1% acid-fast stain showing acid fast, beaded, branched filamentous organisms.

Sensitivity testing revealed resistance to moxifloxacin and oxacillin. The culture results also demonstrated that the *Nocardia asteroides* was sensitive to both amikacin and meropenem. After 14 days of IV meropenem, the patient showed no evidence of active scleritis. At this time, 160 mg of oral trimethoprim and 800 mg of sulfamethoxazole was added twice a day to the regimen. Six months later, the patient has remained clinically free of disease, had no pain complain, but her visual acuity was no light perception with signs of phthisis bulbi.

DISCUSSION

We describe an interesting case of infectious scleritis. Fewer cases of Nocardial necrotizing scleritis have been reported in the literature. Microbial scleritis is an infrequent ocular infection. According to Cunningham et al.⁴ the prevalence of primary bacterial or fungal scleritis among patients with scleritis is estimated to be 1.7%.

Nocardia asteroides is a gram-positive branching filamentous organism. It has been described as causing opportunistic infections, usually occurring in immunosuppressed patient or after surgery and trauma.⁵⁻⁶ Pterygium removal is the most common inciting factor of infectious scleritis in many studies.⁷⁻⁹ In the present case, the patient was in good general health and denied trauma or prior ocular surgery.

With respect to etiologies, the majority of cases reported in the literature were due to a bacterial infection (53%-100%), with *Pseudomonas aeruginosa* being the most commonly reported causative organism.^{7,8,10} Other bacteria isolated included *Staphylococcus aureus*, *Staphylococcus epidermidis*, *Streptococcus pneumoniae*, *Mycobacterium sp.*, and less frequently *Nocardia sp.*⁷⁻¹¹

The interval from onset of symptoms to diagnosis was 46 days. The largest study of infectious scleritis in Medline is that of Hodson et al.⁷ who reviewed 56 cases of infectious scleritis and observed that fungal, nocardial, and mycobacterial infections had a longer interval between symptoms and diagnosis (median 17-45 days) than eyes with non-acid-fast gram positive and gram-negative bacteria (median 7 days). However, the authors did not find that this delay had a detrimental effect on final visual acuity.

Vision-limiting sequelae of infectious scleritis include glaucoma, cataract, choroidal effusion, exudative retinal detachment, and phthisis bulbi. In a literature review of reported cases of infectious scleritis, approximately 60% of the eyes were eviscerated, enucleated, or were left with no light perception despite intensive treatment.¹⁰ Hodson et al.⁷ reported that removal of the eye was necessary in one fourth of patients with microbial scleritis because of progressive inflammation, and 50% of the affected eyes lost functional vision (worse than 20/200). At the last follow-up our patient presented with phthisis bulbi. Depending on the stage and severity of the infection, many cases are quiet amenable to medical treatment.¹⁰ Urbano et al.¹¹ described one case of *Nocardia asteroides* scleritis treated successfully with topical amikacin resulting in a stable area of scleral thinning and a final visual acuity of 20/20.

In conclusion, *Nocardia* organism should be kept in mind as a possible causative agent of any case of infectious scleritis

even in patients with good general health and no history of trauma or prior ocular surgery. The treatment result of this case was not favorable probably because of diagnosis delay. A high degree of clinical suspicion, with appropriate diagnostic tests can help early diagnosis and treatment in order to achieve the best possible outcome.

REFERENCES

1. Okhravi N, Odufuwa B, McCluskey P, Lightman S. Scleritis. *Surv Ophthalmol.* 2005; 50(4):351-63.
2. Brown-Elliott BA, Brown JM, Conville PS, Wallace RJ Jr. Clinical and laboratory features of the *Nocardia* spp. based on current molecular taxonomy. *Clin Microbiol Rev.* 2006; 19(2):259-82.
3. Boiron P, Provost F, Chevrier G, Dupont B. Review of nocardial infections in France 1987 to 1990. *Eur J Clin Microbiol Infect Dis.* 1992;11(8):709-14.
4. Cunningham MA, Alexander JK, Matoba AY, Jones DB, Wilhemus KR. Management and outcome of microbial anterior scleritis. *Cornea.* 2011;30(9):1020-3.
5. Sridhar MS, Sharma S, Reddy MK, Mruthyunjay P, Rao GN. Clinicomicrobiological review (of *Nocardia* keratitis. *Cornea.* 1998; 17(1):17-22.
6. Rao SK, Madhavan HN, Sitalakshmi G, Padmanabhan P. *Nocardia Asteroides* keratitis: report of seven patients and literature review. *Indian J Ophthalmol.* 2000;48(3):217-21. Review.
7. Hodson KL, Galor A, Karp CL, Davis JL, Albin TA, Perez VL, Miller D, Forster RK. Epidemiology and visual outcomes in patients with infectious scleritis. *Cornea.* 2013;32(4):466-72.
8. Jain V, Garg P, Sharma S. Microbial scleritis-experience from a developing country. *Eye (Lond).* 2009; 23(2):255-61.
9. Alfonso E, Kenyon KR, Ormerod LD, Stevens R, Wagoner MD, Albert DM. *Pseudomonas* corneoscleritis. *Am J Ophthalmol.* 1987 ;103(1):90-8.
10. Reynolds MG, Alfonso E. Treatment of infectious scleritis and kerato-scleritis. *Am J Ophthalmol.* 1991; 112(5):543-7.
11. Urbano AP, Urbano AP, Torigoe AM, Urbano I, kara-José N. Esclerite infecciosa espontânea por *Nocardia asteroides*: relato de caso. *Arq Bras Oftalmol.* 2003; 66(2):223-5.

Corresponding author:

Patrick Frensel Tzelikis
Avenida L2 Dul, SGAS 607, módulo G, Hospital Oftalmológico de Brasília – HOB – 70200-670
E-mail: tzelikis@gmail.com