

Glaucoma-simulating cupping in a patient with periventricular leukomalacia: a clinical case report

Escavação simulando glaucoma em paciente com leucomalácia periventricular: relato de caso clínico

Patricia Amaris Tatis¹ , Eduardo Rojas Alvarez² 

¹ Clínica Oftalmológica del Caribe, Barranquilla, Colombia.

² Universidad de Cuenca, Centro Oftalmológico Exiláser, Cuenca, Ecuador.

How to cite:

Tatis PA, Alvarez ER. Glaucoma-simulating cupping in a patient with periventricular leukomalacia: a clinical case report. Rev Bras Oftalmol. 2023;82:e0020.

doi:

<https://doi.org/10.37039/1982.8551.20230020>

Keywords:

Glaucoma; Leukomalacia, periventricular; White matter; Visual fields

Descritores:

Glaucoma; Leucomalácia periventricular; Substância branca; Campos visuais

Received on:

Dec 12, 2022

Accepted on:

Jan 24, 2023

Corresponding author:

Eduardo Rojas Alvarez
Federico Proaño 4-26 y Remigio Crespo
Cuenca, Ecuador.
E-mail: drejasalvarez@gmail.com

Institution:

Clínica Oftalmológica del Caribe,
Barranquilla, Colombia.

Conflict of interest:

the authors declare no conflict of interest.

Financial support:

the authors received no financial support
for this work.



Copyright ©2023

ABSTRACT

Non-glaucomatous papillary cupping constitutes an important differential diagnosis in daily medical practice. There are patients diagnosed and treated as glaucoma, who do not present the disease and are part of the large group of non-glaucomatous optic neuropathies. This case emphasizes directing the diagnostic gaze to these “apparently glaucomatous” optic nerves through a case of periventricular leukomalacia. Patients with a history of prematurity, alterations in the cerebral white matter and presence of optic nerve excavations with normal intraocular pressures.

RESUMO

A escavação papilar não glaucomatosa constitui um importante diagnóstico diferencial na prática médica diária. Há pacientes que recebem o diagnóstico de e tratamento para glaucoma, que não apresentam a doença e fazem parte do grande grupo de neuropatias ópticas não glaucomatosas. Este caso enfatiza o direcionamento do olhar diagnóstico para nervos ópticos “aparentemente glaucomatosos” através de um episódio de leucomalácia periventricular. Pacientes com histórico de prematuridade, alterações na substância branca do cérebro e presença de escavações do nervo óptico com pressões intraoculares normais.

INTRODUCTION

In the ophthalmological clinical practice, we observe different entities that have in common the presence of an enlarged optic cup. The association of a normal-sized optic disc with a large cup is of clinical importance for the diagnosis of optic neuropathy. Of these neuropathies, 80% are of glaucomatous origin, the rest can have ischemic, inflammatory, infectious, toxic, metabolic and traumatic causes.

All neuropathies will show changes suggestive of glaucoma in its different phases, so it is challenging to make a differential diagnosis, such as congenital neuropathies acquired from optic nerve neuropathies in the clinical evaluation. Acquired causes of non-glaucomatous cupping include: compressive optic neuropathy, ischemic optic neuropathy, optic neuritis, optic atrophy, and other neuropathies. The cupping optic nerve should be evaluated in relation to all the findings of an optimal clinical history.

CASE REPORT

Female patient, 17-year-old, Caucasian, presented to ophthalmology in 2016 in Ophthalmological Clinic of the Caribbean, Barranquilla, Colombia.

The optic nerve demonstrated enlarged cupping and abnormal visual field using Humphrey field analyzer (HFA) and optical coherent tomography (OCT, Topcon Corporation, Japan). The patient was born at 27 weeks' gestation, with a birth weight of 800g, by cesarean, stayed 6 weeks in the intensive care unit with the presence of

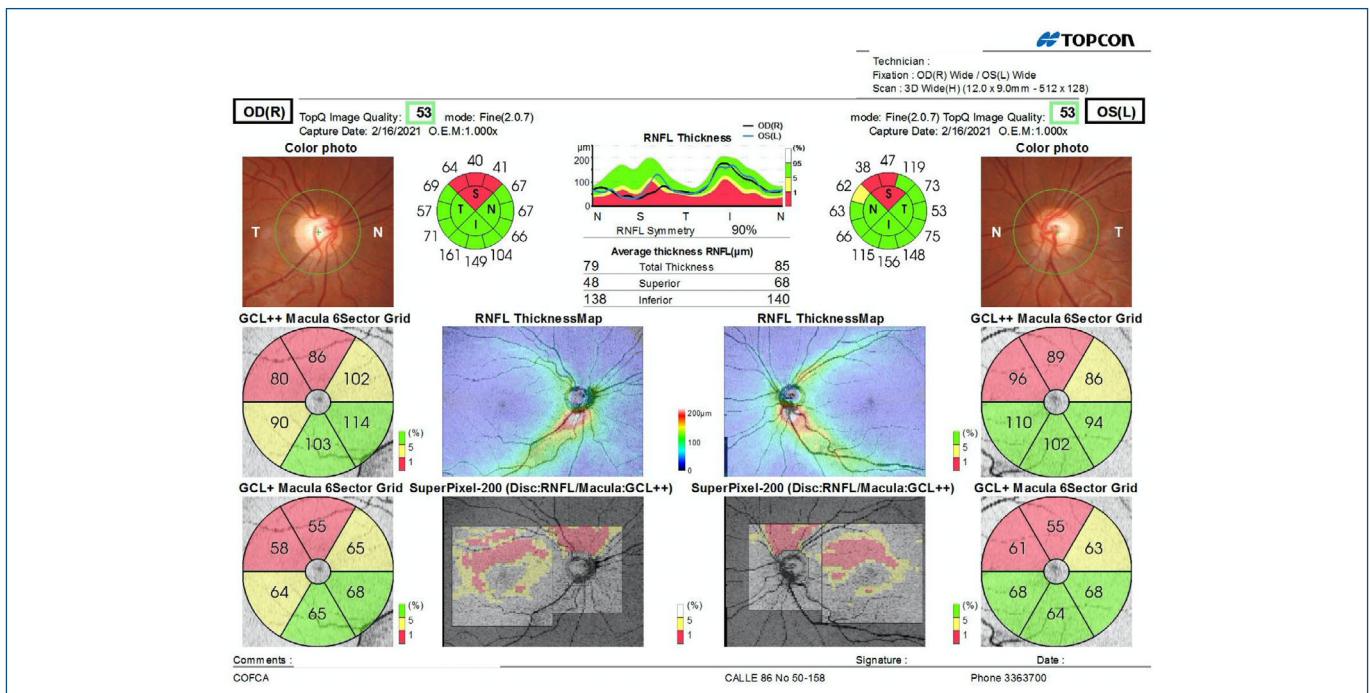
intraventricular hemorrhage and prematurity retinopathy with spontaneous regression. Since early age, she had difficulty to walk. During early childhood, she was treated in the pediatric ophthalmology for the presence of alternating exotropia, with occlusive treatment and lenses.

Visual acuity without lenses was 20/200 in the right eye and 20/80 in the left eye. The best corrected visual acuity with ES: -2.25 -1.50x160° was in her right eye 20/20 and : N -1.50x180° was in her left eye 20/20. Intraocular pressure measurements with Goldman was 13mmHg in both eyes. Extra ocular movements were full, with a small angle exotropia. The anterior chamber was normal.

Gonioscopy showed open angle (D40R in all quadrants) with Spaeth classification in both eyes. Optic nerve examinations demonstrated an enlarged and symmetrical cup to disc ratio (0.7/0.6), with a greater horizontal diameter, and the superior neuroretinal rim was thinner than the inferior rim.

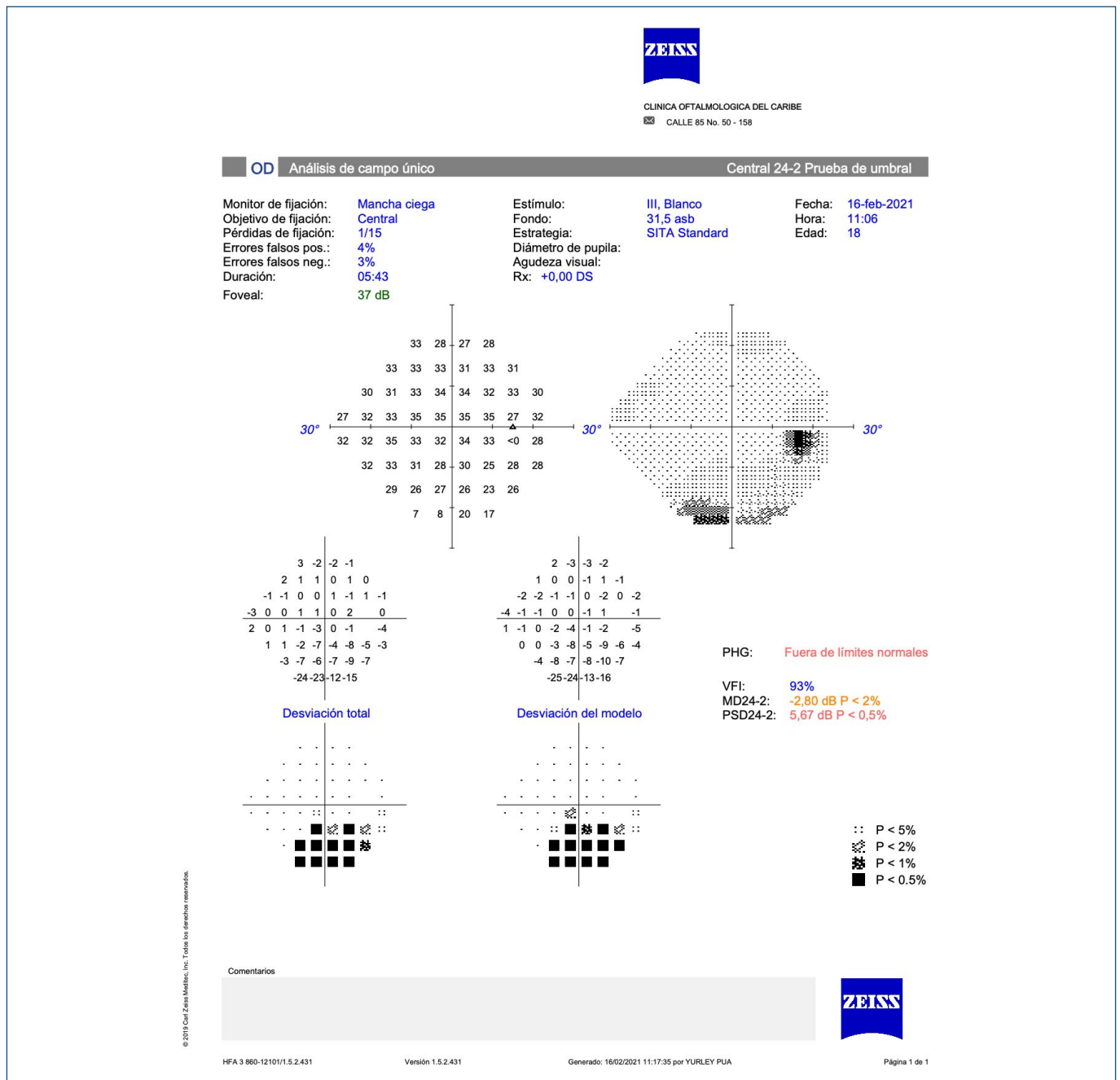
Optical coherent tomography showed a symmetric decrease in the average number of nerve fiber layers in both eyes - right eye: 70µm; left eye: 73µm. Thinning was most prominent superiorly with cup-disc ratio: right eye: 0.71, left eye: 0.65 (Figure 1).

The visual field SITA (Swedish Interactive Thresholding Algorithm) strategy, standard version, test 24-2, demonstrated inferior incomplete arcuate scotoma (crossed the vertical midline bilaterally) in both eyes and corresponded to the structural damage (Figure 2).



OD: right eye; OS: left eye; GCL: Ganglion cell layer; RNFL: Retinal nerve fiber layer.

Figure 1. Optical coherence tomography.



OD: right eye; PHG: glaucoma hemifield test; VFI: Visual field index; MD: mean deviation; PSD: pattern standard deviation.

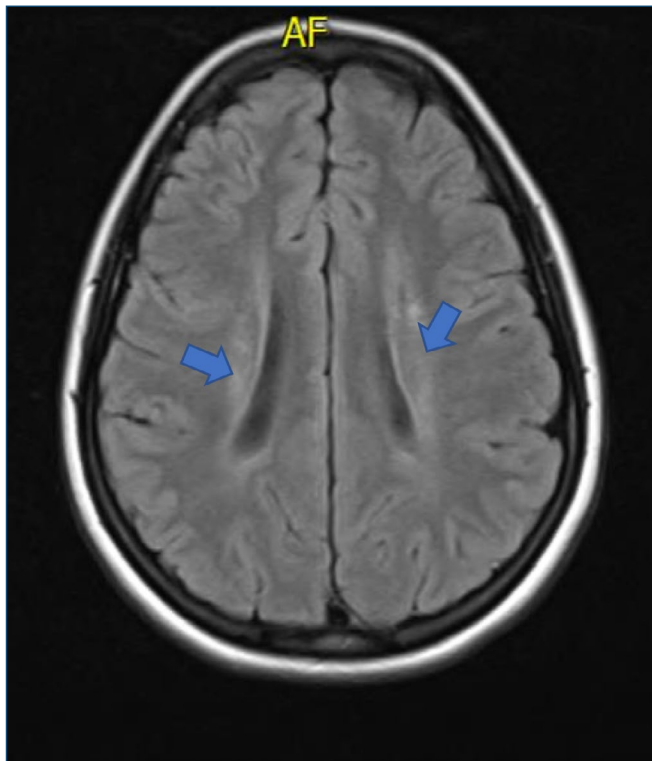
Figure 2. Computerized visual field. SITA (Swedish Interactive Thresholding Algorithm) strategy, standard version, test 24-2.

With the presence of predominantly horizontal, symmetrical cupping, normal intraocular pressures, thinning of the upper nerve fiber layer in both eyes, visual field defects, which corresponds to the nerve fiber defects (arcuate scotoma that crosses the midline lower), in addition to the absence of a family history of glaucoma and the non-use of steroids, the cupping was defined as non-glaucomatous. Because of the birth of prematurity and associated alterations, a magnetic resonance imaging (MRI) without contrast was obtained and Neurology consultation with a

presumptive diagnosis of sequelae of prematurity, suspicion of periventricular leukomalacia (PVL).

Magnetic resonance imaging showed the presence of periventricular white matter lesions consistent with PVL (Figure 3). In addition, motor integration disorders confirm the diagnosis of PVL.

We examined the patient every year. The last exam was in 2022, almost 4 years after this baseline studies. Visual acuity best corrected with -2.75 -1.70x170° and -0.50 -1.75x180° were 20/20 in both eyes. The intraocular



AF: fractional anisotropy.

Figure 3. Magnetic resonance imaging.

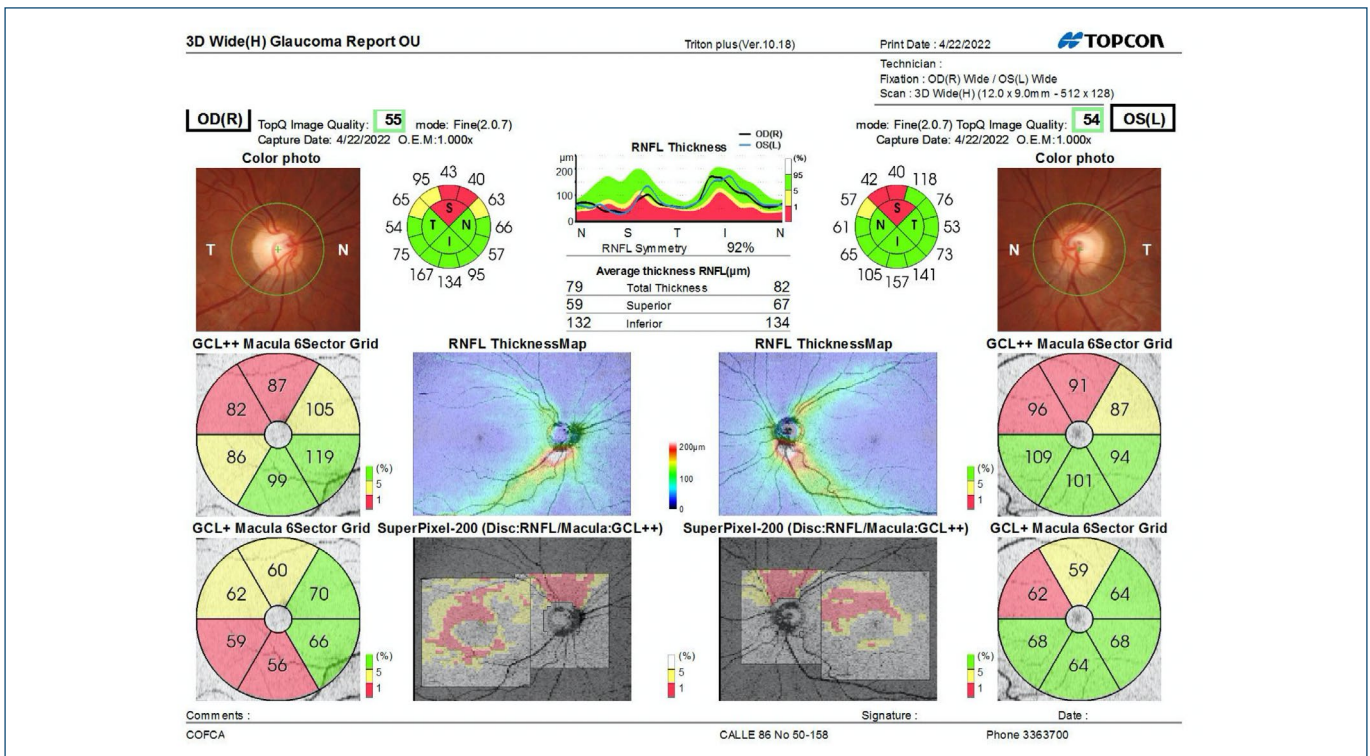
pressure with Goldman was 12mmHg in both eyes, the central corneal thickness was 582µm and 565µm in the right and left eye respectively. Optic nerve cupping was unchanged on appearance and gonioscopy showed D4of

Spaeth classification in both eyes. The retinal nerve fiber layer (RNFL) evaluation was stable on the last OCT and visual field examination shows stability. Optical coherence tomography and visual field were consistent with 2018 exams (Figure 4).

DISCUSSION

Increased cupping in formerly premature children was first described in the late 1970s.⁽¹⁾ Park et al. described the longitudinal progression of cups in children from infancy to 10 years of age, showing an increased number of cups in the preterm cohort before the start of high-quality neuroimaging.⁽²⁾

PVL is a disease where the white matter around the lateral ventricles becomes thinner, associated with hypoxic-ischemic events in a developing brain, worsened by infection or inflammation. This condition occurs in 32% of premature newborns. It is believed to develop between 24-34 weeks of gestation.^(3,4) PVL is known to cause pseudoglaucomatous cups due to transsynaptic degeneration of axons, followed by intrauterine injury from optic radiations.^(5,6) Clinically, it can cause decreased visual acuity, lower visual field constriction, visual cognitive impairment, ocular motility disturbances, and spastic diplegia.^(6,7) Motor deficits are often obvious, visual disturbances often go undetected or are misdiagnosed as they are



OD: right eye; OS: left eye; GCL: Ganglion cell layer; RNFL: Retinal nerve fiber layer.

Figure 4. Optical coherence tomography (3 year later).

not immediately apparent. Brodsky described optic discs of normal size with large optic cups and thin neuroretinal rings in patients with PVL.⁽⁸⁾

PVL is one of the most difficult differential diagnoses to be established in the presence of papillary cupping, especially due to scientific and technical advances in perinatal care. The number of premature patients who reach adulthood is increasing and present with papillary excavations and a history of prematurity.^(3,4) Given the clinical finding of excavation in young patients or adults, with normal intraocular pressures, the presence of alterations in OCT and visual field, with open angles is, in most cases, diagnosed as normal tension glaucoma. Birth history is of vital importance. In the presence of papillary cupping, we mostly inquire about family history of glaucoma and associated diseases. Questions about prematurity are not usually asked.

Large optic cups can mimic glaucoma, but a history of prematurity, normal intraocular pressure, and characteristic symmetrical lower visual field defects are elements that allow us to distinguish PVL from glaucomatous optic atrophy.⁽⁷⁾

Periventricular leukomalacia is a structural loss of the white matter pathways that carry visual information from the lateral geniculate bodies to the visual cortex. Its incidence is approximately 10% in preterm infants <32 weeks of gestation. Risk factors include gestational age, intrauterine infection, premature rupture of membranes, and chorioamnionitis. The prevalence in children under 28 weeks is 39.6%; 27.4% in less than 32 weeks and 7.3% in less than 37 weeks.⁽⁸⁾ The imaging diagnosis is made by RMI, which shows a homogeneous lesion pattern of white matter damage due to immaturity.⁽⁵⁻⁷⁾

Careful examination of the optic nerve will help differentiate it from glaucomatous cupping. Specifically, the papillary cup is larger in the horizontal diameter with little or no nasal displacement. Optical coherence tomography abnormalities are most often at the superior pole of the optic nerve with inferior visual field defects.

Cases have also been reported with decreased visual acuity, nystagmus, ocular motility disorders, mental retardation or normal intelligence, and alterations in psychomotor development, which may remain as sequelae in adulthood, as in the case presented. Therefore, children, adolescents or adults with PVL can present to the ophthalmologist within a clinical spectrum that can range from severe cerebral visual impairment in combination with cerebral palsy and mental retardation to only early-onset esotropia, normal intellectual level and without cerebral palsy.⁽⁶⁻⁹⁾ Three cases similar to our case have been reported in the literature.⁽¹⁻⁸⁾

The differential diagnosis of optic neuropathies with cupping continues to be a difficult topic to address in clinical practice, due to the variety of nosological entities included and the similar forms of presentation. It is essential for the clinicians to differentiate glaucomatous from non-glaucomatous optic disc cupping. Periventricular Leukomalacia should be considered as the differential diagnosis of Normal-tension in patients with history of prematurity.

REFERENCES

1. Fledelius H. Optic disc cupping and prematurity. Large cups as a possible low birth weight sequel. *Acta Ophthalmol (Copenh)*. 1978;56(4):563-73
2. Park JW, Park SW, Heo H. RetCam image analysis of the optic disc in premature infants. *Eye (Lond)* 2013;27(10): 1137-41.
3. Groth SL, Sean PD, Reddy A, Sarma A, Wushensky C. Periventricular Leukomalacia in Patients With Pseudo-glaucomatous Cupping. *Am J Ophthalmol*. 2020;211:31-41.
4. Kayaarasi Ozturker Z, Akar S. Periventricular leukomalacia mimicking normal-tension glaucoma: a case report. *Clin Exp Optom*. 2021 Sep;104(7):807-8.
5. Brodsky MC. Periventricular leukomalacia: an intracranial cause of pseudoglaucomatous cupping. *Arch Ophthalmol*. 2001;119(4):626-7.
6. Jacobson LK, Dutton GN. Periventricular leukomalacia: an important cause of visual and ocular motility dysfunction in children. *Surv Ophthalmol*. 2000;45(1):1-13.
7. Lennartsson F, Nilsson M, Flodmark O, Jacobson L. Damage to the immature optic radiation causes severe reduction of the retinal nerve fiber layer, resulting in predictable visual field defects. *Invest Ophthalmol Vis Sci*. 2014;55(12):8278-88.
8. Brodsky MC. Normal-tension glaucoma or PVL? *Ophthalmology*. 2010;117(3):640-1.
9. Longmuir SQ, Brodsky MC. Postnatal optic disc cupping in a non-glaucomatous infant with periventricular leukomalacia: nosologic implications. *Br J Ophthalmol*. 2012;96(4):606-7.