

Bilateral descemet membrane detachment in femtosecond laser-assisted cataract surgery

Descolamento de descemet bilateral em cirurgia de catarata com laser de femtosegundo

Bruna Vieira Ventura^{1,2,3}, Fernanda Silvestre Ribeiro da Costa Gomes¹, Laura Portela Rabello¹, Marcelo Carvalho Ventura^{1,2}

ABSTRACT

We report an unusual case of a 65-year old patient that developed localized bilateral Descemet membrane detachment during non-simultaneous femtosecond laser-assisted cataract surgery (FLACS). The detachment occurred when the laser was performing the secondary incision. In the operating room, the isolate-and-release technique was used to effectively manage this complication. To the best of our knowledge, this is the first reported case of bilateral Descemet membrane detachment during FLACS.

Keywords: *Descemet membrane; Intraoperative complications; Cataract extraction; Phacoemulsification; Lasers*

RESUMO

Relatamos um caso de uma paciente de 65 anos de idade que evoluiu com descolamento de Descemet localizado bilateral durante cirurgias de catarata não simultâneas com laser de femtosegundo. O descolamento ocorreu durante a realização da paracentese pelo laser. Na sala cirúrgica, foi utilizada a técnica de “isolar e liberar” para conduzir eficazmente esta complicação. De acordo com o nosso conhecimento, esse é o primeiro relato de caso de descolamento bilateral da membrana de Descemet durante cirurgia de catarata com laser de femtosegundo.

Descritores: Membrana de Descemet; Complicações intraoperatórias; Extração de catarata; Facoemulsificação; Lasers

¹Altino Ventura Foundation, Recife, PE, Brazil.

²HOPE Eye Hospital, Recife, PE, Brazil.

³Department of Ophthalmology, Universidade Federal de São Paulo, São Paulo, SP, Brazil.

The study was performed at the Altino Ventura Foundation, in Recife, Brazil.

Os autores declaram não haver conflito de interesses.

Recebido para publicação em 31/01/2017 - Aceito para publicação em 05/05/2017.

INTRODUCTION

Since 2009, femtosecond laser has been used in cataract surgery.⁽¹⁾ Even though it is helpful in routine and challenging cases, it can lead to complications.^(1,2) Recently, two case series reported the first eight eyes that evolved with Descemet membrane detachment (DMD) during femtosecond laser-assisted cataract surgery (FLACS)^(3,4). Herein, we report a patient who developed localized bilateral DMD when the laser was performing the secondary incision in non-simultaneous cataract surgeries. In the operating room, the isolate-and-release technique was used to effectively manage this complication.⁽³⁾

CASE REPORT

A 65-year-old female presented referring difficulty while driving at night in the last 6 months. She had systemic hypertension and an unremarkable previous ocular history. Her best-corrected distance visual acuity (BCVA) was 20/20 in both eyes (OU) with a refraction of +4.25 diopters (D) OU. She was 20/30 OU in the brightness acuity test. Slit lamp examination revealed 1+ nucleosclerosis OU. Her preoperative exams showed an endothelial cell density of 1995 cells/mm³ in the right eye (OD) and 2061 cells/mm³ in the left eye (OS), and a central corneal thickness of 588 μ m in OD and 579 μ m in OS.

She underwent non-simultaneous FLACS using the LenSx laser system (Alcon Laboratories, Inc., Fort Worth, TX) in OU. The surgeries were 65 days apart. We used our usual laser parameters (Table 1). When performing the secondary incision, the laser started firing normally in the anterior chamber and progressed towards the epithelium. DMD occurred right after the laser was applied to the corneal internal surface, and did not progress to the corneal central area. In OD, the detachment extended over two and a half clock hours in the corneal periphery (Figure was previously published as Figure 1A3), while in OS it remained peri-incisional (Figure 1). In spite of causing DMD, the laser continued performing the secondary incision as usual.

In the operating room, the isolate-and-release technique was used to manage this complication.⁽³⁾ Briefly, this technique consists of first opening the incision not affected by the detachment and filling the anterior chamber with ophthalmic viscosurgical device. This increases the intracameral pressure and isolates the detached part of the Descemet membrane (DM), preventing the trapped bubbles from increasing the detachment by moving inadvertently. Then, the incision with the detachment is opened with a spatula. As soon as the internal part of this incision is opened, the increased intracameral pressure causes the trapped bubbles to be released from the eye, and the detachment cannot be seen in the microscope or its limits can only be barely seen.

Table 1

Routine femtosecond laser parameters used to perform corneal incisions

Incision	Energy	Spot separation	Layer separation	Angulation
Main incision (triplanar)	6 uJ	3 μ m	3 μ m	76°/14°/90°
Secondary incision	5 uJ	4 μ m	3 μ m	35°

We used the primary and secondary incisions made by the laser to perform the surgery. The phacoemulsification and IOL implantation occurred uneventfully. An air bubble was placed in the anterior chamber at the end of each surgery. The corneas were clear on the first postoperative day and anterior segment optical coherence tomography (OCT) showed DMD. Within 30 days, a new OCT showed resolution of the detachments. The final BCVA was 20/20, with a refraction of plano -0,50 x 100° in OD and plano - 0,25 x 70° in OS.

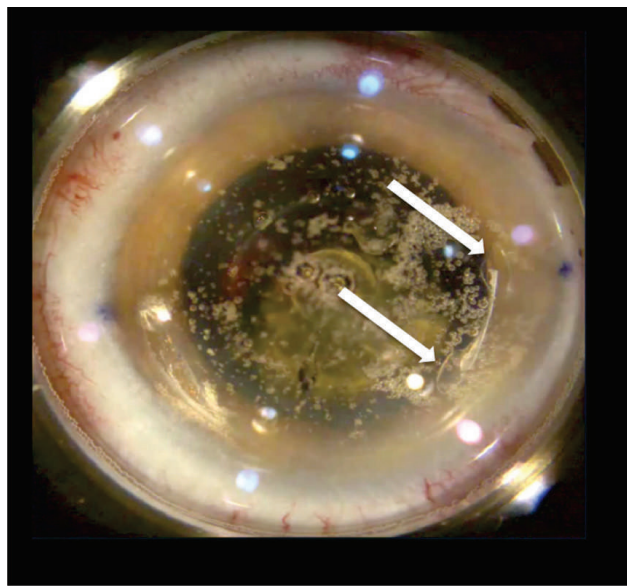


Figure 1. Screenshot of the femtosecond laser display of another patient evidencing two small Descemet membrane detachments caused by the laser when it started making the main incision (white arrows).

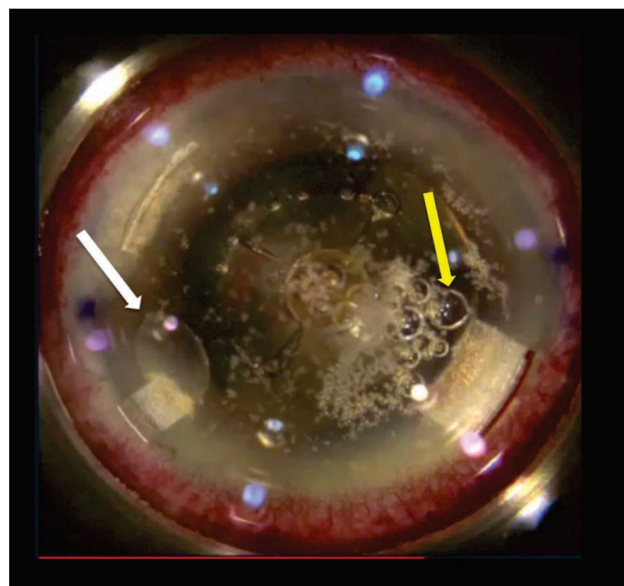


Figure 2. Screenshot of the femtosecond laser display at the end of the laser treatment of the left eye evidencing the localized Descemet membrane detachment adjacent to the secondary incision (white arrow) and the normal bubbles produced by the laser and that are present intracamerally at the end of the laser application (yellow arrow).

DISCUSSION

DMD is a rare complication of phacoemulsification, being described in 0.5% of conventional cataract surgeries.⁽⁵⁾ The first cases in FLACS were recently reported.^(3,4) In one of them, the detachment was only noticed after cataract removal, and the surgery ended with absence of the central part of the DM and a detachment of its remaining peripheral part.⁽⁴⁾ This patient had to undergo DM endothelial keratoplasty to obtain a satisfactory postoperative visual acuity, evidencing the importance of early identification of this possible complication and of having a safe and effective technique to manage it.

Among the factors that increase the risk of DMD in conventional cataract surgery are age older than 65 years; pre-existing endothelial disease; poor wound manipulation; and inadvertent injection of viscoelastic, fluid or gas between the DM and the corneal stroma.^(6,7) Moreover, it has been previously hypothesized that some patients might have an anatomic predisposition to develop a detachment, due to an abnormality in the fibrillary stromal attachment to the DM.⁽⁸⁾

The factors that increase the risk of DMD in FLACS have not been determined. Also, the reason for the bubbles created by the laser to get trapped between the DM and the stroma, despite the incision having been effectively made by the laser, remain unclear. However, we believe that the factors described above for conventional cataract surgery may play a role. Our patient was 65 years old at the time of FLACS. Furthermore, the fact that the detachment occurred in OU suggests that she has an anatomic predisposition to develop this complication. We ruled out excessive laser energy and device miscalibration as possible causes, since we were using our routine laser parameters, the laser presented no abnormality in the calibration tests and several other patients underwent FLACS in this time period and did not have this complication.

Smaller detachments (Figure 1) might be misinterpreted as the normal bubbles produced by the laser and that are present intracamerally at the end of the laser application (Figure 2). It is important to distinguish between these two scenarios before entering the anterior chamber to avoid further ocular damage if there is a true DMD. The bubbles that are trapped between the DM and the stroma, causing a detachment, do not move if the eye is passively moved using a forceps, differing from the bubbles that are free in the anterior chamber.

Our patient's localized DMD did not extend to the central corneal region by using the isolate-and-release technique,⁽³⁾ which consists of simple maneuvers to avoid progression of the DMD and important further ocular damage, as aspiration of the DM.⁽⁴⁾

To the best of our knowledge, this is the first case of bilateral DMD during non-simultaneous FLACS. The exact risk factors for this complication are still unknown and require future studies. However, the early identification of the detachment and dealing with it appropriately is key to decrease the risk of compromising the postoperative visual result and to avoid the need for further surgical procedures.

REFERENCES

1. Nagy ZZ, Takacs AI, Filkorn T, Kránitz K, Gyenes A, Juhász E, et al. Complications of femtosecond laser-assisted cataract surgery. *J Cataract Refract Surg*. 2014;40(1):20-8.
2. Grewal DS, Schultz T, Basti S, Dick HB. Femtosecond laser-assisted cataract surgery-current status and future directions. *Surv Ophthalmol*. 2016;61(2):103-31.
3. Ventura B, Ventura M. Managing descemet detachment in femtosecond laser-assisted cataract surgery: the isolate-and-release technique. *J Refract Surg*. 2016; 32(2):136.
4. Nosé RM, Rivera-Monge MD, Forseto AS, Nosé W. Descemet membrane detachment in femtosecond laser-assisted cataract surgery. *Cornea*. 2016; 35(4):562-4.
5. Khng CY, Voon LW, Yeo KT. Causes and management of Descemet's membrane detachment associated with cataract surgery—not always a benign problem. *Ann Acad Med Singapore*. 2001;30(5):532-5.
6. Ti SE, Chee SP, Tan DT, Yang YN, Shuang SL. Descemet membrane detachment after phacoemulsification surgery: risk factors and success of air bubble tamponade. *Cornea*. 2013;32(4):454-9.
7. Fang JP, Amesu KB, Baratz KH. Preexisting endothelial abnormalities in bilateral postoperative descemet membrane detachment. *Arch Ophthalmol*. 2003;121(6):903-4.
8. Kansal S, Sugar J. Consecutive Descemet membrane detachment after successive phacoemulsification. *Cornea*. 2001;20(6):670-1.

Corresponding Author:

Bruna V. Ventura
 Altino Ventura Foundation
 Rua do Progresso, 71, Boa Vista, Recife (PE), Brazil.
 Zip code 50070-020. Phone 5581-3302-4343.
 Email: brunaventuramd@gmail.com