

Analysis of corneal curvature after pterygium excision: the impact of the surgical procedure objectively in our practice

Análise da curvatura corneana após exérese de pterígio: o impacto do procedimento cirúrgico de forma objetiva em nossa prática

Ignatz Rohrbacher¹, Pedro Felipe Mylla Boso¹, Fernanda Brixius de Almeida¹, Ernani Luiz Garcia²

ABSTRACT

Introduction: Pterygium is a centripetal proliferation of fibrovascular tissue, which proceeds from the bulbar conjunctiva towards the center of the cornea. Excision of the pterygium may cause visual acuity improvement and surgical excision aims to achieve a topographically regular ocular surface. The improvement of the visual acuity results from the alteration of the refractive corneal power, that is measured in the topography as alteration of the topographic astigmatism. The objective of this study was to evaluate the variation of the final topographic astigmatism after the pterygium excision surgery. **Methods:** A prospective study was carried out to follow up patients after pterygium excision surgery with corneal topography before and 1 month after the surgery. The population was of the non-probabilistic type of volunteers, with n of 74 eyes. Sampling was for convenience and participation was offered to patients from the ophthalmology residence outpatient service who underwent pterygium excision between July and December 2015. **Results:** A total of 74 surgeries were performed in the period and 44 were included in the statistical analysis. Mean values of topographic astigmatism (CYL) showed a statistically significant reduction from 2.715D to 1.448D ($p = 0.0037$). The change in the more curved meridian (Ks) showed no significant change from 45.60D to 45.32D ($p = 0.1050$), while the meridian plane at 90° Ks (Kf) showed a significant increase from 42.86D to 43.87D ($p = 0.0052$). Isolated analysis of the groups showed that only the group with grade 3 pterygia suffered a significant alteration of CYL from 7,12D to 1,82D ($p = 0,0002$). **Conclusion:** The surgery resulted in a significant reduction of topographic astigmatism only in patients with grade 3 pterygium, due to the reduction of the flattening caused by the pterygium.

Keywords: Pterygium; Cornea; Conjunctiva; Ophthalmologic surgical procedures; Corneal topography

RESUMO

Introdução: O pterígio é uma proliferação de tecido fibrovascular centrípeta, que avança da conjuntiva bulbar em direção ao centro da córnea. A excisão do pterígio pode causar melhora na acuidade visual. A excisão cirúrgica tem como objetivo atingir uma superfície ocular topograficamente regular. A melhora da acuidade visual decorre da alteração do poder refrativo corneano, que é aferido na topografia como alteração do astigmatismo topográfico. O objetivo do estudo foi avaliar a variação do astigmatismo topográfico final após a cirurgia de exérese de pterígio. **Métodos:** Foi realizado um estudo prospectivo de acompanhamento de pacientes após cirurgia de exérese de pterígio com a realização de topografias corneanas antes e 1 mês após a cirurgia. A população foi do tipo não-probabilística de voluntários, com n de 74 olhos. A amostra-gem foi por conveniência, sendo oferecida a participação aos pacientes do ambulatório geral de oftalmologia que foram submetidos ao procedimento de exérese de pterígio entre julho e dezembro de 2015. **Resultados:** Foram realizadas 74 cirurgias no período e 44 foram incluídas na análise estatística. Os valores médios do astigmatismo topográfico (CYL) mostraram redução estatisticamente significativa de 2,715D para 1,448D ($p = 0,0037$). A alteração do meridiano mais curvo (Ks) não mostrou alteração significativa com variação de 45,60 D para 45,32 D ($p = 0,1050$), enquanto o meridiano plano à 90° Ks (Kf) mostrou aumento significativo de 42,86 D para 43,87 D ($p = 0,0052$). A análise isolada dos grupos mostrou que apenas o grupo com pterígios grau 3 sofreu alteração significativa do CYL de 7,12 D para 1,82 D ($p = 0,0002$). **Conclusão:** A cirurgia resultou em uma redução significativa do astigmatismo topográfico apenas em pacientes com pterígio grau 3, isso em decorrência da redução do aplanamento provocado pelo pterígio.

Descritores: Pterígio; Córnea; Túnica conjuntiva; Procedimentos cirúrgicos oftalmológicos; Topografia da córnea

¹ Ophthalmology Service, Hospital Governador Celso Ramos, Florianópolis, SC, Brazil.

² Cornea Department of the Ophthalmology Service, Hospital Governador Celso Ramos, Florianópolis, SC, Brazil.

Study carried out at Hospital Governador Celso Ramos de Florianópolis, SC, Brazil.

The authors declare no conflict of interests.

Received for publication 11/04/2017 - Accepted for publication 13/01/2018.

INTRODUCTION

Pterygium is the name given to a fibrovascular proliferation of tissue that usually occurs in the nasal portion of the corneal-scleral limbus. The etiopathogenesis of the pterygium is not fully understood, and mild theories point to its origin from altered lumbar cells leaving the limbus and migrating centripetally over the basal membrane of the cornea structurally affecting the Bowman's layer.⁽¹⁾ Surgical treatment is indicated when there is persistent discomfort, visual distortions, induction of irregular astigmatism, significant and progressive growth (>3 - 4mm) in front of the corneal visual axis, restriction of ocular motility, and aesthetic alteration.^(2,3) The most commonly used techniques are the excision of the pterygium with conjunctival flap or autologous conjunctival transplant, but techniques using the amniotic membrane coating or mitomycin C may be employed.⁽³⁻⁵⁾ The objective of the microsurgical excision is to achieve a normal and topographically smooth ocular surface.⁽²⁾ Excision of the pterygium can improve visual acuity by altering the refractive corneal power, which can be measured in the topography as a change in topographic astigmatism.^(5,6) The objective was to evaluate the variation of the final topographic astigmatism after pterygium excision surgery.

METHODS

This was a prospective follow-up study of patients after pterygium excision surgery. The study was carried out in four stages, a pre-surgical appointment, the surgical procedure, and re-evaluation 7 and 30 days after the procedure. Surgeries and appointment were performed at the Ophthalmology Service of Hospital Governador Celso Ramos in Florianópolis, Santa Catarina, by resident physicians of the first year of ophthalmology, under the supervision of a professor ophthalmologist. Pterygium was classified according to the Brazilian Ophthalmology Series of the Brazilian Council of Ophthalmology as grade I (<2mm of development on the cornea), grade II (2 to 4mm), and grade III (> 4mm). The device used to perform the corneal topography of the central 3mm was TMN-4N (Tomey®).

The surgical procedure followed the technique of asepsis and antisepsis, local anesthesia with tetracaine hydrochloride eyedrops, palpebral retractor positioning, subconjunctival injection of lidocaine hydrochloride 2%, excision of the pterygium from the center of the cornea using a scalpel blade number 15, excision of part of the Tenon's capsule followed by closure of the exposed area with superior conjunctival flap, episcleral and conjunctival sutures with silk thread 8.0. At the end of the procedure, eyedrops of dexamethasone 1.0 mg, neomycin sulfate 5.0 mg and polymyxin B sulfate 6000 IU, and occlusive dressing

were applied. The medications prescribed were the combination of dexamethasone 1.0 mg, neomycin sulfate 5.0 mg, polymyxin B sulfate 6,000 IU eyedrops every 3 hours for 7 days, and afterwards regressive use of nimesulide 100mg every 12 hours and cold compresses at the site for pain management. Everybody was guided to return to the hospital in case of severe pain, worsening of visual acuity or other symptoms. The stitches were removed at the first re-evaluation 7 days later, and a new corneal topography was performed with re-evaluation 30 days later.

The population studied was a non-probabilistic type of volunteers with n of 74 eyes in 79 participants. The sampling was by convenience, with participation being offered to patients of the ophthalmology ambulatory. The study was carried out between July and December 2015. Primary pterygium patients were evaluated in the ophthalmology ambulatory. Patients who did not follow the follow-up or whose medical records were incomplete were excluded from the analysis. The corneal topographic variables analyzed were Ks (Value in diopters of the most curved meridian), Kf (Value in diopters of the meridian at 90° of Ks), and CYL (Topographic astigmatism measured in diopters by the difference between Ks and Kf). The analysis of the results was made with the t-paired test.

The present study was approved by the institution's CEP (Research Ethics Committee). In compliance with the provisions of the Declaration of Helsinki and resolution 466/12 of the National Health Council, participants were previously informed about the research, the risks and benefits of the procedure. A free and informed consent form was handled in two copies.

RESULTS

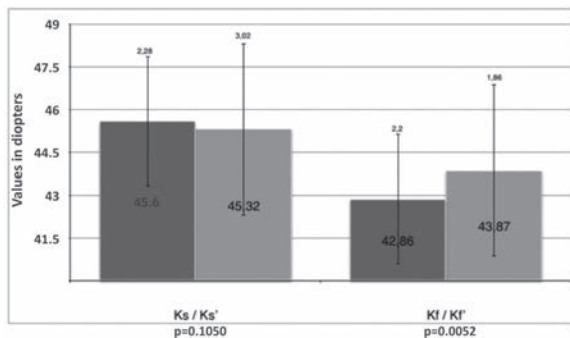
There were 74 surgeries of pterygium excision between July and December 2015. All cases were of pterygium with nasal location. Of these, 27 were excluded in the statistical analysis due to not returning for re-evaluation 30 days after surgery, and 3 due to filling the medical record wrongly, leaving 44 eyes in 41 patients for the evaluation of the results. Among the patients analyzed, 21 were males, 2 of whom underwent surgery in both eyes at different dates, and 20 females, 1 of whom undergoing surgery on both eyes at different dates. The average age was 51 ± 12 years. Table 1 shows in the number of pterygium by grade the average values of Ks, Kf and CYL before and 1 month after of surgery, as well as the result of the statistical analysis comparing the variation of the values.

Figure 1 shows the average values \pm standard deviation of Ks and Kf of all patients analyzed, as well as the result of the statistical analysis comparing the variation of the values. Figure 2 shows the average values \pm standard deviation of the topographic cylinder of all patients analyzed, as well as the result of the statistical analysis comparing the variation of the values.

Table 1
Comparison of the average values of Ks, Kf and CYL before surgery and 1 month after surgery, discriminated by the degree of pterygium

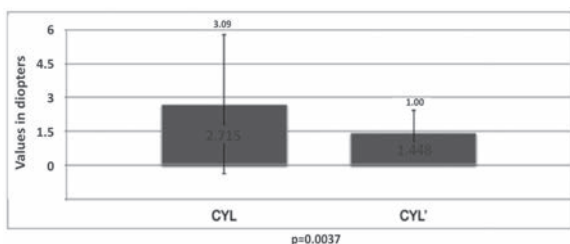
	n	Ks	Ks ¹		Ks	Ks ¹		CYL	CYL ¹	
Grau 1	21	45.83	45.91	p=0.7342	44.66	44.60	p=0.3403	1.18	1.30	p=0.5315
Grau 2	13	44.90	44.34	p=0.1588	43.02	43.04	p=0.9449	1.80	1.39	p=0.2818
Grau 3	10	46.01	45.22	p=0.0816	38.89	43.40	p=0.0001	1.80	7.12	p=0.0002

Ks/Ks¹ - Value in diopters of the most curved meridian before and 1 month after surgery; Kf/Kf¹ - Value in diopters of the flattest meridian before and 1 month after surgery; CYL/CYL¹ - Value in diopters of the topographic astigmatism before and 1 month after surgery



Ks/Ks' - Value in diopters of the most curved meridian before and 1 month after surgery; Kf/Kf' - Value in diopters of the flattest meridian before and 1 month after surgery;

Figure 1: Comparison of the average values of Ks and Kf before surgery and 1 month after surgery



CYL/CYL' - Value in diopters of topographic astigmatism before and 1 month after surgery

Figure 2: Comparison of the average values + standard deviation of topographic astigmatism before surgery and 1 month after surgery

DISCUSSION

Pterygium excision surgery significantly reduces corneal irregularity, making the cornea more topographically curved at the site of surgery.⁽⁵⁾ The present study showed a reduction in the topographic astigmatism, corroborating other authors who did similar analyzes.^(7,8) Bahar et al. demonstrated a decrease in astigmatism in the central 3mm of the cornea from 3.12D in the pre-operative period to 2.51D after surgery, and improvement in the visual acuity with correction.⁽⁶⁾ Khan et al. also reported a reduction in the average topographic astigmatism from 2.25D to 1.30D.⁽⁹⁾ Oh and Wee observed a reduction of corneal astigmatism from 3.08D to 1.22D, in addition to increased sensitivity to contrast after surgery for pterygium removal.⁽⁷⁾ Considering the topographic measurement of the central 3mm of the anterior corneal surface, the reduction in topographic astigmatism was statistically significant, reducing the average CYL from 2.715D to 1.448D. The subgroup analysis showed that this result was due to the reduction of the topographic astigmatism of the corneas with grade 3 pterygium, showing an average reduction of CYL from 7.12D to 1.82D. Our result agrees with a study by Tomidokoro et al. demonstrating that larger pterygium exert greater influence on the corneal surface.⁽¹⁰⁾ Increased Kf in these patients was responsible for the change of the cylinder, reducing the difference between

the corneal meridians. Most of the surgical procedures are performed in pterygium with a corneal extension smaller than 2mm (Grade 1), which did not result in significant topographic changes. We suggest future studies to evaluate the visual changes and refraction in patients with grade 3 pterygium. Our result agrees with other studies published demonstrating that pterygium excision surgery satisfactorily reduces corneal astigmatism.^(7,11)

CONCLUSION

Pterygium excision surgery resulted in a significant reduction of topographic astigmatism only in patients with grade 3 pterygium due to the reduction of the flattening caused by the pterygium.

REFERENCES

1. Dushku N, Reid TW. Immunohistochemical evidence that human pterygia originate from an in-vasion of vimentin-expressing altered limbal epithelial basal cells. *Curr Eye Res.* 1994;13(7):473-81.
2. Aminlari A, Singh R, Liang D. Management of pterygium. *EyeNet* [Internet]. [cited 2017 Dec 12] Available from: [https://www.aaopt.org/eyenet/article/management-of-ptyerygium-2].
3. Alvez MR, Angotti HS. Pterigio. *Série Oftalmologia Brasileira: Doenças Externas oculares e córnea 4a. ed.* Rio de Janeiro: Cultura Médica; 2016. p.455-9.
4. Kheirkhah A1, Nazari R, Nikdel M, Ghassemi H, Hashemi H, Behrouz MJ. Postoperative conjunctival inflammation after pterygium surgery with amniotic membrane transplantation versus conjunctival autograft. *Am J Ophthalmol.* 2011;152(5):733-8.
5. Kurna SA, Altun A, Aksu B, Kurna R, Sengor T. Comparing treatment options of pterygium: limbal sliding flap transplantation, primary closing, and amniotic membrane grafting. *Eur J Ophthalmol.* 2013;23(4):480-7.
6. Bahar I, Loya N, Weinberger D, Avisar R. Effect of pterygium surgery on corneal topography: a prospective study. *Cornea.* 2004;23(2):113-7.
7. Oh JY, Wee WR. The effect of pterygium surgery on contrast sensitivity and corneal topographic changes. *Clin Ophthalmol.* 2010;4:315-9.
8. Stern GA, Lin A. Effect of pterygium excision on induced corneal topographic abnormalities. *Cornea.* 1998;17(1):23-7.
9. Khan FA, Niazi SPK, Khan DA. the impact of pterygium excision on corneal astigmatism. *J Coll Physicians Surg Pak.* 2014; 24(6):404-7.
10. Tomidokoro A, Miyata K, Sakaguchi Y, Samejima T, Tokunaga T, Oshika T. Effects of pterygium on corneal spherical power and astigmatism. *Ophthalmology.* 2000;107(8):1568-71.
11. Lin A, Stern G. Correlation between pterygium size and induced corneal astigmatism. *Cornea.* 1998;17(1):18-30.

Corresponding author:

Ignatz Rohrbacher; R. Irmã Benwarda, 297 - Centro, Florianópolis, SC, Brazil. ZIP Code: 88025-30. E-mail ignatz.rohrbacher@gmail.com