

# Kjer's disease associated with hypoacusis and late clinical manifestation

## *Neuropatia óptica dominante associada a hipoacusia e apresentação tardia*

Eduardo Scaldini Buscacio<sup>1</sup>, Juliana Glicéria Monteiro da Silva<sup>1</sup>, Yoshifumi Yamane<sup>2</sup>

### ABSTRACT

*The optic neuropathy of Kjer, or dominant optic atrophy, is the most common among optic neuropathies. It is an optical atrophy of dominant autosomal character that is caused by an alteration in the gene on chromosome 3q28 with OPA1 penetration of 98%. Only 15% of cases have visual acuity of 0.1 or worse, while demonstrating different grades of atrophy of the disc. This report aims to describe the genetic and clinical characteristics, and methods of family counseling through the presentation of a case of dominant optic atrophy with severe loss of visual acuity, together with the onset of unusually late and bilateral hearing loss.*

**Keywords:** Optic atrophy, autosomal dominant/genetics; Deafness; Color vision defects; Genetic counseling; Case reports

### RESUMO

A neuropatia óptica de Kjer, ou atrofia óptica dominante, é a mais frequente das neuropatias ópticas familiares. Trata-se de uma atrofia óptica de caráter autossômico dominante que se dá por uma alteração no gene OPA1, no cromossomo 3q28, com penetrância de 98%. Apenas 15% dos casos possuem acuidade visual de 0,1 ou pior, apresentando ainda diferentes graus de atrofia do disco. Este relato objetiva descrever as características genéticas e clínicas da doença, bem como apresentar medidas de aconselhamento familiar. Para isso, será relatado um caso clínico de atrofia óptica dominante no qual se constata perda acentuada da acuidade visual, início de manifestações atipicamente tardias e hipoacusia bilateral.

**Descritores:** Atrofia óptica autossômica dominante/genética; Surdez; Defeitos da visão cromática; Aconselhamento genético; Relatos de caso

<sup>1</sup>Resident, Piedade Municipal Hospital, Rio de Janeiro/RJ, Brazil.

<sup>2</sup>Ph.D., Professor at Gama Filho University (UGF), Rio de Janeiro/RJ, Brazil.

**The authors declare no conflicts of interest**

Received for publication: 5/2/2013 - Accepted for publication: 20/6/2013

## INTRODUCTION

**K**jer's dominant optic atrophy, first described by Kjer in a study on Danish families in 1959<sup>(1)</sup>, is the most common hereditary optic atrophy, with an estimated prevalence between 1:10,000 and 1:50,000<sup>(2,3)</sup>.

It is characterised by hereditary optic neuropathy, usually bilateral<sup>(3)</sup>, associated with dyschromatopsia, changes in the visual field, variable loss of visual acuity<sup>(4)</sup>, and optic disc pallor. The condition generally begins in childhood<sup>(4)</sup>, and has autosomal dominant inheritance linked to the OPA1 gene<sup>(3,5)</sup>, with high penetrance and variable expressivity<sup>(4,6,7)</sup>.

This paper aims to describe the genetic and clinical characteristics of the disease and to present family counselling measures. This will be done through a case report of dominant optic atrophy with marked loss of visual acuity, unusually delayed onset of clinical manifestations, and bilateral hearing loss.

## CASE REPORT

BB, a 43-year-old mixed-race male patient from Rio de Janeiro, was seen at the outpatient clinic of the Piedade Municipal Hospital complaining of progressive loss of visual acuity starting approximately 16 years earlier. He had a history of cataract and had undergone phakectomy in both eyes. Family history revealed parents and siblings with hearing loss and low vision not previously investigated.

Ophthalmic examination showed a corrected visual acuity of 0.1 in both eyes (BE). Biomicroscopy confirmed that the patient was pseudophakic in both eyes, without other significant changes. Goldmann applanation tonometry found an intraocular pressure of 12 mmHg in BE. Biomicroscopy of the fundus showed a predominantly temporal atrophy of both optic discs and the retinal pigment epithelium (Figure 1).

The Ishihara test was used to assess colour perception. The test was conducted at distances of 40 cm and 100 cm under uniform lighting conditions and found generalised, nonspecific dyschromatopsia. Manual Goldman perimetry showed a peripheral contraction in BE and a scotoma containing the blind spot in the left eye (LE) (Figure 2). An MRI showed no changes. Audiometry revealed severe bilateral sensorineural hearing loss.

The patient's family members were assessed and included in the genogram shown in Figure 3. Members with some degree of optic disc atrophy were considered to be affected by the condition. Varying degrees of visual acuity impairment were found, ranging between 0.05 and 1.0.

We opted not submit the patient to any specific treatment. The family was referred for genetic counselling and regular outpatient follow-up.

## DISCUSSION

Four loci associated with optic atrophy have been mapped: OPA1 (autosomal dominant, 3q28 to 29); OPA2 (X-linked, Xp11.4 to 11.21); OPA3 (autosomal recessive, 19q13.2 to 13.3); and OPA4 (autosomal dominant, 18q12.2 to 12.3)<sup>(8)</sup>. The OPA1 gene was identified in these four loci. Mutations in this gene are responsible for 90% of cases of dominant optic atrophy, with varying degrees of severity. The mutation occurs mostly in chromosome 3q28-

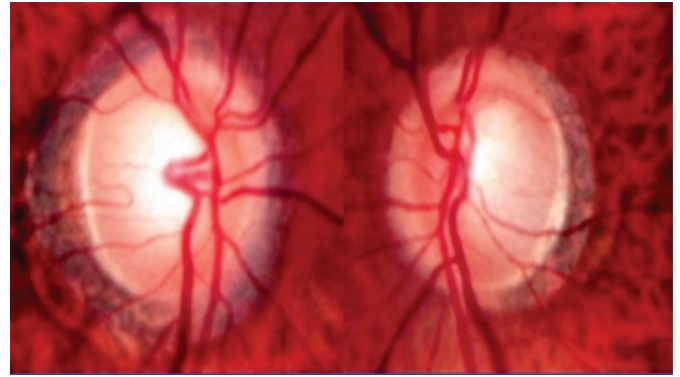


Figure 1 Temporal optic disc atrophy bilaterally.

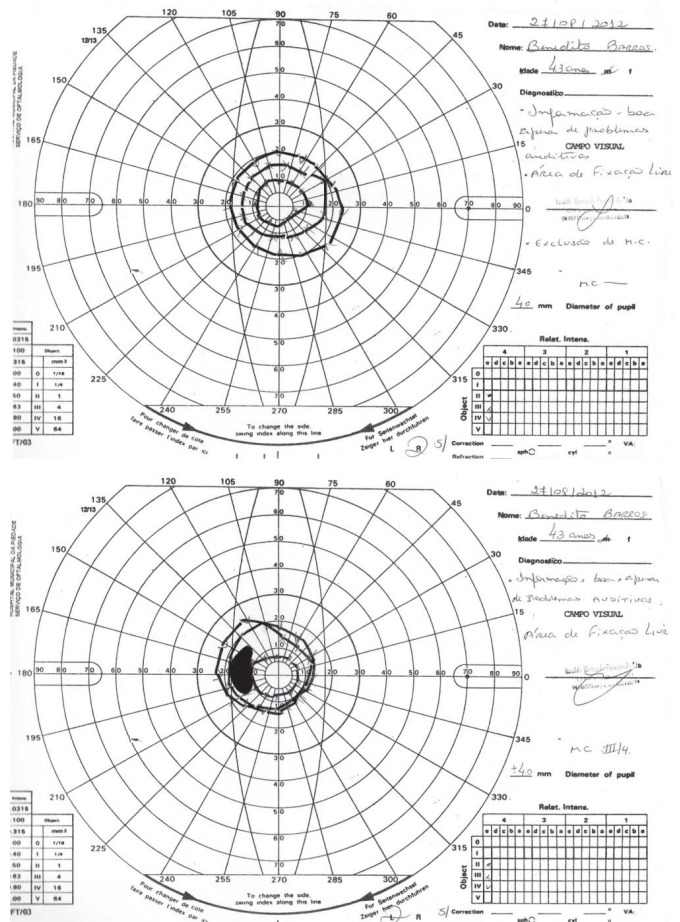


Figure 2. Goldmann perimetry.

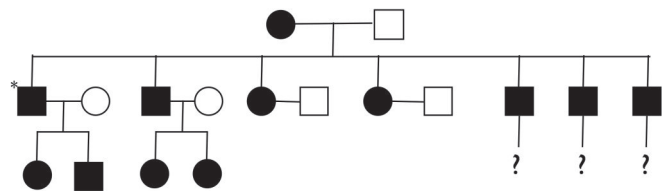


Figure 3: Genogram.

q29, with a mean penetration of 98%. However, there is evidence of genetic heterogeneity<sup>(9,10)</sup>.

In 1972 Smith reviewed the clinical characteristics of dominant optic atrophy and listed its diagnostic criteria<sup>(11)</sup>. In a family affected by dominant optic atrophy, the minimum diagnostic criteria are total or temporal optic disc pallor and any defect in colour vision. The disease usually manifests in children and young adults<sup>(3,5)</sup>, and half of affected individuals manifest the disease before the age of 10 years<sup>(6)</sup>.

Visual acuity can be reduced or normal. When reduced, both eyes tend to be affected symmetrically. Only 15% of patients have a visual acuity of 0.1 or worse, and there is great variability in visual acuity within and between families<sup>(4,12)</sup>. The patient presented here had severe impairment of visual acuity of delayed onset, making this case even more peculiar.

The degree of optic disc atrophy also varies within and between families<sup>(13)</sup>. The atrophy can be mild, affecting the temporal side with triangular cupping, or diffuse, involving the entire optic nerve<sup>(7,13)</sup>.

The disease mainly affects the ganglion cell layer of the retina, producing ascending optic atrophy. It causes diffuse atrophy of the ganglion cell layer while preserving the inner and outer nuclear layers, with non-inflammatory demyelination of the optic nerve and loss of nervous tissue in the temporal side of the disc<sup>(14)</sup>. Electrophysiological and histopathological studies also suggest a defect in the ganglion cell layer. It can thus be inferred that the gene responsible for optic atrophy is expressed in ganglion cells<sup>(3)</sup>.

Impairment of colour vision usually includes changes in the blue-yellow axis or tritanopia<sup>(3,12)</sup>, but it can also present as nonspecific generalised impairment<sup>(12,15)</sup>, as was the case in our patient.

The most common changes in perimetry include central and cecocentral scotomata<sup>(12)</sup>, but our patient had a bilateral contraction and a scotoma containing the blind spot in the LE.

The disease is infrequently associated with neurological changes, but there are reports of association with mental retardation and sensorineural deafness<sup>(4)</sup>, as was the case in our patient.

There is currently no available treatment to prevent visual loss, delay disease progression, or restore vision<sup>(6)</sup>.

The differential diagnosis of the condition includes other diseases that cause optic atrophy, including Leber hereditary optic neuropathy, Leigh syndrome, Costeff optic atrophy syndrome, normal tension glaucoma, and nutritional deficiencies<sup>(16,17)</sup>.

## CONCLUSION

Even though Kjer's optic atrophy is the most common hereditary optic atrophy, it is still a relatively rare disease. The case presented here was particularly interesting because of its atypical manifestations. Even general ophthalmologists should be familiar with the disease, otherwise it might not be recognised as a familial disorder, leading to unnecessary diagnostic costs and failure to provide genetic counselling for family members.

## REFERENCES

1. Kjer P. Infantile optic atrophy with dominant mode of inheritance: a clinical and genetic study of 19 Danish families. *Acta Ophthalmol Suppl.* 1959;164(Suppl 54):1-147.

2. Lyle WM. Genetic risks. Waterloo, Ontario: University of Waterloo Press; 1990.
3. Kjer B, Eidberg H, Kjer P, Rosenberg T. Dominant optic atrophy mapped to chromosome 3q region. II. Clinical and epidemiological aspects. *Acta Ophthalmol Scand.* 1996;74(1):3-7
4. Hoyt CS. Autosomal dominant optic atrophy. A spectrum of disability. *Ophthalmology.* 1980;87(3):245-51.
5. Omim® - Online Mendelian Inheritance in Man®. Baltimore, MD., National Center for Biotechnology Information; [cited 1999 Set 9].
6. Johnston RL, Seller MJ, Behnam JT, Burdon MA, Spalton DJ. Dominant optic atrophy. Refining the clinical diagnostic criteria in light of genetic linkage studies. *Ophthalmology.* 1999; 106(1): 123-8.
7. Votruba M, Fitzke FW, Holder GE, Carter A, Bhattacharya SS, Moore AT. Clinical features in affected individuals from 21 pedigrees with dominant optic atrophy. *Arch Ophthalmol.* 1998; 116(3):351-8. Comment in *Arch Ophthalmol.* 1999; 117(2): 287-8.
8. Delettre C, Griffioen JM, Kaplan J, Dollfus H, Lorenz B, Faivre L, et al. Mutation spectrum and splicing variants in the OPA1 gene. *Hum Genet.* 2001;109(6):584-91.
9. Seller MJ, Behnam JT, Lewis CM, Johnston RL, Burdon MA, Skalton DJ. Linkage studies in dominant optic atrophy, Kjer type: possible evidence for heterogeneity. *J Med Genet.* 1997;34(12):967-72.
10. Kerrison JB, Arnould VJ, Ferraz Sallum JM, Vagefi MR, Barmada MM, Li Y, et al. Genetic heterogeneity of dominant optic atrophy, Kjer type: identification of a second locus on chromosome 18q12.2- 12.3. *Arch Ophthalmol.* 1999;117(6):805-10.
11. Smith DP. Diagnostic criteria in cominantly inherited juvenile optic atrophy. A report of three new families. *Am J Optom Arch Am Acad Optom.* 1972;49(3):183-200.
12. Kline LB, Glaser JS. Dominant optic atrophy. The clinical profile. *Arch Ophthalmol.* 1979;97(9):1680-6.
13. Newman NJ, Bioussé V. Hereditary optic neuropathies. *Eye (Lond).* 2004;18(11):1144-60. Review.
14. Kjer P, Jensen OA, Klinken L. Histopathology of eye, optic nerve and brain in a case of dominant optic atrophy. *Acta Ophthalmol (Copenh).* 1983;61(2):300-12.
15. Newman NJ. Hereditary optic neuropathies. In: Miller NR, Newman NJ, Bioussé V, Kerrison JB, editors. *Walsh & Hoyt clinical neuro-ophthalmology.* 6th ed. Baltimore: Lippincott Williams & Wilkins; 2005. v. 1. p. 465-501.
16. Amigo MH, Bárbara EC, Ghirelli W. Autoimmune optic neuropathy as the first manifestation of systemic lupus erythematosus. *Rev Bras Oftalmol.* 2012;71(2):106-10.
17. Amigo MH, Ghirelli W. Neuropatia óptica isquêmica posterior como complicação pós-cirurgia de blefaroplastia. *Rev Bras Oftalmol.* 2011;70(6):422-5.

## Corresponding author:

Eduardo Scaldini Buscacio  
Rua Senador Vergueiro 93/503 - Flamengo - CEP 22230-000  
Rio de Janeiro/RJ, Brazil