



RBO
REVISTA BRASILEIRA DE ORTOPEDIA

www.rbo.org.br/



Original Article

Patellofemoral instability: evaluation by magnetic resonance imaging

Patrícia Martins e Souza,^{1,*} Marcelo Sadock de Sá Gabetto,² Marcelo Ganem Serrão,³
Luiz Antônio Martins Vieira,⁴ Diogo Cals de Oliveira⁵

¹MD, MSc and PhD in Radiology from Instituto D'Or de Ensino e Pesquisa, and Radiologist in Grupo Fleury and Instituto Nacional de Traumatologia e Ortopedia, Rio de Janeiro, RJ, Brazil.

²Radiologist at Instituto D'Or de Ensino e Pesquisa, and Radiologist at Grupo Fleury, Rio de Janeiro, RJ, Brazil.

³Orthopedist with specialization in Sports Medicine and Knee Surgery from Hospital São Zacarias/Santa Casa de Misericórdia do Rio de Janeiro, Rio de Janeiro, RJ, Brazil.

⁴Orthopedist with specialization in Knee Surgery, Instituto Nacional de Traumatologia e Ortopedia, Rio de Janeiro, RJ, Brazil.

⁵Orthopedist with specialization in Knee Surgery, Instituto Nacional de Traumatologia e Ortopedia, Rio de Janeiro, RJ, Brazil.

Work performed at Instituto D'Or de Ensino e Pesquisa, Rio de Janeiro, RJ, Brazil.

ARTICLE INFO

Article history:

Received on February 1, 2012

Approved on April 12, 2012

Keywords:

Joint Instability

Patellar Dislocation

Magnetic Resonance Imaging

A B S T R A C T

Objective: To determine the contribution of magnetic resonance imaging (MRI) in evaluating patellofemoral instability. **Methods:** 39 patients (45 knees) with patellar instability underwent knee magnetic resonance images between October 2009 and July 2011, at the Rede Lab's D'Or, in the city of Rio de Janeiro, State of Rio de Janeiro, were included. MRI were analyzed for the presence of bone, hyaline cartilage and soft-tissue abnormalities, as well as anatomic variants that may contribute to chronic patellar instability. **Results:** The authors found, of the 45 knees analysed, bone changes in 44%, cartilaginous injuries in 64%, disruption of the medial patellofemoral ligament (MPFL) in 29% and joint morphology abnormalities in 73% patients. Meniscal tears were also identified in 2 (4%) patients and fibular fracture in one (2%) patient. **Conclusion:** MRI allowed the detection of predisposing factors that may contribute to the development of patellofemoral instability and the diagnosis of bone, hyaline cartilage, ligamentous and meniscal abnormalities.

© 2013 Sociedade Brasileira de Ortopedia e Traumatologia. Published by Elsevier Editora Ltda. All rights reserved.

*Corresponding author at: Rua Barão de São Francisco 287/403, Rio de Janeiro, RJ, Brasil, CEP: 20.560-031.

E-mail: pat_martins@ig.com.br

Introduction

Patellofemoral instability is still a challenge for orthopedists, not only because of the diversity and complexity of the causal factors but also because of the large number of therapeutic possibilities. Many authors have taken the view that, in the majority of cases, there is a predisposing anatomical factor that contributes towards the instability and that it is fundamental to recognize this in order to define the best approach. Moreover, displacement of the patella promotes occurrences of other lesions and greater risk of development of osteoarthritis, which also affects the choice of treatment and the prognosis.¹

For many decades, simple radiographs (X-rays) and computed tomography (CT) were the only imaging methods used for evaluating these patients. However, over recent years, magnetic resonance imaging (MRI) has emerged as an auxiliary method for investigating patellofemoral instability, particularly for detecting osteochondral lesions and for evaluating the medial patellofemoral ligament (MPFL). Furthermore, many authors have perceived that MRI also makes it possible to detect predisposing factors and to make a variety of measurements with the same accuracy as CT scans, thus making this the preferred imaging method for evaluating patellofemoral instability in several centers.²

The aim of this study was to determine the contribution of MRI in evaluations on patients with a clinical condition of patellofemoral instability.

Material and methods

This study was approved by the ethics committee of our institution (Instituto D'Or de Ensino e Pesquisa). MRI scans on 45 consecutive knee cases were retrospectively analyzed. The patients were referred by orthopedists who are specialists in knee surgery, with a clinical condition of patellofemoral instability and a history of recurrent lateral dislocation of the patella. The MRI scans were produced between October 2009 and July 2011, in apparatus of 1.5 tesla, using specific coils for the knee joint. All the examinations included T2-weighted sequences with fat suppression in the axial plane, proton density (PD) weighted sequences with fat suppression in the coronal and sagittal planes, and T2-weighted sequences in the sagittal plane. Twenty-three examinations included additional sequences with T1 weighting in the axial and sagittal planes at flexion of around 20° to 30°.

Areas of bone edema typical of previous lateral dislocation of the patella were sought (Fig. 1). These were characterized by increased signal in the T2 and PD weightings with fat suppression, in the bone marrow of the medial portion of the patella and on the external face of the lateral femoral condyle,²⁻⁵ other areas of bone edema unrelated to patellar dislocation, joint effusion and tendinous, ligamentous, meniscal or cartilaginous lesions. The presence of morphological or joint geometrical abnormalities that would predispose towards patellofemoral instability was also evaluated,^{2,6} using the following criteria:

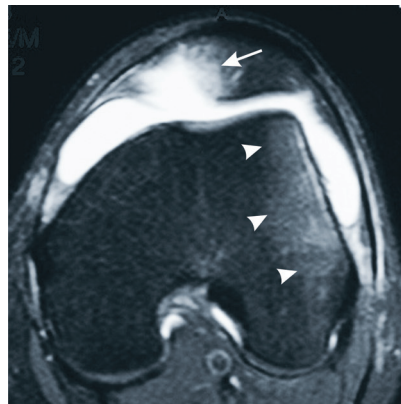


Fig. 1 - T2-weighted MRI with fat suppression in the axial plane, in which bone edema is observed in the medial portion of the patella (arrow) and on the periphery of the lateral femoral condyle, which is typical of a recent episode of transitory lateral dislocation of the patella. Also note the presence of joint effusion.

a) High patella: Caton-Deschamps index greater than 1.2 (Fig. 2).

b) Morphological abnormalities in the intercondylar fossa of the femur (trochlea dysplasia), based on the Dejours radiographic classification (Fig. 3):

Type A – trochlea with morphology preserved, but with a shallow trochlear sulcus (angle greater than 145°).

Type B – rectified trochlea.

Type C – asymmetrical trochlear facets, with hypoplasia of the medial facet and convexity of the lateral facet.

Type D – asymmetry of the trochlear facets, with presence of a supra-trochlear ventral prominence greater than or equal to 7 mm.

c) Lateral inclination of the patella: normally, the lateral facet of the patella forms an angle with the posterior bicondylar line that is open laterally and greater than 8° in flexion (lateral inclination angle). Patellae with a lateral inclination angle that opened laterally but was less than or equal to 8° on axial images obtained in flexion were considered to be inclined. If the only images available were axial, in extension, the patellae were considered to be inclined if their inclination angle opened medially or if the lateral facet of the patella was parallel to the posterior bicondylar line (Fig. 4).

d) Lateral displacement of the patella: this was only evaluated in the 23 cases in which images acquired in flexion in the axial plane were available, since lateralization of the patella in extension may be physiological. Patellae that did not fit into the trochlea in flexion and with the medial margin lateralized in relation to a line perpendicular to the bicondylar line, in the plane

of the medial eminence of the femoral trochlea, were considered to be displaced (Fig. 5).

e) Increased TA-GT distance: this measurement was evaluated only in the cases in which the image acquisition in the axial plane included the insertion of the patellar ligament into the tuberosity of the tibia. The technique used was based on the criteria of Bernageau and Goutallier, but done with the knee extended and adaptation to the magnetic resonance images, as described in the literature:⁷⁻⁹ firstly, a line was traced out tangentially to the posterior femoral condyles (posterior bicondylar line). Then, two lines were traced out perpendicular to the posterior bicondylar line: one going through the center of the base of the trochlea (line GT), in the plane in which the intercondylar region has the shape of a Roman arch; and the other going through the center of the patellar ligament (line TA), in the plane of its uppermost insertion into the tuberosity of the tibia, in the first slice in which no fat was identified between the patellar ligament and the cortical bone of the tibia. The distance between the lines TA and GT (TA-GT distance) was measured in millimeters, and this was considered to be within normal limits when it was less than or equal to 15 mm⁹ (Fig. 6).

The images were analyzed by two radiologists with more than five years of experience of musculoskeletal radiology, and reports describing the abnormalities encountered were issued. The main findings and their prevalences are detailed in Table 1.

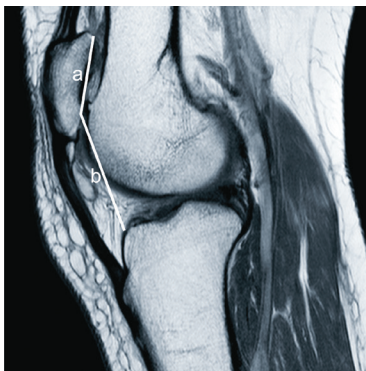


Fig. 2 - High patella, according to the Caton-Deschamps index, shown on T1-weighted MRI in the sagittal plane, in which the ratio between the line traced out from the lower pole of the patella to the anterior margin of the tibial plateau (line b) and the line from the joint margin of the patella (line a) is greater than 1.2.

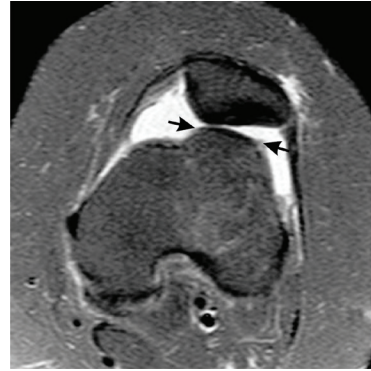

Fig. 3 - T2-weighted MRI with fat suppression in the axial plane, showing dysplastic trochlea characterized by a convex lateral facet (arrows).

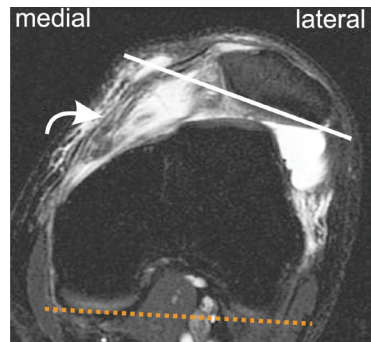


Fig. 4 - T2-weighted MRI with fat suppression in the axial plane, showing an inclined patella characterized by the angle formed by projection of the posterior bicondylar line (dashed line) and the lateral facet of the patella (straight line) with medial opening. Note that the patella is lateralized and the trochlea is also dysplastic, similar to the case in Fig. 3. There is also joint effusion and a lesion on the medial patellofemoral ligament (curved arrow).

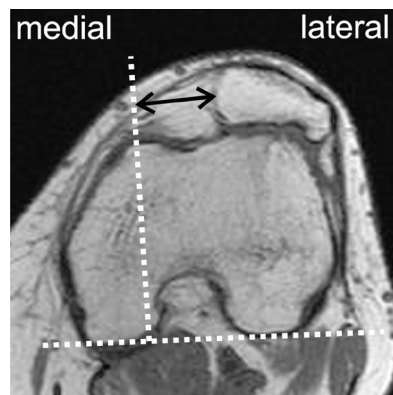


Fig. 5 - T1-weighted MRI in the axial plane, acquired in flexion, showing patella not fitting into the trochlea and with the medial margin lateralized in relation to a line perpendicular to the bicondylar line, in the plane of medial eminence of the femoral trochlea.

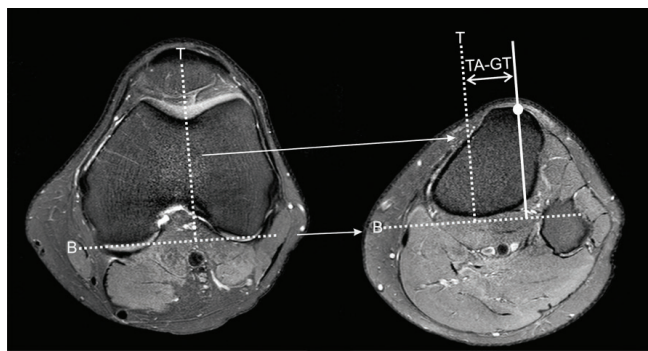


Fig. 6 - T2-weighted MRI with fat suppression in the axial plane, in extension, showing measurement of the TA-GT distance. Firstly, a line was traced out tangentially to the posterior femoral condyles (dashed line B), which was extended to the image in the plane of the anterior tuberosity of the tibia. Following this, two lines perpendicular to the posterior bicondylar line were traced out: one going through the center of the base of the trochlea (dashed line T), which was also extended; and the other (straight line) going through the center of the patellar ligament (circle), in the plane of its uppermost insertion into the tuberosity of the tibia. The TA-GT distance (double arrow) is the distance between these two lines, which are parallel to each other.

Table 1 - Prevalence of the findings from MRI.

| Abnormalities detected on MRI | n | % |
|---|---------|----|
| Bone contusion typical of transitory dislocation of the patella | 20 | 44 |
| Joint effusion | 22 | 49 |
| Lesion of the medial patellofemoral ligament | 13 | 29 |
| Chondral lesion: | 29 | 64 |
| Patellar cartilage | 29 | 51 |
| Patellar and femoral cartilages | 7 | 15 |
| Detached osteochondral fragment | 4 | 9 |
| Signal abnormality in the subchondral bone of the patella | 7 | 15 |
| Patellofemoral arthrosis | 5 | 12 |
| Morphological or joint geometry abnormalities: | 33 | 73 |
| High patella | 24 | 53 |
| Laterally inclined patella | 25 | 56 |
| Laterally displaced patella* | 13 (23) | 29 |
| Trochlear dysplasia | 23 | 51 |
| Increased TA-GT distance** | 11 (26) | 24 |
| Lesion of the medial meniscus | 2 | 4 |
| Fracture of the head of the fibula | 1 | 2 |

* measurements made on 23 knees;
** measurements made on 26 knees.

Results

MRI scans from 45 knees (n = 26 (58%) on the right side and n = 19 (42%) on the left side) were analyzed. These were from 39 patients (six presented bilateral clinical conditions and underwent MRI on both knees), of whom 19 were men (42%) and 26 were women (58%).

The ages of the patients studied ranged from 14 to 53 years, with a mean of 29 years (± 10) and median of 28 years. Twenty patients (44%) presented a bone contusion pattern typical of recent lateral transitory dislocation of the patella, in association with joint effusion. One patient presented bone edema relating to an impacted fracture in the head of the fibula, along with signs of recent transitory dislocation of the patella.

Signs of lesions of the patellofemoral ligament were identified in 13 patients (29%), and all of these patients also presented bone edema characteristic of recent dislocation of the patella, with presence of joint effusion and fluid infiltration adjacent to the medial retinaculum.

Thirty-six patients (64%) presented chondral lesions; patella cartilage lesions were identified in 29 patients (51%); and in seven cases (15%), a lesion in the femoral cartilage was also observed. A detached osteochondral fragment could be identified in four of the patients with patellar cartilage lesions. Edema of the subchondral bone relating to chondropathy was identified in seven patients (15%), while five patients (11%) presented signs of patellofemoral arthrosis, with reduction of the lateral patellofemoral joint space and presence of osteophytes. The ages of these five patients ranged from 29 to 53 years (mean of 44 ± 10 years). None of these patients presented any signs of arthrosis in the femorotibial compartment.

Morphological or joint geometry abnormalities that predisposed towards patellofemoral instability were found in 33 cases (73%), and these were characterized as follows: high patella (n = 24; 53%); lateral inclination of the patella beyond the physiological limits (n = 25; 56%); patella displace laterally (n = 13; 29%); and trochlear dysplasia (n = 23; 51%).

An increased TA-GT distance was found in 11 cases (24%), although this measurement could only be made in 26 knees (58% of the cases), because of non-inclusion of the insertion of the patella ligament in the tibial tuberosity, in the axial plane, in 19 cases.

Seventeen patients (38%) presented edema in the superolateral portion of the infrapatellar fat.

Discussion

Patellofemoral instability can be classified as acute or chronic. Acute instability is characterized by traumatic lateral dislocation of the patella and mainly affects adolescents and young adults. Up to 44% of these patients evolve to chronic instability.^{6,10} Chronic instability comprises episodes of recurrent dislocation, with greater risk of development of osteoarthritis.^{1,10-12} In the present study, only patients with a history of chronic instability were selected. Their mean age (28 ± 10 years) was similar to what has been reported in the

literature,^{10,13} with predominance of female patients (58%). In the present study group, 44% presented a bone contusion pattern typical of recent dislocation of the patella.

Many authors have taken the view that in most cases of chronic instability, there is a predisposing anatomical factor, and that the more intensely that these factors are present, the lower the intensity of the trauma required for dislocation to occur will be.^{1,2,12-14} The commonest predisposing factors are trochlea dysplasia, high patella and lateralization of the anterior tuberosity of the tibia, and recognition of these bone abnormalities is fundamental for defining the prognosis and for achieving the best therapeutic management.^{1,2,15}

For a long time, radiographic studies on the knee in anteroposterior, absolute lateral and patellar axial views were the main imaging methods available for evaluating the femoropatellar joint. These methods were fundamental for developing concepts relating to the dynamics of the extensor mechanism and for detecting morphological abnormalities of the trochlea.^{1,4,12,15}

However, radiographic studies performed in isolation present some important limitations. It is not very easy to obtain images in absolute lateral view,¹⁶ particularly without using fluoroscopy. The lateral view needs to be acquired rigorously, in order to adequately analyze the trochlea, given that rotations of just 5% may generate false positive or false negatives regarding trochlear dysplasia.¹⁴ Lateralization of the tibial tuberosity has also been implicated in instability, and measurement of the TA-GT distance has become critical data in making therapeutic decisions, since this enables quantitative analysis that is more reliable than the clinical examination. However, this measurement is also not accurate when made by means of radiographic images, as was demonstrated in the study by Wagenaar et al.¹⁷ For these reasons, CT scans have often been used in association with radiographic studies in evaluating these patients, since this enables measurement of the TA-GT distance, along with assessment of the positioning of the patella and the morphology of the trochlea.^{9,12,15,18}

Over the last few years, MRI has also emerged as an auxiliary method for investigating patellofemoral instability, particularly for detecting osteochondral lesions and for evaluating the MPFL, given that X-rays and CT scans are used primarily for bone assessments.^{5,10,13,19-21} Cartilage lesions of the patellofemoral compartment are generally related to instability,^{5,20} as also observed in the present study, in which chondral lesions were found in 64% of the cases. MRI presents sensitivity of around 90% for detecting osteochondral lesions in the knee, which may go unnoticed on X-rays in up to 60% of the cases, thus justifying performing MRI among these patients.^{2,5} Lesions of the joint cartilage predispose towards early arthrosis, and this was observed in five patients (12%), with a mean age of 44 ± 10 years.

MRI also presents excellent results for detecting lesions of the MPFL after acute dislocation of the patella, with estimated sensitivity of up to around 85%.^{2,6} In the present study, lesions of the MPFL were detected in 29% of the cases, although it has to be emphasized that in all of these cases, there had been a recent episode of dislocation of the patella, with presence of joint effusion and fluid adjacent to the stabilizing structures of the medial compartment, which seems to facilitate detection

of fiber discontinuity. Further studies will be needed in order to evaluate the accuracy of MRI for identifying lesions of the MPFL in cases in which there is no recent dislocation.

With greater use of MRI among patients presenting instability, several authors have noticed over recent years that MRI not only has good accuracy in detecting lesions of the cartilage and soft tissues, but also enables detection of predisposing factors.^{2,14,16,18,22}

In fact, in the present study, anatomical or joint geometry abnormalities that were considered to be predisposing factors for patellofemoral instability were identified in 73% of the cases. Trochlear dysplasia, which is considered to be one of the main risk factors for instability,²¹ was present in more than half of the cases and was easily identified using MRI, thus confirming the results from several authors who had stated that MRI was an excellent method for diagnosing trochlear dysplasia.^{2,14,16,21,22} It was also possible to identify high patella and patellar inclination beyond the physiological limits in 53% and 56% of the cases, respectively, thus confirming the high prevalence of morphological abnormalities of the trochlea and of patellar positioning among these patients.

Measurement of the TA-GT distance is one of the main reasons for requesting tomographic evaluations among patients with patellofemoral instability.^{9,12,15,18} With the growing need for evaluation of ligament and joint cartilage integrity, many patients have started to undergo three types of imaging diagnostics: X-ray, CT scan and MRI, which increases the cost. This has led many authors to try to adapt the measurements made using CT, including measurement of the TA-GT distance, for MRI, with excellent results.^{1,2,10,14,16,18,22}

Although comparison between the findings from MRI and CT scans was not among the objectives of the present study, we can affirm that it was possible in the majority of the cases to identify the main morphological and joint geometry abnormalities that predispose towards instability.

However, MRI also presents some limitations. Because it is an operator-dependent method, the images are not always acquired in an ideal manner such that measurements can be made in accordance with the criteria established in the literature. This was found in the present study, in which it was not possible to measure the TA-GT distance in 42% of the cases, because of failure to identify the insertion of the patellar ligament on images in the axial plane. One attenuating factor was the fact that a large portion of these patients had already undergone CT examination previously, with tomographic measurement of the TA-GT distance, and MRI was only indicated for detection of other abnormalities. Nonetheless, this indicates that unless special attention is given to inclusion of the tuberosity of the tibia in the axial plane, it can easily be excluded from the study. Another limiting factor of MRI is that because of the physiological lateralization and inclination of the patella in extension, evaluation of these parameters should be done with the knee flexed, which is not part of the habitual routine of MRI on the knee and is not possible on any equipment. For this reason, the examination needs to be guided by a radiologist who is familiar with the recommended protocols for evaluating instability by means of MRI, as well as the need for availability of apparatus and coils of a design that allows image acquisition in this position.

Despite these limitations, the capacity to combine evaluation on bone, cartilage and soft-tissue structures has meant that in many centers, MRI is today considered to be the preferred imaging method for evaluating patellofemoral instability, thus replacing CT, with the additional benefit of not exposing patients to the risks of ionizing radiation.^{2,18,22}

Conclusion

This study demonstrated that MRI contributed towards making the diagnosis, detecting factors that predispose towards instability and identifying lesions that tend not to be identified on X-rays and CT scans, such as cartilaginous lesions and those of the MPFL. In addition, this study also demonstrated other unsuspected lesions, such as fractures of the head of the fibula and meniscal lesions in some cases. However, further studies comparing the methods will be necessary in order to determine whether MRI is really capable of replacing CT scans in our setting.

Conflicts of interest

The authors declare that there was no conflict of interests in conducting this study.

REFERENCES

- Andrish J. The management of recurrent patellar dislocation. *Orthop Clin North Am.* 2008;39(3):313-27.
- Biedert RM, Bachmann M. Anterior-posterior trochlear measurements of normal and dysplastic trochlea by axial magnetic resonance imaging. *Knee Surg Sports Traumatol Arthrosc.* 2009;17(10):1225-30.
- Colvin AC, West RV. Patellar instability. *J Bone Joint Surg Am.* 2008;90(12):2751-62.
- Christian SR, Anderson MB, Workman R, Conway WF, Pope TL. Imaging of anterior knee pain. *Clin Sports Med.* 2006;25(4):681-702.
- Diederichs G, Issever AS, Scheffler S. MR imaging of patellar instability: injury patterns and assessment of risk factors. *Radiographics.* 2010;30(4):961-81.
- Elias DA, White LM. Imaging of patellofemoral disorders. *Clin Radiol.* 2004;59(7):543-57.
- Fithian DC, Neyret P, Servien E. Patellar instability: the Lyon experience. *Techniques in Knee Surgery.* 2007;6(2):112-23.
- Gomes JLE, Marczyk LRS, De César PC, Jungblut CF. Reconstrução do ligamento patelofemoral medial: sua indicação na luxação da patela. *Rev Bras Ortop.* 2003;38(1/2):56-66.
- Hernandez AJ, Favaro E, Laraya MHF. Luxação aguda da patela. *Rev Bras Ortop.* 2004;39(1):65-74.
- Keser S, Savranlar A, Bayar A, Ege A, Turhan E. Is there a relationship between anterior knee pain and femoral trochlear dysplasia? Assessment of lateral trochlear inclination by magnetic resonance imaging. *Knee Surg Sports Traumatol Arthrosc.* 2008;16(10):911-5.
- Koëter S, Horstmann WS, Wagenaar FBM, Huysse W, Wymenga AB, Anderson PG. A new CT scan method for measuring the tibial tubercle trochlear groove distance in patellar instability. *The Knee.* 2007;14(2):128-32.
- Lim AKS, Chang HC, Hui JHP. Recurrent patellar dislocation: reappraising our approach to surgery. *Ann Acad Med Singapore.* 2008;37(4):320-3.
- Lustig S, Servien E, Ait Si Selmi T, Neyret P. Factors affecting reliability of TT-TG measurements before and after medialization: a CT scan study. *Rev Chir Orthop.* 2007;92(5):429-36.
- Merchant AC. Patellofemoral Imaging. *Clin Orthop Relat Res.* 2001;(389):15-21.
- Nomura E, Inoue M, Kurimara M. Chondral and osteochondral injuries associated with acute patellar dislocation. *Arthroscopy.* 2003;19(7):717-21.
- Pfarrmann CWA, Zanetti M, Romero J, Hodler J. Femoral trochlear dysplasia: MR findings. *Radiology.* 2000;216(3):858-64.
- Wagenaar FCBM, Koëter S, Anderson PG, Wymenga AB. Conventional radiography cannot replace CT scanning in detecting tibial tubercle lateralization. *The Knee.* 2007;14(1):51-4.
- Sanders TG, Paruchuri NB, Michael B, Zlatkin MB. MRI of osteochondral defects of the lateral femoral condyle: incidence and pattern of injury after transient lateral dislocation of the patella. *AJR.* 2006;187(5):1332-7.
- Schoettle PB, Zanetti M, Seifert B, Pfarrmann CWA, Fucentese SF, Romero J. The tibial tuberosity-trochlear groove distance: a comparative study between CT and MRI scanning. *The Knee.* 2006;13(1):26-31.
- Stefancin JJ, Parker RD. First-time traumatic patellar dislocation: a systematic review. *Clin Orthop Relat Res.* 2007;455:93-101.
- Toms AP, Cahir J, Swift L, Donell ST. Imaging the femoral sulcus with ultrasound, CT, and MRI: reliability and generalizability in patients with patellar instability. *Skeletal Radiol.* 2009;38(4):329-38.
- White BJ, Sherman OH, Bull NYU. Patellofemoral instability. *Hosp Jt Dis.* 2009;67(1):22-9.