



## Case Report

# Hindfoot aneurysmal bone cyst: report of two cases<sup>☆</sup>



Alexandre Luiz Dal Bosco<sup>a,\*</sup>, Marcos Ceita Nunes<sup>a</sup>, Jung Ho Kim<sup>a</sup>,  
Luis Gustavo Calieron<sup>a</sup>, Rubens Rosso Nadal<sup>a,b</sup>

<sup>a</sup> Instituto de Ortopedia e Traumatologia, Passo Fundo, RS, Brazil

<sup>b</sup> Universidade Federal da Fronteira Sul (UFFS), Passo Fundo, RS, Brazil

## ARTICLE INFO

## Article history:

Received 9 November 2016

Accepted 6 March 2017

Available online 23 February 2018

## Keywords:

Aneurysm

Bone cysts

Foot diseases

Bone neoplasms

## ABSTRACT

Osseous tumors of the hindfoot are not usual in the literature, the diagnosis in these cases is difficult and can often go unnoticed. Besides that, surgery and reconstruction are complicated due to the complexity of the local anatomy, which makes these lesions even more challenging for the orthopedic oncological professionals. On the following article two cases of aneurysmal bone cyst of the hindfoot are reported, as well as the alternatives and peculiarities in conducting these cases according to the oncological principles. When the subject are hindfoot tumor lesions, the early diagnosis is extremely important, as well as the proper staging and the management of the case by the orthopedic oncological professional according to oncological principles.

© 2018 Sociedade Brasileira de Ortopedia e Traumatologia. Published by Elsevier Editora Ltda. This is an open access article under the CC BY-NC-ND license (<http://creativecommons.org/licenses/by-nc-nd/4.0/>).

## Cisto ósseo aneurismático do retopé: relato de dois casos

## RESUMO

Os tumores do retopé são raros na literatura, o diagnóstico é difícil e muitas vezes é feito pelo profissional menos experiente. Acrescente-se a isso o fato de o tratamento cirúrgico e a reconstrução serem complicados pela intrincada anatomia local. Essas lesões são desafiadoras para o ortopedista oncológico. Relatamos dois casos de cisto ósseo aneurismático do retopé e nossas opções e particularidades na condução deles de acordo com os princípios oncológicos. Nas lesões tumorais do retopé é importante a suspeita diagnóstica precoce, bem como o estadiamento adequado e a condução do caso de acordo com os princípios oncológicos, preferencialmente pelo ortopedista oncológico.

© 2018 Sociedade Brasileira de Ortopedia e Traumatologia. Publicado por Elsevier Editora Ltda. Este é um artigo Open Access sob uma licença CC BY-NC-ND (<http://creativecommons.org/licenses/by-nc-nd/4.0/>).

## Palavras-chave:

Aneurisma

Cistos ósseos

Doenças do pé

Neoplasias ósseas

<sup>☆</sup> Study conducted at Serviço de Ortopedia Pediátrica e Cirurgia Oncológica, Instituto de Ortopedia e Traumatologia de Passo Fundo, Passo Fundo, RS, Brazil.

\* Corresponding author.

E-mail: [alexandredb1@yahoo.com.br](mailto:alexandredb1@yahoo.com.br) (A.L. Bosco).

<https://doi.org/10.1016/j.rboe.2018.02.007>

2255-4971/© 2018 Sociedade Brasileira de Ortopedia e Traumatologia. Published by Elsevier Editora Ltda. This is an open access article under the CC BY-NC-ND license (<http://creativecommons.org/licenses/by-nc-nd/4.0/>).

## Introduction

Tumors of the hindfoot are rarely described in the literature; the diagnosis is usually difficult to attain from a general practitioner. Often, the only known complaint is pain and it is related to traumatic events, which requires a high index of suspicion for the diagnosis.

Aneurysmal bone cyst is a benign, locally aggressive tumor that occurs primarily in the first two decades of life. It accounts for 1–2% of primary bone tumors and, if not treated properly, has a risk of local recurrence, followed by destruction of the

joint and significant functional deficit. Due to the complexity of such tumors, the correct management and follow-up should be conducted by an orthopedic oncologist.

The authors report the presentation of two cases of aneurysmal bone cyst of the hindfoot and their respective management.

## Case report 1

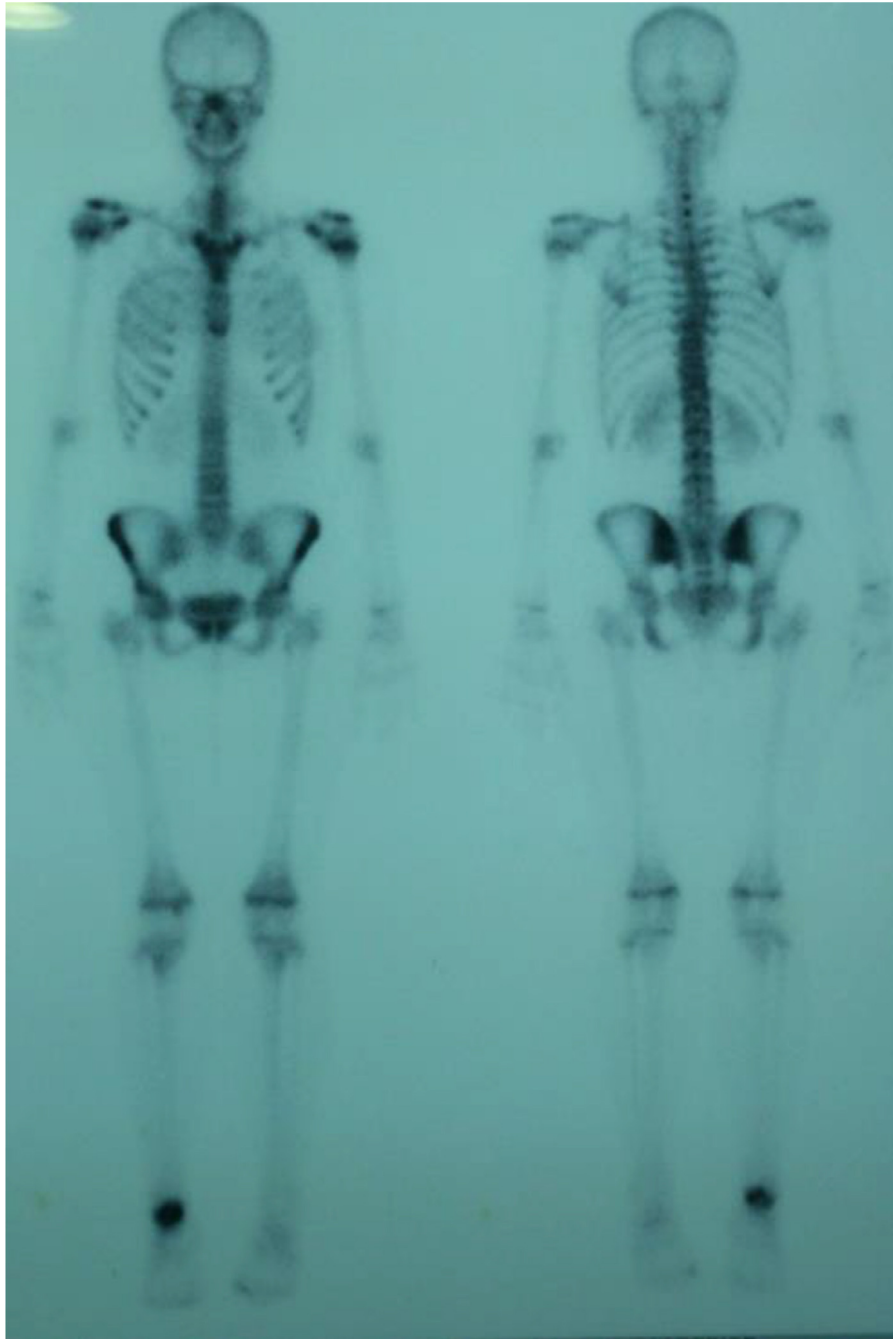
A female patient, aged 18 years, had pain in the right ankle; radiography showed a lytic lesion in the body of the talus,

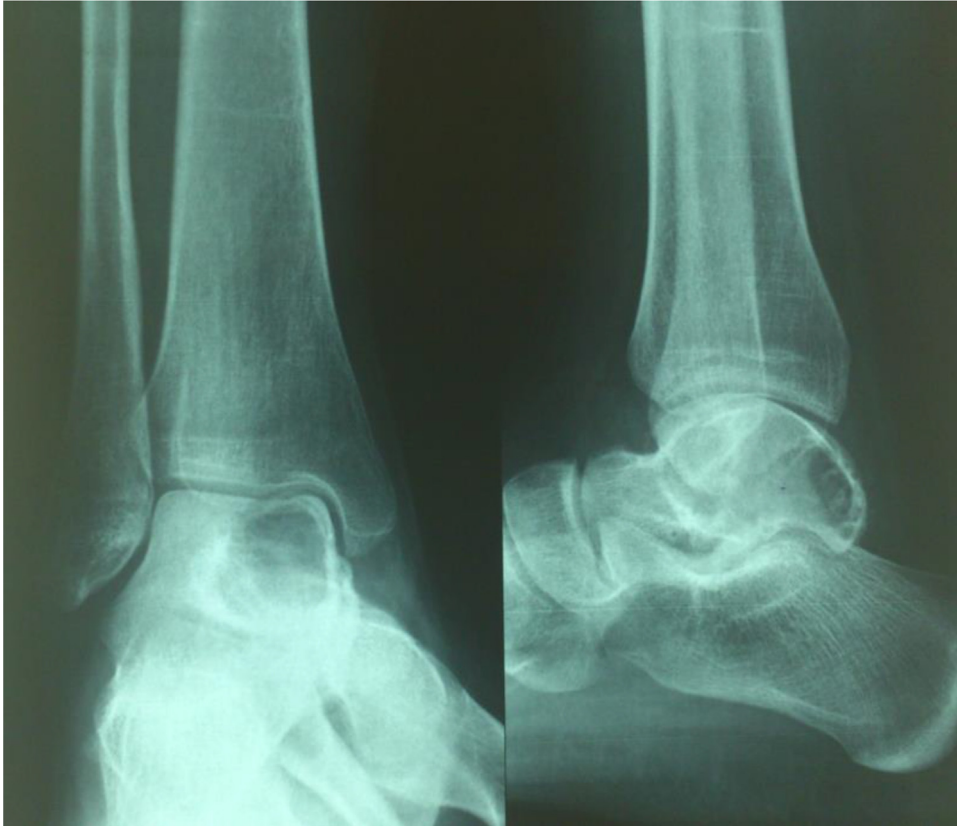

Fig. 1 – Radiograph of the right ankle showing a lytic lesion in the talus.

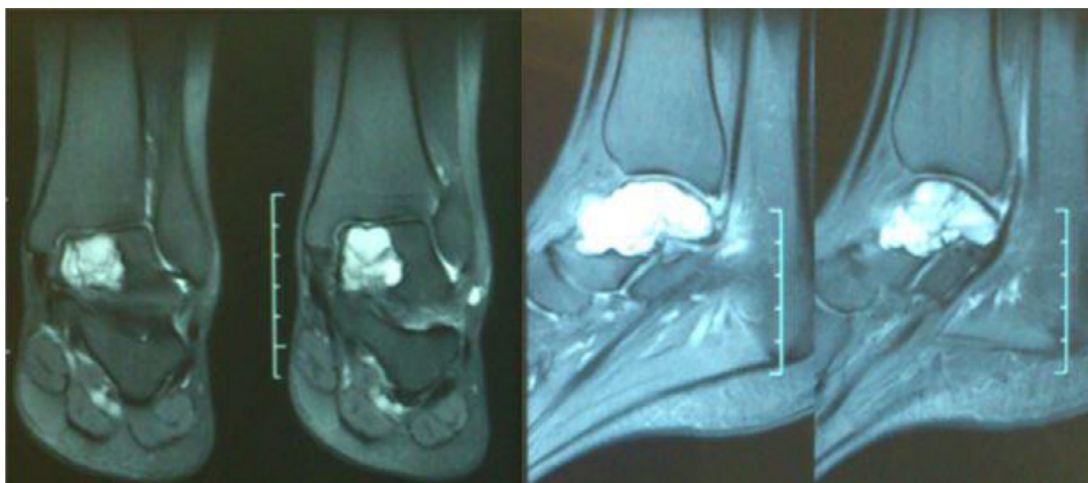

Fig. 2 – Magnetic resonance imaging indicating lesion with hypersignal on T2.



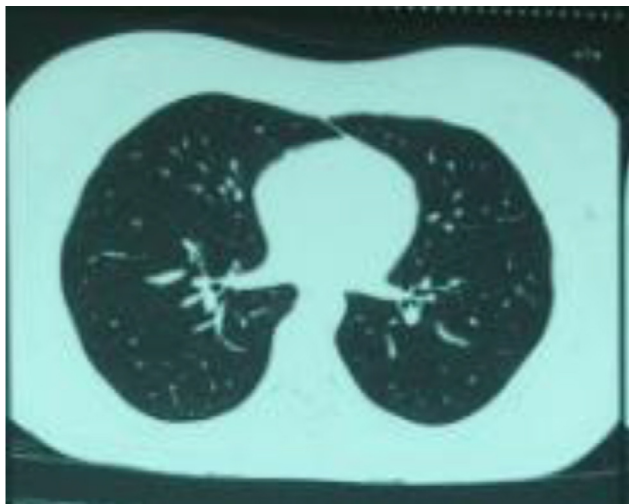
**Fig. 3 – Total skeletal bone scan with technetium-99 indicating massive flow and pool response in the right ankle.**

with irregular borders, an insuflative aspect, eccentric, without sclerosis, with apparent thinning of the posterior cortex (Fig. 1).

On T2 weighted magnetic resonance imaging the segment evidenced a lesion with no evidence of fluid, and preserved cortices (Fig. 2).

Total skeletal bone scan showed direct ankle flow and pool response in the three phases of the examination (Fig. 3); chest computed tomography showed no lesions (Fig. 4). After needle biopsy, the diagnostic suspicion of aneurysmal bone cyst was confirmed.

Due to the fact that the lesion was located in a weight-bearing area, with preservation of the talar dome cartilage, and considering the age of the patient, the authors opted for a marginal resection of the lesion with curettage and adjuvant electrocauterization; subsequently, a biological reconstruction was performed using a cancellous bone autograft from the iliac crest. The posterior access was used for the procedure; in the postoperative period, early mobilization was initiated on the second day. Weight-bearing was not permitted for 12 weeks, until bone graft integration was confirmed radiographically (Fig. 5).

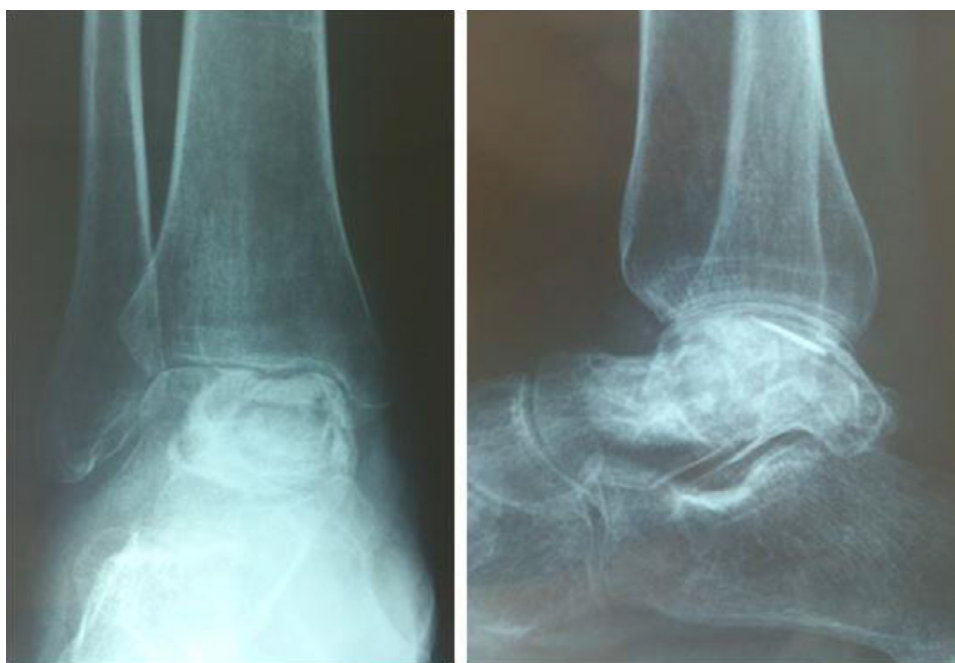

**Fig. 4 – Axial image of chest tomography showing no evidence of metastatic lesions.**

After one year of postoperative follow-up, the patient is painless with good joint mobility, and with no signs of relapse.

### Case report 2

A 46-year-old male patient reported a history of a right calcaneal lesion for approximately eight years. At the time, the lesion was removed; the result was inconclusive and, according to the patient, “they were not able to remove the entire lesion.” Now the patient complains of pain in the region of the medial scar, limitation of joint mobility, and volume increase. Local radiography, magnetic resonance imaging, chest tomography, skeletal bone scan, and biopsy were performed.



**Fig. 5 – Right ankle radiograph, one year postoperatively, showing optimal graft integration and joint preservation.**

Radiography indicated an insuflative lesion with a “bulbous” aspect without cortical sclerosis (Fig. 6). Magnetic resonance imaging demonstrated a calcaneal lesion with hypersignal and heterogeneous areas on T2 weighted MRI, hyposignal on T1 weighted MRI with, cortical insuflation, large lesion of the subtalar joint, and involvement of the sustentaculum tali, but without involvement of the calcaneo cuboid joint (Fig. 7).

Chest tomography indicated the absence of metastatic lesions, and bone scan confirmed a single lesion in the calcaneus. A biopsy confirmed the diagnosis of aneurysmal bone cyst. Subsequently, for preoperative planning, a local tomography was performed, which confirmed the destruction of the subtalar joint (Figs. 8–10).

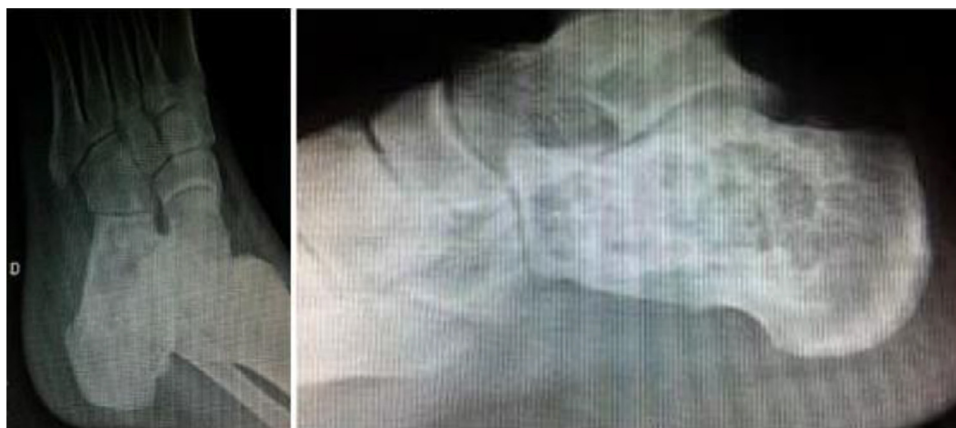A medial approach was used, with curettage and adjuvant electrocauterization after dehydrated alcohol (Fig. 11). Then, a reconstruction was made using a tricortical biological graft from the iliac crest. The subtalar joint, as evidenced by the tomography, was destroyed by the lesion; therefore, the authors opted for primary subtalar arthrodesis with self-compression screws (Figs. 12 and 13).

At present, with a three-year follow-up, the patient has returned to daily activities, without pain or functional limitations, and with excellent graft integration and no signs of relapse.

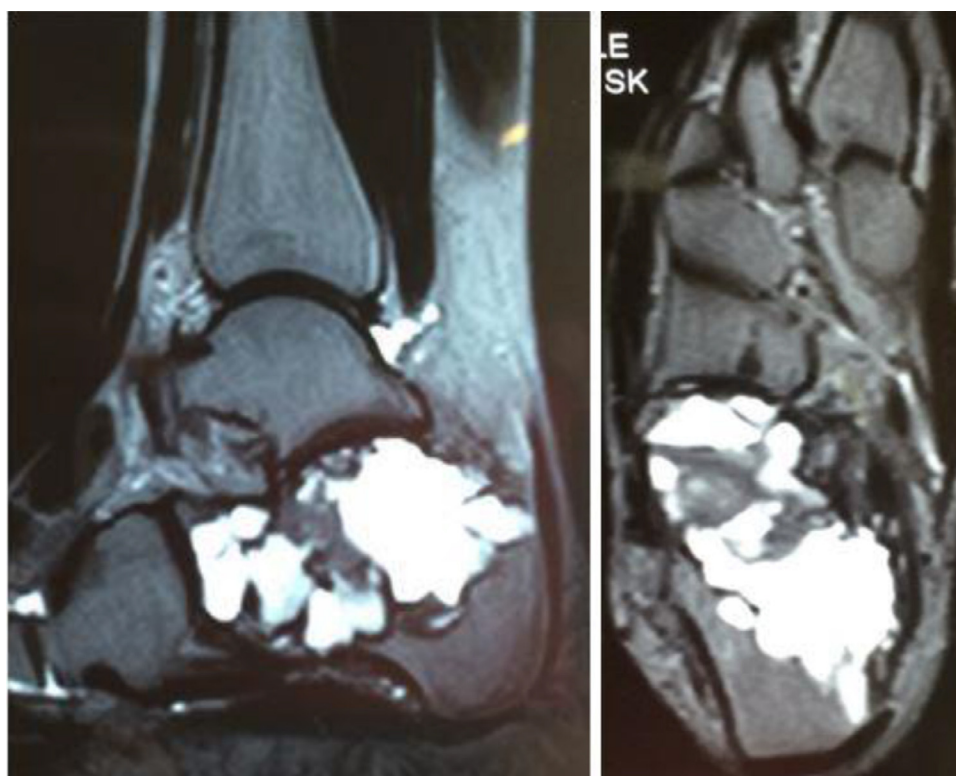
### Discussion

Foot tumors are uncommon and constitute a major problem in orthopedics; few reviews in the literature describe their behavior and the epidemiology is not well known. Bone tumors are known to be more common in the forefoot and hindfoot, while soft-tissue tumors are more common in the midfoot and have a higher prevalence in females.<sup>1</sup>





**Fig. 6 – Right foot radiograph indicating lesion with lytic and insuflated aspect on the calcaneus.**



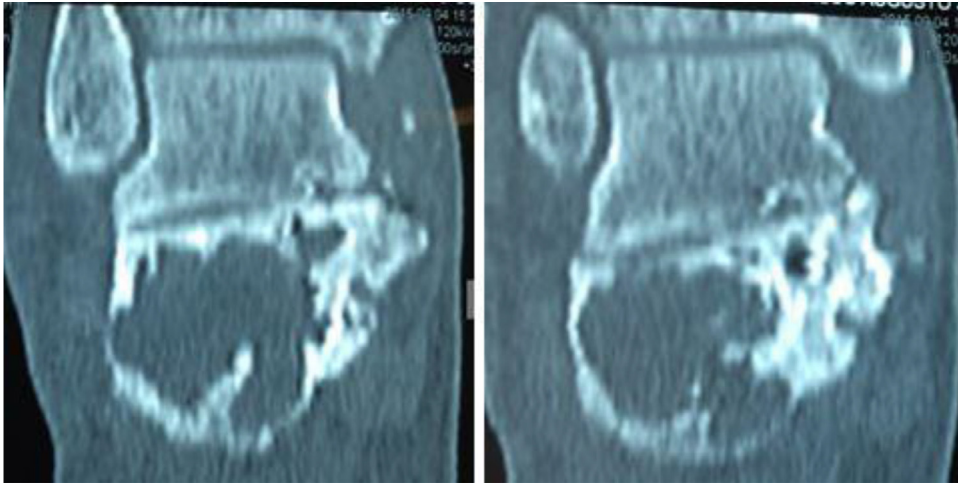
**Fig. 7 – Magnetic resonance imaging indicating lesion with hypersignal on T2.**

Primary tumors of bone in the foot account for 3% of bone neoplasms. Among the most common sites of the foot, the vast majority of tumors are located in the metatarsals and calcaneus, with 31% of benign and 35%, malignant lesions.<sup>2</sup> The literature presents few cases of hindfoot tumors. The non-diagnosis of these lesions reported in the literature is attributed to many factors, such as rarity, lack of knowledge of the complex anatomy of this region of the foot, low index of suspicion by the non-specialized orthopedist, and the great variability of the presentation of bone tumors when located in the hindfoot.<sup>3,4</sup> Thus, a high index of locally aggressive lesions with metastases installed at the time of diagnosis was observed.

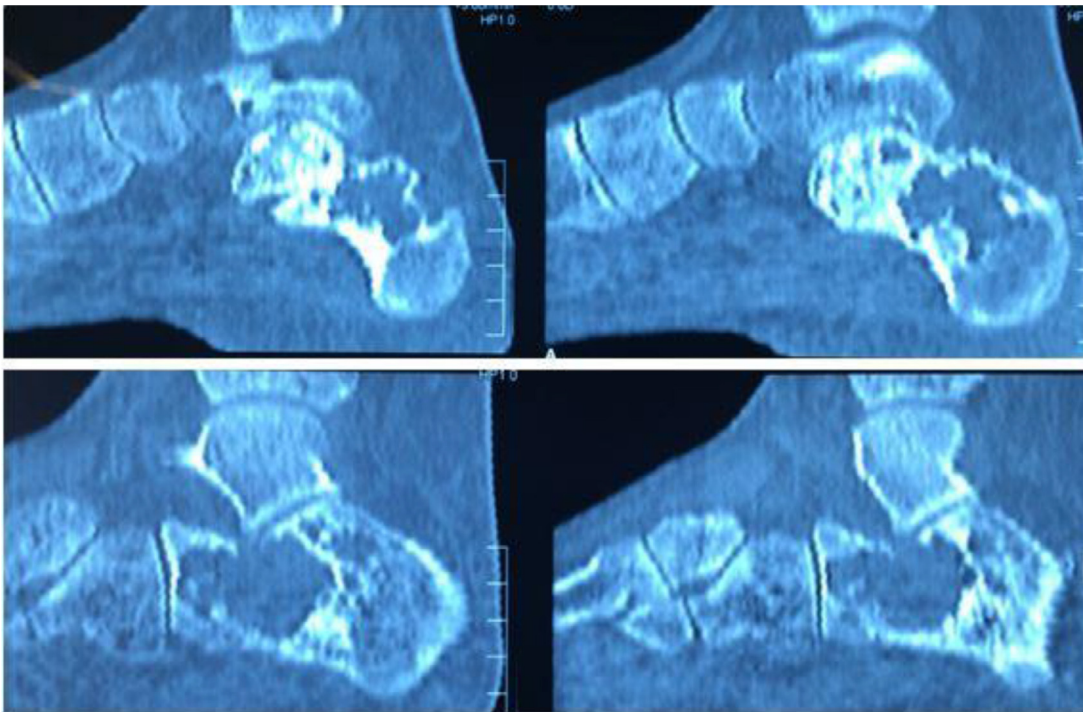
Pain is the most commonly described symptom, particularly in talar tumors, and is more severe in malignant lesions; often, the complaint that leads to seeking care is the association with a common trauma. This fact induces underdiagnosis and inadequate treatments based on traumatic history. Edema and swelling are most strongly associated with malignancy.

A pathological fracture may be present as the initial diagnosis, especially in the case of cystic lesions.<sup>5,6</sup>

In a retrospective study by Young et al.,<sup>7</sup> in which 57 patients were evaluated, the ratio between benign and malignant lesions was 1.6:1 in the calcaneus and 6.7:1 in the talus. In calcaneal lesions, the most common tumor was simple bone cyst (one-third of which with pathological fracture); in the



**Fig. 8 – A coronal view of an ankle tomography indicating involvement of the sustentaculum tali.**



**Fig. 9 – Sagittal views of an ankle tomography indicating preserved calcaneo cuboid joint and destruction of the subtalar joint.**

talus, the most common lesion was osteoid osteoma, followed by chondroblastoma. Osteosarcoma was the main malignant lesion found; one-third of the cases had pre-existing Paget's disease.

In the study by Murrari et al.,<sup>2</sup> the benign:malignant ratio observed in the talus was 2.8:1 and in the calcaneus, 5:1; benign lesions were predominant in males, with a mean age of 25 years.

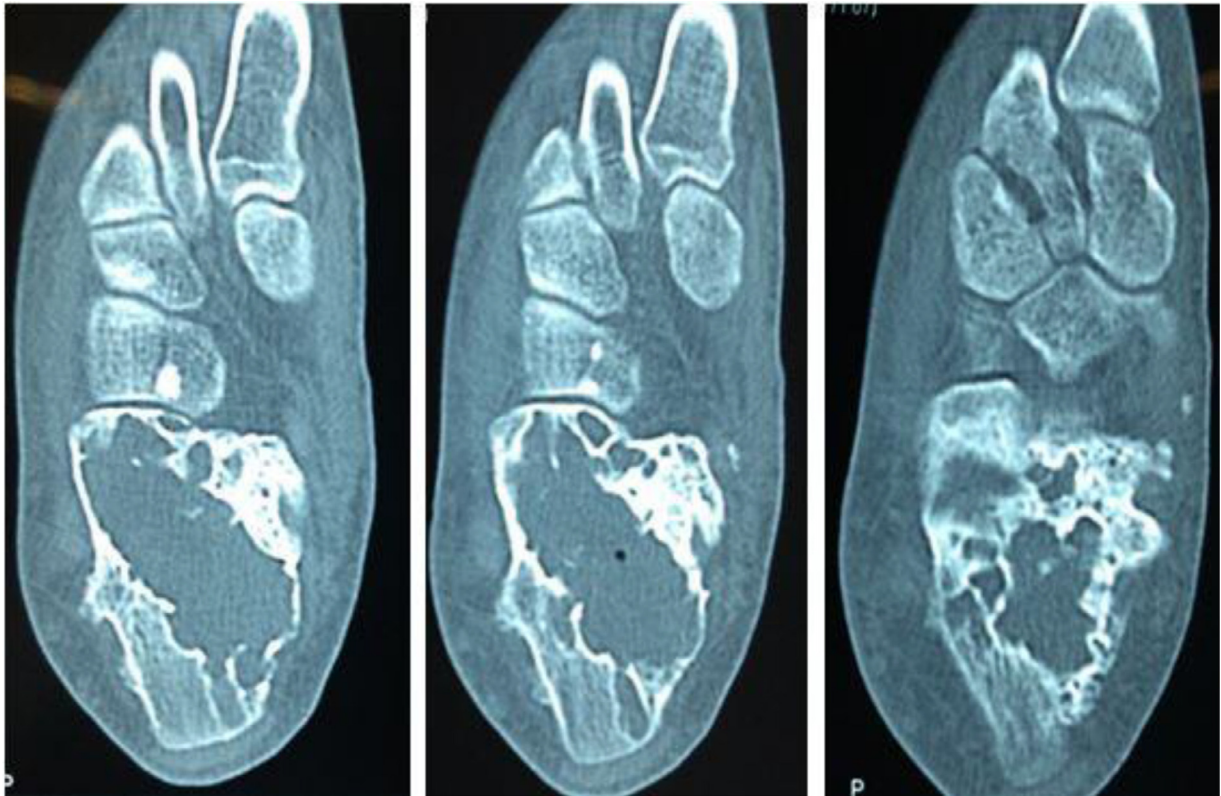
Kinoshita et al.<sup>8</sup> described 83 cases of foot tumors, but only 12 cases of hindfoot tumors, most of which were benign and of chondrogenic origin: three osteochondromas, two chondroblastomas, and three simple cysts. These authors reported

only three malignant tumors, one chondrosarcoma, and two metastases; in their series, male predominance was also observed.

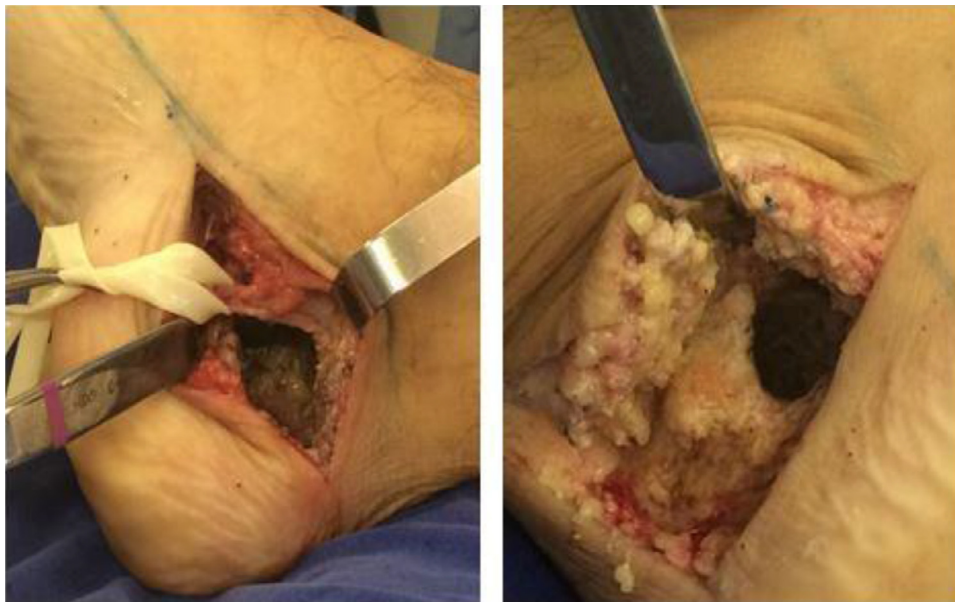Chondrosarcoma has been described in the literature as having a preference for the hindfoot, especially the calcaneus<sup>9</sup>; high-grade tumors produce pulmonary metastases.

High-grade sarcomas often present a high incidence of pulmonary and bone metastases at the time of diagnosis, reinforcing the importance of early diagnosis to positively influence the outcome of the disease.





**Fig. 10 – Axial view of an ankle tomography showing the extent of a lesion in the body of the calcaneus.**

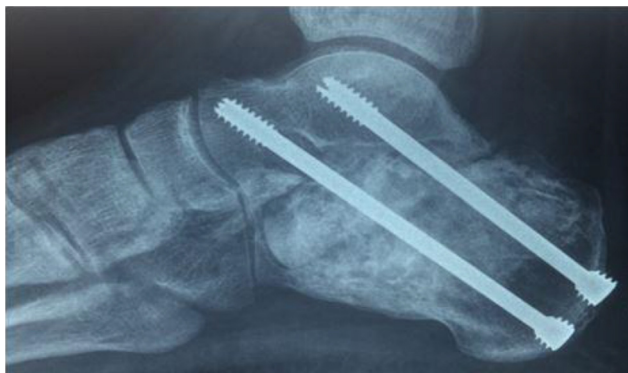

**Fig. 11 – Medial approach of the calcaneus, curettage of the lesion with protection and preservation of the neurovascular bundle.**

Primary aneurysmal bone cyst does not have a clearly defined etiology and is considered a type of vascular malformation, an arteriovenous fistula, or, when secondary, may be associated with other tumor lesions, such as giant cell tumor, chondroblastoma, osteoblastoma, and osteosarcoma. Therefore, biopsy is mandatory

for diagnostic confirmation and exclusion of associated lesions.<sup>10,11</sup>

In the study by Rastogi et al.,<sup>12</sup> a review of 72 cases of aneurysmal bone cyst treated with sclerotherapy, only three cases were described in the foot, and the mean age of the patients was 15 years.



**Fig. 12 – Postoperative lateral view radiograph of the ankle showing the self-compression screws and subtalar arthrodesis.**

Several types of treatment have been described, and include only observation, alcohol injection, steroids, embolization, resection, or intralesional curettage.

Periarticular location, physeal distance less than 2.5 cm, open physis, incomplete resection, number of mitoses, high Enneking stages, pathological fracture, female gender, and age less than 12 years are risk factors for local recurrence. In the studies evaluated, ethnicity was not a significant variable.<sup>13-15</sup> Typically, the treatment of the primary aneurysmal bone cyst, after biopsy, is intralesional resection followed by an adjuvant method, which aims at extending the peritumoral necrosis zone and eliminating possible cells. Curettage alone, without adjuvants, has a recurrence rate of around 31%; however, when associated with another method, such as phenol,

liquid nitrogen, polymethylmethacrylate, electrocauterization, or argon plasma, these rates are reduced to 3.7% up to 18%.<sup>15,16</sup>

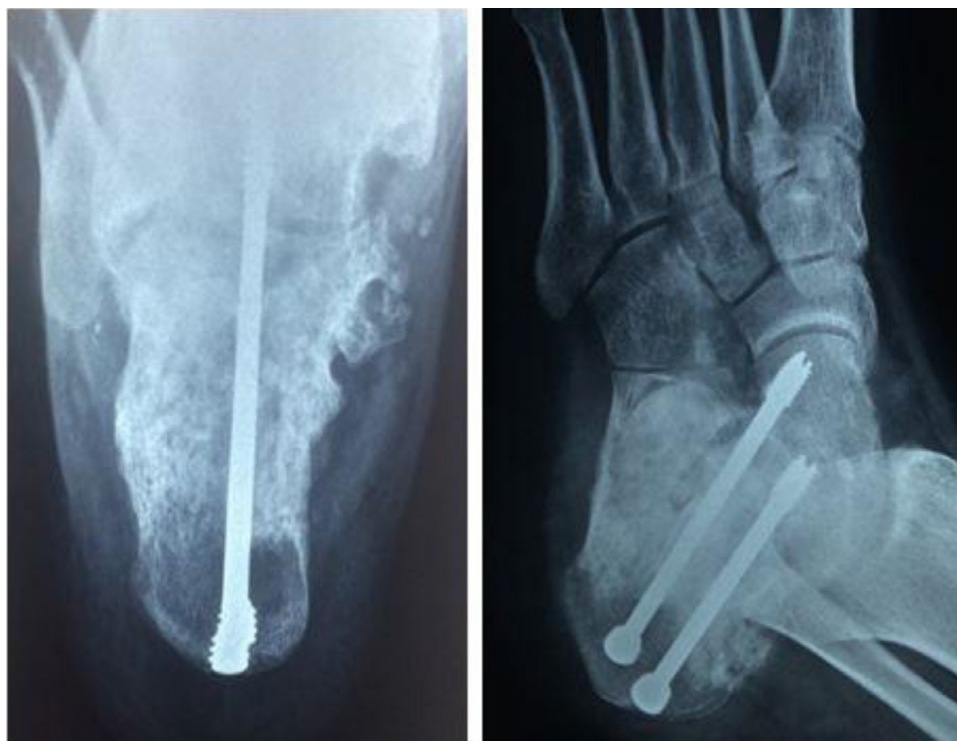The choice of the type of reconstruction after the removal of the lesion depends on the anatomical site; the natural history of this tumor indicates that reossification will occur after tumor removal, but this mechanism is not well known.

Preoperative embolization is a good option to reduce intraoperative bleeding in the case of very large lesions. Radiotherapy has been described as an option in places with difficult surgical access. However, it offers too many side effects that arise from radiation exposure.<sup>17</sup>

Less invasive methods of treatment, without curettage of the tumor mass, may be used. Scaglietti described good results with steroid injections; however, several reapplications are necessary. Based on its mechanism of action in suppressing the osteoclastic activity of the lesion, calcitonin infiltration has been suggested by some authors.<sup>18,19</sup>

Methylmethacrylate bone cement presents advantages when used as an adjuvant, as the high temperatures reached during its polymerization allow immediate weight-bearing. However, for young patients and lesions very close to the articular cartilage, it is a choice exception, as it presents the risk of intra-articular migration and development of early arthrosis.<sup>15</sup>

The use of a material that stimulates osteoinduction and osteoconduction is desired and has better results than demineralized bone graft alone. The iliac trabecular graft meets these two requirements, with low cost and low morbidity. Other authors have reported good results with demineralized grafting associated with bone marrow aspirate in the lesion.<sup>20-22</sup>



**Fig. 13 – Axial and oblique postoperative radiographs of the calcaneus indicating good bone graft integration and screw positioning.**



## Conclusion

Tumors of the hindfoot are rare, but have high destructive potential, as they are close to important joints, such as the tibiotalar and talocalcaneal; they substantially hinder weight-bearing in the lower limb, with serious functional repercussions. The diagnosis is complicated by the complex anatomy of the region and is often late, either with advanced local destruction or distant metastases. Lesion resection and subsequent oncologic reconstruction are also hindered by these factors.

Aneurysmal bone cyst, despite being classified as a "benign" lesion, should be adequately treated according to oncological principles in order to minimize local recurrences and complications. In cases of tumor lesions of the hindfoot, evaluation and staging by an oncological surgeon as soon as possible is paramount.

## Conflicts of interest

The authors declare no conflicts of interest.

## REFERENCES

- Kirby EJ, Shereff MJ, Lewis MM. Soft-tissue tumors and tumor-like lesions of the foot. An analysis of eighty-three cases. *J Bone Jt Surg Am.* 1989;71(4):621-6.
- Murari TM, Callaghan JJ, Berrey BH Jr, Sweet DE. Primary benign and malignant osseous neoplasms of the foot. *Foot Ankle.* 1989;10(2):68-80.
- Biscaglia R, Gasbarrini A, Böhling T, Bacchini P, Bertoni F, Picci P. Osteosarcoma of the bones of the foot – an easily misdiagnosed malignant tumor. *Mayo Clin Proc.* 1998;73(9):842-7.
- Dhillon MS, Singh B, Singh DP, Prabhu V, Nagi ON. Primary bone tumors of the talus. *J Am Podiatr Med Assoc.* 1994;84(8):379-84.
- Kilgore WB, Parrish WM. Calcaneal tumors and tumor-like conditions. *Foot Ankle Clin.* 2005;10(3):541-65.
- Monroe MT, Manoli A 2nd. Osteoid osteoma of the lateral talar process presenting as a chronic sprained ankle. *Foot Ankle Int.* 1999;20(7):461-3.
- Young PS, Bell SW, MacDuff EM, Mahendra A. Primary osseous tumors of the hindfoot: why the delay in diagnosis and should we be concerned? *Clin Orthop Relat Res.* 2013;471(3):871-7.
- Kinoshita G, Matsumoto M, Maruoka T, Shiraki T, Tsunemi K, Futani H, et al. Bone and soft tissue tumours of the foot: review of 83 cases. *J Orthop Surg (Hong Kong).* 2002;10(2):173-8.
- Ogose A, Unni KK, Swee RG, May GK, Rowland CM, Sim FH. Chondrosarcoma of small bones of the hands and feet. *Cancer.* 1997;80(1):50-9.
- Enneking WF, Dunham W, Gebhardt MC, Malawar M, Pritchard DJ. A system for the functional evaluation of reconstructive procedures after surgical treatment of tumors of the musculoskeletal system. *Clin Orthop Relat Res.* 1993;(286):241-6.
- Martinez V, Sissons HA. Aneurysmal bone cyst. A review of 123 cases including primary lesions and those secondary to other bone pathology. *Cancer.* 1988;61(11):2291-304.
- Rastogi S, Varshney MK, Trikha V, Khan SA, Choudhury B, Safaya R. Treatment of aneurysmal bone cysts with percutaneous sclerotherapy using polidocanol. A review of 72 cases with long-term follow-up. *J Bone Jt Surg Br.* 2006;88(9):1212-6.
- Leithner A, Windhager R, Lang S, Haas OA, Kainberger F, Kotz R. Aneurysmal bone cyst. A population based epidemiologic study and literature review. *Clin Orthop Relat Res.* 1999;(363):176-9.
- Gibbs CP Jr, Hefele MC, Peabody TD, Montag AG, Aithal V, Simon MA. Aneurysmal bone cyst of the extremities. Factors related to local recurrence after curettage with a high-speed burr. *J Bone Jt Surg Am.* 1999;81(12):1671-8.
- Steffner RJ, Liao C, Stacy G, Atanda A, Attar S, Avedian R, et al. Factors associated with recurrence of primary aneurysmal bone cysts: is argon beam coagulation an effective adjuvant treatment? *J Bone Jt Surg Am.* 2011;93(21):e1221-9.
- Cottalorda J, Bourelle S. Modern concepts of primary aneurysmal bone cyst. *Arch Orthop Trauma Surg.* 2007;127(2):105-14.
- Papagelopoulos PJ, Choudhury SN, Frassica FJ, Bond JR, Unni KK, Sim FH. Treatment of aneurysmal bone cysts of the pelvis and sacrum. *J Bone Jt Surg Am.* 2001;83(11):1674-81.
- Scaglietti O, Marchetti PG, Bartolozzi P. Final results obtained in the treatment of bone cysts with methylprednisolone acetate (depo-medrol) and a discussion of results achieved in other bone lesions. *Clin Orthop Relat Res.* 1982;(165):33-42.
- Szendrői M, Antal I, Liszka G, Kónya A. Calcitonin therapy of aneurysmal bone cysts. *J Cancer Res Clin Oncol.* 1992;119(1):61-5.
- Delloye C, De Nayer P, Malghem J, Noel H. Induced healing of aneurysmal bone cysts by demineralized bone particles. A report of two cases. *Arch Orthop Trauma Surg.* 1996;115(3-4):141-5.
- Delloye C [thesis] The bridging capacity of a cortical bone defect by different bone grafting materials and diaphyseal distraction lengthening. Louvain-la-Neuve, Belgique: Université Catholique de Louvain; 1990.
- Docquier PL, Delloye C. Treatment of aneurysmal bone cysts by introduction of demineralized bone and autogenous bone marrow. *J Bone Jt Surg Am.* 2005;87(10):2253-8.