



## Original Article

# Periacetabular hip osteotomy for residual dysplasia treatment: preliminary results<sup>☆</sup>



Vinicius de Brito Rodrigues<sup>a,\*</sup>, Josiano Valério<sup>b</sup>, Francisco Zaniolo<sup>b</sup>, Mark Deeke<sup>b</sup>, Marco Pedroni<sup>b</sup>, Ademir Schuroff<sup>b</sup>

<sup>a</sup> Hospital Geral de Vitória da Conquista, Vitória da Conquista, BA, Brazil

<sup>b</sup> Hospital Universitário Cajuru, Curitiba, PR, Brazil

## ARTICLE INFO

## Article history:

Received 1 March 2017

Accepted 4 April 2017

Available online 5 April 2018

## Keywords:

Osteotomy

Acetabulum

Hip dislocation

Biomechanical phenomena

## ABSTRACT

**Objective:** To evaluate whether the change in the CE angle of Wiberg and the acetabular index after Ganz periacetabular osteotomy is statistically significant.

**Methods:** The pre- and postoperative CE angle of Wiberg and acetabular index of 14 hips operated at a tertiary hospital in Curitiba, Paraná, Brazil were evaluated.

**Results:** The postoperative measurements showed significant differences in relation to the preoperative period. There was a significant reduction in the CE angle of Wiberg in the postoperative period, as well as in the acetabular index. These differences were statistically significant for both the right and left sides.

**Conclusion:** The radiographic evaluation of patients submitted to Ganz periacetabular osteotomy presented some statistically significant results; however, a larger sample is still necessary.

© 2017 Sociedade Brasileira de Ortopedia e Traumatologia. Published by Elsevier Editora Ltda. This is an open access article under the CC BY-NC-ND license (<http://creativecommons.org/licenses/by-nc-nd/4.0/>).

## Osteotomia periacetabular do quadril para tratamento da displasia residual: resultados preliminares

## RESUMO

**Objetivo:** Avaliar se a mudança do ângulo CE de Wiberg e do índice acetabular após a osteotomia periacetabular de Ganz é estatisticamente significativa.

**Métodos:** Foram avaliados os ângulos CE de Wiberg e índice acetabular pré- e pós-operatórios de 14 quadris operados em um hospital terciário de Curitiba, Paraná.

**Resultados:** As medidas do pós-operatório apresentaram diferenças significativas em relação ao pré-operatório. Observou-se um aumento significativo no ângulo CE de Wiberg no

## Palavras-chave:

Osteotomia

Acetábulo

Luxação do quadril

Fenômenos biomecânicos

<sup>☆</sup> Study conducted at Hospital Universitário Cajuru, Serviço de Quadril, Curitiba, PR, Brazil.

\* Corresponding author.

E-mail: [viniciusbr.medicina@yahoo.com.br](mailto:viniciusbr.medicina@yahoo.com.br) (V.B. Rodrigues).

<https://doi.org/10.1016/j.rboe.2018.03.012>

2255-4971/© 2017 Sociedade Brasileira de Ortopedia e Traumatologia. Published by Elsevier Editora Ltda. This is an open access article under the CC BY-NC-ND license (<http://creativecommons.org/licenses/by-nc-nd/4.0/>).

pós-operatório e uma redução significativa no índice acetabular. Essas diferenças foram estatisticamente significativas tanto para o lado direito como para o lado esquerdo.

**Conclusão:** A avaliação radiográfica dos pacientes submetidos à osteotomia periacetabular de Ganz apresentou alguns resultados estatisticamente significativos, porém ainda há necessidade de uma amostra maior.

© 2017 Sociedade Brasileira de Ortopedia e Traumatologia. Publicado por Elsevier Editora Ltda. Este é um artigo Open Access sob uma licença CC BY-NC-ND (<http://creativecommons.org/licenses/by-nc-nd/4.0/>).

## Introduction

The aim of the Bernese-Ganz<sup>1</sup> periacetabular osteotomy is to change the pathological biomechanics of the hip that lead to intra-articular damage and consequent arthrosis of this joint.<sup>1</sup> The reorientation of the dysplastic acetabulum increases the load surface, while maintaining or improving joint stability.<sup>2</sup>

Ganz periacetabular osteotomy has a number of advantages over other pelvic osteotomy techniques; namely, the maintenance of the posterior column, which remains intact and allows a greater intrinsic stability and early rehabilitation. Before this technique was developed, osteotomies violated the posterior column; a hip spica cast or pelvic fixation was necessary for an extensive period of time, which increased the risk of pseudoarthrosis at the osteotomy site. Moreover, as it is a close-to-joint osteotomy, the dimensions of the true pelvis do not change. Therefore, these patients are allowed to perform vaginal delivery,<sup>3</sup> which is not the case for patients who undergo other types of osteotomies. The proximity of this osteotomy to the joint also promotes an improvement of the lever arm of the abductor musculature, through hip medialization, which reduces the forces resulting in that location.<sup>4</sup>

From the anatomical standpoint, the bone cuts are made based on the knowledge of the vascular supply of the fragment. The pelvis is approached through a direct anterior or the modified Smith-Petersen access; care is taken to preserve the abductor muscles.<sup>5</sup> The literature on acetabulum irrigation is not extensive, particularly on its relation to periacetabular surgical techniques.<sup>6</sup> The blood supply of the endosteal fragment is interrupted at the osteotomy, but its perfusion is maintained by two branches of the superior gluteal artery, the acetabular artery, a branch of the inferior gluteal artery, and the acetabular branch of the obturator artery.<sup>5</sup> An additional contribution of capsular blood supply is also observed, unless the osteotomy is too close to that supply.<sup>7</sup>

In the Ganz osteotomy, the osteotomized acetabular fragment is much larger when compared to other techniques, which decreases the risk of joint cuts and fragment necrosis and, if necessary, allows an internal detachment of the joint rotation center and an adequate inspection of the joint for labral lesion correction.<sup>8</sup>

From its initial description, the surgical technique has undergone several modifications. In the anterior approach, as part of the original technique for the anterior aspect of the pelvis,<sup>1</sup> the abductors were removed from the iliac wing so that the supra-acetabular osteotomy could be performed. This procedure has greatly evolved, and the abductors are now mostly left intact.<sup>9-11</sup> In addition to preserving abductor

function, their protection preserves the obturator, superior and inferior gluteal arteries, and the capsular contributions to acetabular perfusion, reducing the risk of acetabular osteonecrosis.<sup>6-8</sup> Initially, the bone cuts were made from both sides of the iliac wing; however, in order to preserve the abductors, these cuts were altered and are made generally from the inner side of the pelvis.<sup>1,9-11</sup> It has recently become apparent that hip flexion strength is decreased within two years after surgery.<sup>12</sup> Some authors advocate that an access sparing the rectus femoris would improve hip flexion strength and may be a strategy to be adopted.

An important finding was that the femoroacetabular impact (FAI) could be responsible for continued pain after periacetabular osteotomy.<sup>13</sup> In a dysplastic hip, the femoral head has an elliptical shape with a decreased head-neck ratio<sup>14</sup> and a lateral flattening from the minimal gluteal hypertrophy.<sup>15</sup> When the acetabulum is reoriented so that there is excessive lateral or anterior coverage, FAI may occur, resulting in the incorporation of an arthrotomy in the surgical technique for collision assessment.<sup>15</sup>

The Bernese-Ganz periacetabular osteotomy aims in increasing the survival of the dysplastic hip, avoiding early hip replacement. This osteotomy brings the possibility of joint survival for at least 20 years. The factors of poor prognosis for osteotomy are: female gender, advanced age (over 40 years), anterior impact, severity of hip subluxation (Wiberg < 0°), and osteoarthrosis (Tönnis > 2).

## Material and methods

Twelve patients (14 hips) underwent the procedure. The mean age of patients at surgery was 27.8 years; the oldest was 38 years old. Surgeries were performed from September 2011 to June 2015.

In this surgical technique, patients were placed in dorsal recumbent position, under spinal anesthesia and with a cushion under the ipsilateral buttock of the hip to be operated. Ganz periacetabular osteotomy was performed with the ilioinguinal access using only the first access window. The reference points were, laterally, the iliac crest; and medially, the iliopsoas muscle. Moreover, in the immediate postoperative period, an epidural catheter was used for patient analgesia.

For this study, the radiographs of patients operated in a tertiary hospital in Curitiba, Paraná, Brazil, were evaluated. Through the computer program Surgimap, Version 2.1.8, the center-edge angles (or Wiberg CE angle), and the pre

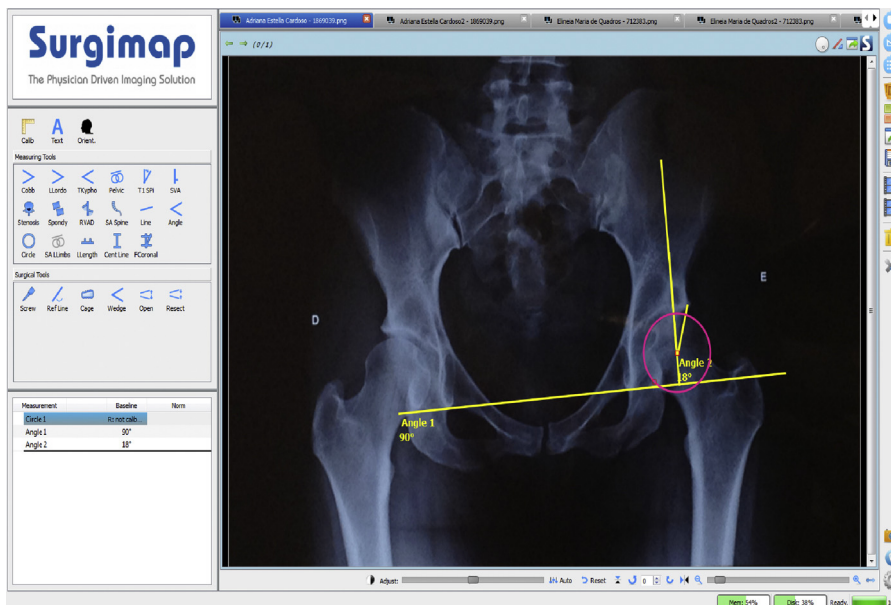


Fig. 1 – CE angle of Wiberg on Surgimap.

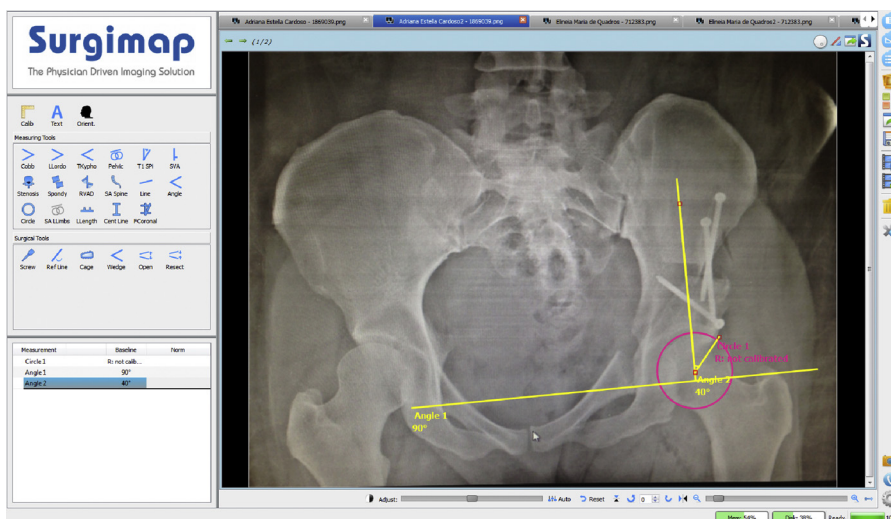


Fig. 2 – Postoperative CE angle of Wiberg on Surgimap.

and postoperative acetabular index of these patients were evaluated (Figs. 1 and 2).

Descriptive statistical measures were calculated to summarize and analyze the data set: means, medians, standard deviations, and maximum and minimum values. Graphs of means with their respective standard errors were also drawn.

To compare the sides of the operations, the non-parametric Mann-Whitney test was used; the Wilcoxon test was applied to compare the pre and postoperative moments. The use of these tests is justified by the lack of normality of the data, checked by the Shapiro-Wilk normality test.

In order to apply a classic test, which requires the assumption of normal data, it would be advisable to increase the sample size to 30 cases. However, with 12 cases, it is possible to apply alternative statistical techniques, which provide satisfactory results.

Excel and Statistica software (version 7) were used for the statistical analyzes, and the significance level was set at 5%.

## Results

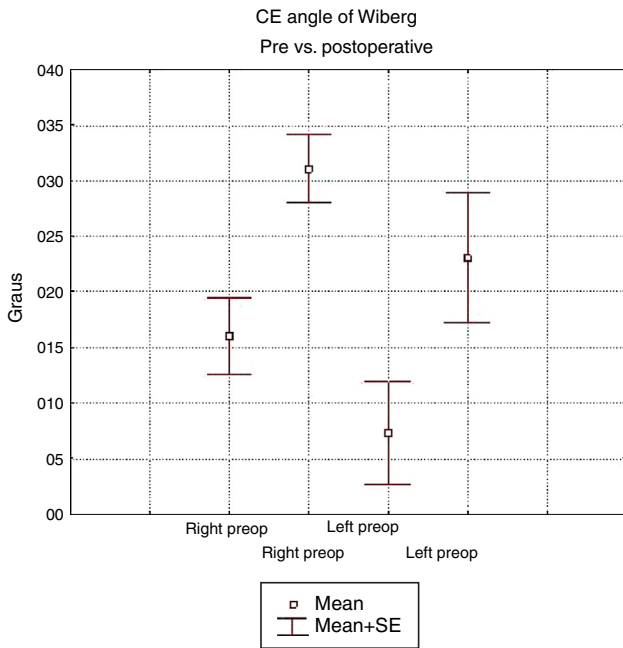
As shown in Table 1, osteotomies were more commonly performed on the right side than on the left. A negative CE angle of Wiberg was observed on the left side.

An increase was observed in the CE angle of Wiberg in the postoperative period (Fig. 3), when compared with the preoperative period on both the right and left sides.

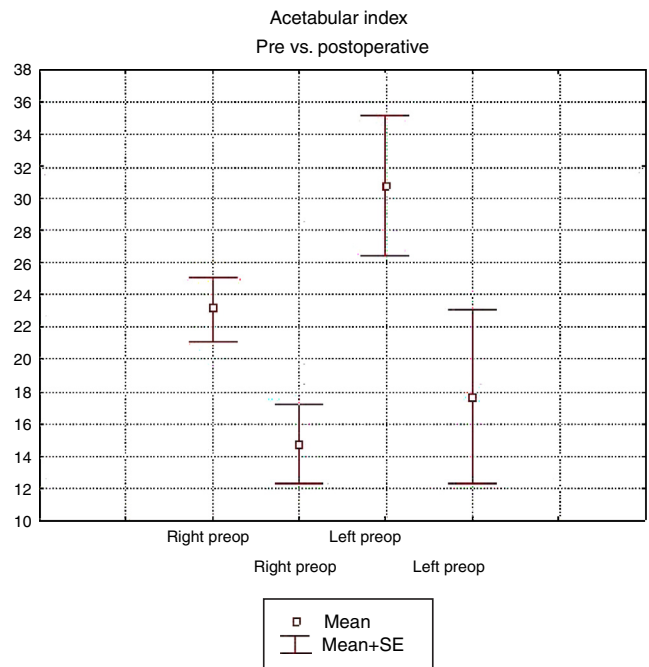
Regarding the acetabular index, a reduction in the values was observed in the postoperative period when compared with the preoperative period on both the right and left sides (Fig. 4 and Table 2).

**Table 1 – Descriptive measures.**

Operative	Side	Measurements	Mean	n	Minimum	Maximum	Median	SD
Pre	Right	CE angle of Wiberg	16.0	8	7	37	14.5	9.89
		Acetabular index	23.1	8	16	34	23	5.67
	Left	CE angle of Wiberg	7.3	6	-11	18	12	11.38
		Acetabular index	30.8	6	14	43	32	10.65
Post	Right	CE angle of Wiberg	31.0	8	17	48	31.5	8.68
		Acetabular index	14.8	8	4	22	14.5	7.03
	Left	CE angle of Wiberg	23.0	6	3	38	28.5	14.25
		Acetabular index	17.7	6	5	40	14.5	13.22



**Fig. 3 – CE angle of Wiberg.**



**Fig. 4 – Acetabular index.**

Table 2 demonstrates that the postoperative measurements were significantly different than those in the preoperative period. A significant postoperative increase was observed in the CE angle of Wiberg, and a significant postoperative reduction was observed in the acetabular index. These differences were statistically significant on both the right and left sides.

Comparing surgeries performed on the right side with those performed on the left side (Table 3), a significant difference was observed only between the acetabular index measurements in the pre and postoperative periods. The measurements obtained before surgery on the left side were significantly higher. However, if a significance level of 1% had been considered, this difference would not have been significant.

**Discussion**

Over 70% of hip arthroses identified on radiographs are related to malformations.<sup>16</sup> Of the hip malformations, residual dysplasia is directly related to osteoarthritis. A direct relationship has been observed between the radiographic grade of dysplasia and the age at the diagnosis of osteoarthritis.<sup>17</sup>

**Table 2 – Pre vs. postoperative comparisons.**

Measurements	Side	n	T	p
CE angle of Wiberg	Right	8	0.00	0.005
	Left	6	0.00	0.25
Acetabular index	Right	8	0.00	0.005
	Left	6	0.00	0.25

**Table 3 – Right vs. left comparisons.**

Operative		Sum			n		p
		R	L	U	R	L	
Pre	CE angle of Wiberg	79.0	26.0	11.0	9	5	0.147
	Acetabular index	51.0	54.0	6.0	9	5	0.029
Post	CE angle of Wiberg	76.0	29.0	14.0	9	5	0.298
	Acetabular index	60.5	44.5	15.5	9	5	0.364

Furthermore, numerous studies have confirmed the relationship between dysplasia and the presence of symptomatic and radiographic osteoarthritis.

Ganz osteotomy is widely recognized as the most anatomical of the periacetabular redirection osteotomies; nonetheless, it is the most complex procedure, with a steeper learning



curve.<sup>18-20</sup> In an analysis of 508 Ganz osteotomies published in 1999, it was observed that 85% of the technical complications were observed in the first 50 procedures.<sup>11</sup>

As these procedures were performed by the same surgeon in a single medical institution, there is no learning curves bias or difference between institutions, which allows for a proper assessment of the results obtained and the correlation of results with the preoperative radiographic findings.

Despite the low number of cases evaluated, in each case of the present study, a good postoperative result was observed regarding acetabular coverage, bringing the values to the normal range.

Among the assessed cases, one presented good preoperative acetabular coverage; this patient underwent osteotomy to treat acetabular retroversion as a cause of joint pain and loss of mobility (flexion). In that surgical procedure, retroversion correction, femoral neck osteochondroplasty, pincer-type impingement resection, and labrum reinsertion were performed.

As the present study was aimed at evaluating the radiographic results, the functional results were not discussed here; however, it is worth noting that even in cases where there was contraindication for the osteotomy due to a very low CE angle of Wiberg, the patients evolved well, presenting normal range of motion, and walked without pain. These results are attributed to the restoration of Shenton's line and, consequently, the biomechanics of the joint after surgery.

## Conclusion

Radiographic evaluation of the patients who underwent Ganz periacetabular osteotomy presented some statistically significant results; however, a larger sample is still required.

## Conflicts of interest

The authors declare no conflicts of interest.

## REFERENCES

- Ganz R, Klaue K, Vinh TS, Mast JW. A new periacetabular osteotomy for the treatment of hip dysplasias. Technique and preliminary results. *Clin Orthop Relat Res.* 1988;(232):26-36.
- Mechlenburg I, Nyengaard JR, Rømer L, Søballe K. Changes in load-bearing area after Ganz periacetabular osteotomy evaluated by multislice CT scanning and stereology. *Acta Orthop Scand.* 2004;75(2):147-53.
- Loder RT, Karol LA, Johnson S. Influence of pelvic osteotomy on birth canal size. *Arch Orthop Trauma Surg.* 1993;112(5):210-4.
- Haddad FS, Garbuz DS, Duncan CP, Janzen DL, Munk PLCT. Evaluation of periacetabular osteotomies. *J Bone Joint Surg Br.* 2000;82(4):526-31.
- Beck M, Leunig M, Ellis T, Sledge JB, Ganz R. The acetabular blood supply: implications for periacetabular osteotomies. *Surg Radiol Anat.* 2003;25(5-6):361-7.
- Nötzli HP, Siebenrock KA, Hempfing A, Ramseier LE, Ganz R. Perfusion of the femoral head during surgical dislocation of the hip monitoring by laser Doppler flowmetry. *J Bone Joint Surg Br.* 2002;84(2):300-4.
- Kalhor M, Beck M, Huff TW, Ganz R. Capsular and pericapsular contributions to acetabular and femoral head perfusion. *J Bone Joint Surg Am.* 2009;91(2):409-18.
- Trousdale RT, Ekkernkamp A, Ganz R, Wallrichs SL. Periacetabular and intertrochanteric osteotomy for the treatment of osteoarthritis in dysplastic hips. *J Bone Joint Surg Am.* 1995;77(1):73-85.
- Leunig M, Ganz R. The Bernese method of periacetabular osteotomy. *Orthopade.* 1998;27(11):743-50.
- Leunig M, Siebenrock KA, Ganz R. Rationale of periacetabular osteotomy and background work. *Instr Course Lect.* 2001;50:229-38.
- Hussell JG, Rodriguez JA, Ganz R. Technical complications of the Bernese periacetabular osteotomy. *Clin Orthop Relat Res.* 1999;(363):81-92.
- Sucato DJ, Tulchin K, Shrader MW, DeLaRocha A, Gist T, Sheu G. Gait, hip strength and functional outcomes after a Ganz periacetabular osteotomy for adolescent hip dysplasia. *J Pediatr Orthop.* 2010;30(4):344-50.
- Myers SR, Eijer H, Ganz R. Anterior femoroacetabular impingement after periacetabular osteotomy. *Clin Orthop Relat Res.* 1999;(363):93-9.
- Steppacher SD, Tannast M, Werlen S, Siebenrock KA. Femoral morphology differs between deficient and excessive acetabular coverage. *Clin Orthop Relat Res.* 2008;466(4):782-90.
- Beck M, Woo A, Leunig M, Ganz R. Gluteus minimus-induced femoral head deformation in dysplasia of the hip. *Acta Orthop Scand.* 2001;72(1):13-7.
- Gosvig KK, Jacobsen S, Sonne-Holm S, Palm H, Troelsen A. Prevalence of malformations of the hip joint and their relationship to sex, groin pain, and risk of osteoarthritis: a population-based survey. *J Bone Joint Surg Am.* 2010;92(5):9-1162, <http://dx.doi.org/10.2106/JBJS.H.01674>.
- Cooperman DR, Wallensten R, Stulberg SD. Acetabular dysplasia in the adult. *Clin Orthop Relat Res.* 1983;(175):79-85.
- Gillingham BL, Sanchez AA, Wenger DR. Pelvic osteotomies for the treatment of hip dysplasia in children and young adults. *J Am Acad Orthop Surg.* 1999;7(5):325-37.
- Crockarell J Jr, Trousdale RT, Cabanela ME, Berry DJ. Early experience and results with the periacetabular osteotomy. The Mayo Clinic experience. *Clin Orthop Relat Res.* 1999;(363):45-53.
- Davey JP, Santore RF. Complications of periacetabular osteotomy. *Clin Orthop Relat Res.* 1999;(363):33-7.